The Shalakya Tantra

Diseases of Eye, Head & E.N.T.

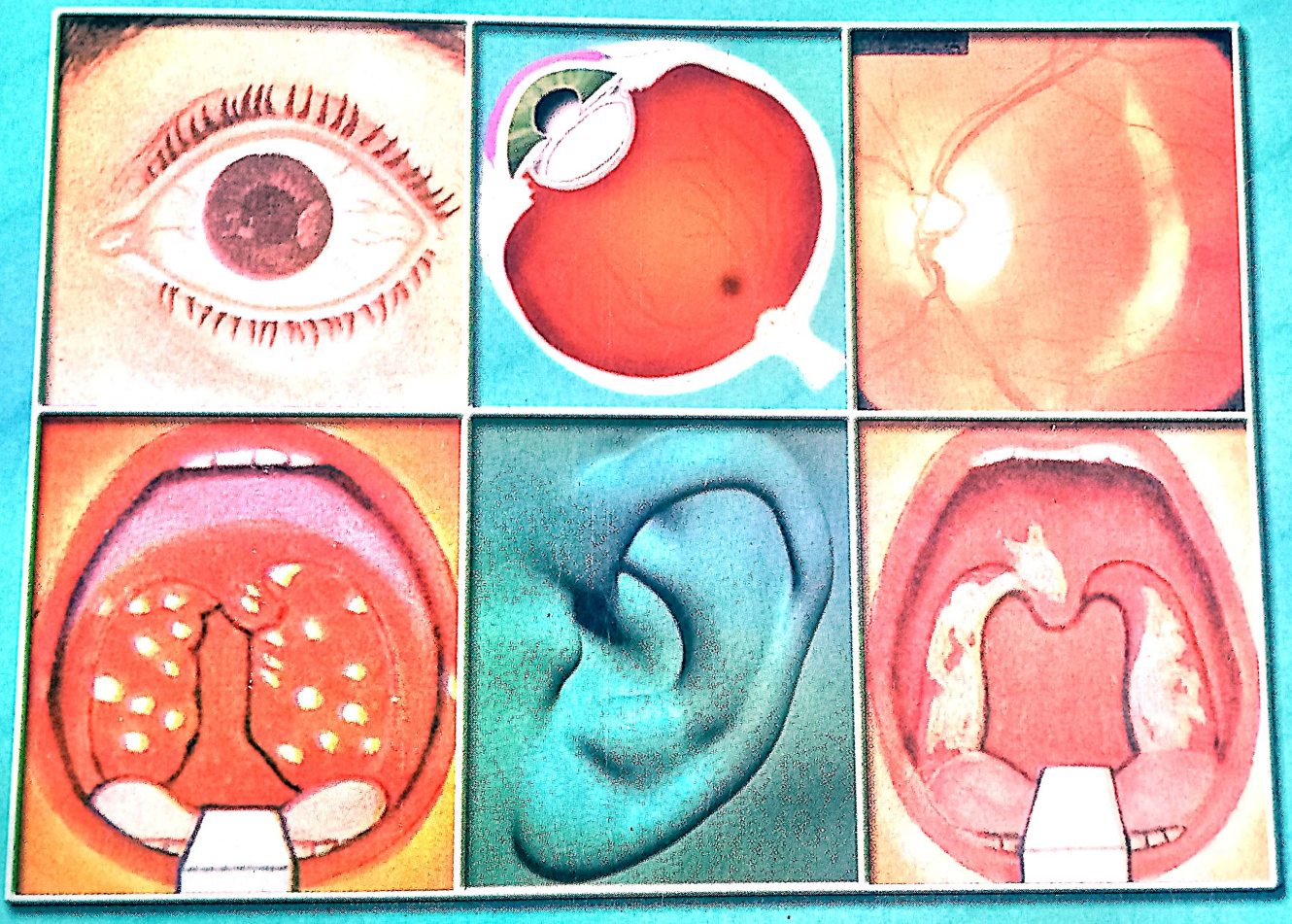

Dr. Dingari Lakshmana Chary

Ayurveda Ek Vikalp Foundation

- All ayurvedic books store
- India's biggest Ayurveda union.
- For Ayurvedic E- book follow, subscribe us on

Telegram-
https://t.me/ayurvedaekvikalpfoundation

Facebook-
https://m.facebook.com/ayurvedaekvikalp/?ref=bookmarks

E-mail- ayurvedaekvikalp@gmail.com

Website- ayurvedaekvikalp.org

For WhatsApp group msg-
9561788826

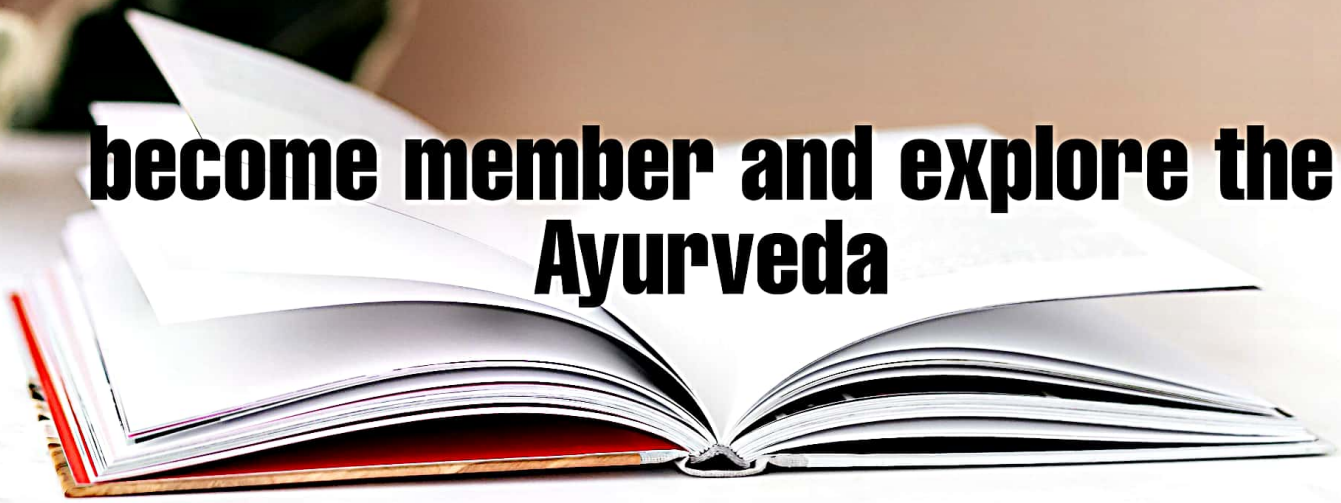

become member and explore the Ayurveda

THE SHALAKYA TANTRA

Publishers :
CHAUKHAMBA SANSKRIT PRATISHTHAN
[illegible], Ansari Road, Darya Ganj, New Delhi 110002
Phone : (011) 41530902, 42637180
WhatsApp : 9013900450, 8800844221
E-mail : [illegible]
Website : www.chaukhambabooks.in

© All Rights Reserved
ISBN : 978-81-7084-175-3
Reprint : 2019
Pages : II+VIII+398 (Part I) } Bound in one
10+410 (Part II) } with Coloured Plates
Price : ₹ 625.00

Also can be had from :
CHOWKHAMBA VIDYABHAWAN
Chowk (Behind The Bank of Baroda Building)
Varanasi 221001

•

CHAUKHAMBA SURBHARATI PRAKASHAN
K. 37/117 Gopal Mandir Lane
Varanasi 221001

•

CHAUKHAMBA PUBLISHING HOUSE
4697/2, Ground Floor, Street No. 21-A
Ansari Road, Darya Ganj
New Delhi 110002

All rights reserved. No part of this publication may be reproduced or transmitted in any form or by any means, electronic or mechanical, including photocopying, recording or any information storage or retrieval system, without prior permission in writing from the Publishers.

Printed by :
A. K. Lithographers, Delhi

Blessings from
H.H. Sh. Shivakumar Swamiji
The Chairman
C.S.S. N.K.J. Ayurvedic Medical College, Bidar

Best Wishes from
Prof. V.S. Patil
Principal
C.S.S. N.K.J. Ayurvedic Medical College, Bidar.

Late Shri Dingari Venkata Charyulu
Late Smt. Dingari Venkata Ramanamma

The Author
Dr. Dingari Lakshmana Chary
B.A.M.S.; M.D.; (Ph.D)
Date of Birth : 26-01-1962
B.A.M.S. 1979-1985 (Kakatiya University
M.D. 1986 TO 1989 (Osmania University
Ph.D - from 1998 (Pune University)
Working as HOD of Shalya Shalakya Department,
N.K.J. Ayurvedic Medical College, Bidar.

FORE WORD

The Shalakya Tantra is an important Branch of Ayurveda dealing with the diseases of E.N.T. and eye, written by Dr. D. Lakshmana Chary. B.A. M.S; M.D; (Ph.D) Shalakya, in English language is based on the syllabus contents of B.A.M.S. degree course. This book is helpful not only to the students of Ayurveda but also to the teachers of Shalakya Tantra.

The work of Dr. Chary is really appreciable. He has taken great pains to compile and collect the various scholarly commentaries and tried to compare and contrass them to elucidate the real interpretation for better understanding of the subject. His work is the need of the hour, particularly for the students of south where the books in English Language are very few. This work fullfils the long felt need of the students.

I welcome this publication on "Shalakyatantra" subject and congratulate the young author for this onerous task which he completed energitically and patiently. I wish him all success and hope that he will continue to write many more books on various subjects in future with this experience, I feel honoured to write this foreword for the book brought out by Dr. Chary who was my student. I wish him success in all his future endeavour.

With love and blessings

Prof. Dr. V.S. PATIL
G.C. I.M; M.D (B.H.U)
Principal,
N.K.J. Ayurvedic Medical College,
Bidar, Karnataka.

PREFACE

It is my great privilege and pleasure to undertake the work of writing the book "Shaalakya Tantra" in two volumes. It is by the grace of God Dhanvanthari alone that my book has been uninterruptedly completed.

Since there has been no book of its kind in English furnishing the fullest information about Shalakyatantra, I have made a bold attempt to venture on it keeping in view the C.C.I.M. syllabus of final B.A.M.S. Students. The success of my work fully depends upon its utility to many a student.

I express my sincere gratitude to H.H. Sri Sri Sri Shivakumar Swamiji, the presedent, C.S.S;N.K.J. Ayurvedic Medical College, Bidar, for providing me the best opportunity to serve in his esteemed Medical Institution. It is he who has been the source of my inspiration to bring out this book.

I offer my heartfelt thanks to the Principal, Dr. V.S. Patil for giving me the most Valuable suggestions from time to time. It is kind of him to write the foreword to my book.

I owe a great deal to Dr. V.V. Doiphode, the principal Tilak Ayurvedic Mahavidyalaya, Pune and the Dean of faculty of Ayurveda Pune University Pune, for extending his utmost co-operation for my Ph.D. work and I am profusely thankful to the Director P.G. Section Dr. Purchure and the Joint Director Dr. D.P. Puranic for rendering their invaluable help to me.

I whole heartedly thank here Dr. S.M. Sathye who is giving me the very good guidance for my Ph.D. work.

I also wish to record my unfailing thankfulness to the Professors, the Readers, the Lecturers of N.K.J. Ayurvedic Medical College, Bidar and Tilak Ayurveda Mahavidyalaya Rastapet, Pune for their best encouragement in my endeavour.

I. Sincerely acknowledge and place on record the direct and Indirect help and guidance of the authors of modern text books on ophthalmology and E.N.T. whose views presentations and illustrations are very much helpful to me in bringing out the book.

Last but not the least I thank Printers of the book and all others who helped me in completing the book as desired

Yours Sincerely

Dr. D. LAKSHMANA CHARY
M.D. (Ph.D) Shalakya
H.O.D. of Shalya Shalakya Dept.
N.K.J. Ayurvedic Medical College,
Bidar, Karnataka.

Contents

	Topic	Page No.
I.	**INTRODUCTION TO AYURVEDA**	**2**
II.	**ANCIENT LITERARY REFERENCES OF SHALAKYA TANTRA**	**8**
III.	**DESCRIPTION OF SHALAKA - SHALAKYA TANTRA WITH REFERENCE SHLOKA IN HINDI**	**9**
IV.	**AVAILABILITY OF SHALAKYA LITERATURE IN SAMHITAS**	**10**
V.	**SHALAKYA TANTRA ACHARYA RISHIES**	**10**
VI.	**NETRA SHAREERA WITH REFERENCE SHLOKA IN HINDHI**	
	1) Synonyms of Netra	15
	2) Netra Uthpatthi	15
	3) Netra Pramanam	16
	4) Netra Pancha bhauthikatha	17
	5) Netra Bhaga	18
	6) Netra Mandala	19
	7) Netra Sandhi	19
	8) Netra Patala	19
	9) Netra Guha (Orbit)	21
	10) Contents of orbit according to Ayurveda	22
	11) Anatomy of the Orbit	22
	12) Contents of orbit	24
	13) Anatomy of eye lids	26
	14) Lacrimal apparatus	29
	15) Conjunctiva	30
	16) Anatomy of eye ball	32
	17) Cavity of Eye ball	39
	18) Anterior Chamber	40
	19) Aqueous circulation	40
	20) Lens	41
VII.	**NETRA ROGA SAMANYA NIDANA WITH REFERENCE SHLOKA IN HINDI**	**42**
VIII.	**NETRA ROGA SAMANYA POORVA RUPAM**	**47**
IX.	**NETRA ROGA SAMPRAPTHI**	**47**
X.	**CLASSIFICATIONS OF EYE DISEASES**	**48**
	1) Classification of eye diseases according to dosha	49
	2) Classification of eye diseases according to Shareera	51
	3) Classification of eye diseases according to sadya-Asadya	52
	4) Classification of eye diseases according to the treatment principle.	52
XI.	**DISEASES OF NETRA SANDHI WITH REFERENCE SHLOKAS IN HINDI**	
	1) Types of Sandhigatha roga	54
	2) Puyalasa	54
	3) Upanaha	55
	4) Netrasrava	58
	5) Parvani	58
	6) Alaji	59
	7) Comparative study of Parvani and Alaji	59
	8) Phlyctenular Conjunctivitis	59

9) Krimigranthi 60
10) Epiphora 60
11) Lactimation 60
12) Dacryocystitis 61
13) Blepharitis 63

XII DISEASES OF VARTHMA MANDALA WITH REFERENCE SHLOKA IN HINDI

1) Types of Varthma roga 73
2) Utsangini 73
3) Lagana 75
4) Bahala Varthma 76
5) Chalazian 76
6) Kumbheeka 77
7) Anjana namika 78
8) External hordeolum - stye 78
9) Pothaki 79
10) Trachoma 80
11) Varthma Sharkara 81
12) Arshovarthma 81
13) Shuskarsha 82
14) Varthmabandha or Varthmava bandha 82
15) Klista Varthma 82
16) Varthma Kardama 82
17) Shyava Varthma 83
18) Praklinna Varthma 83
19) Aklinna Varthma 83
20) Ankyloblepharon 83
21) Symblepharon 84
22) Blepharophimosis 84
23) Vatahatha arbuda 84
24) Lagophthalmos 84
25) Ptosis 85
26) Varthma arbuda 86
27) Nimesha 86
28) Blinking of eyelids 86
29) Tumours of eye lids 87
30) Shonithaarsha 88
31) Bisavarthma 88
32) Pakshma Kopa 88
33) Entropion 91
34) Ectropion 91
35) Trichiasis 92
36) Kruchronmeelan 92
37) Alaji 93
38) Pakshma Shaatha 93
39) Uthklista 93
40) Pittoth Klista 93
41) Kapthothklista 94

42) Kukunaka 94
43) Shista Varthma 95
44) Kunchana 95
45) Congenital abnormalities of eyelids 95

XIII. DISEASES OF SHUKLA MANDAL WITH REFERENCE SHLOKA IN HINDI

1) Types of Shukla gatha roga 105
2) Arma 106
3) Pterigium 110
4) Shukthika 111
5) Xerophthalmia 111
6) Arjuna 112
7) Pistaka 113
8) Sirajala 113
9) Sira Pidika 113
10) Balasa graditha 114
11) Episcleritis 114
12) Scleritis 114
13) Pinguecula 115
116

XIV. DISEASES OF KRISHNAMANDAL WITH REFERENCE SHOKA IN HINDI

1) Types of Krishnagatha roga 122
2) Savrana Shukla 122
3) Sira Shukla 123
4) Avrana Shukla 124
5) Ajakajatha 124
6) Akshi Pakatyaya 125
7) Shukra Vyadhi Chikista 126
8) Ulcerative Keratitis classifications 129
9) Aetiology-Pathology of Ulcerative Keratitis 132
10) Dendritic corneal ulcer 134
11) Lagophthalmic corneal ulcer 134
12) Neurotrophic corneal ulcer 134
13) Phlyctenular Keratitis 134
14) Hypopyon corneal ulcer 135
15) Mycotic corneal ulcer 135
16) Marginal corneal ulcer 135
17) Atheromatus corneal ulcer 135
18) Moorens corneal ulcer 136
19) Superficial Keratitis 136
20) Deep Keratitis 137
21) Other affections of cornea 138
22) Corneal Opacities 139

XV. SARVAGATHA ROGA WITH REFERENCE SHLOKA IN HINDI

1) Types of sarvagatha roga 149
2) Abhishyanda 149
3) Vataj Abhishyanda 149
4) Pittaj Abhishyanda 150
5) Kaphaj Abhishyanda 150

6) Raktaj Abhishyanda 151
7) Treatment Principles of Vataj Abhishyanda 151
8) Treatment Principles of Pittaja Abhishyanda 153
9) Treatment Principles of Kaphaj Abhishyanda 154
10) Treatment Principles of Raktaj Abhishyanda 155
11) Conjunctivitis types, Description 156
12) Adhimantha Aetiology-clinical features 167
13) Vatika Adhimantha 168
14) Pittaja Adhimantha 168
15) Kaphaj Adhimantha 169
16) Raktaj Adhimantha 169
17) Glaucoma 170
18) Sashopha akshipaka 174
19) Ashopha akshi paka 175
20) Hathadhimantha 176
21) Anila Paryaya 176
22) Anyathovatha 177
23) Shuskaakshipaka 177
24) Amladyushitha 178
25) Sirothpaatha 178
26) Siraharsha 178

XVI DISEASES OF DRUSTIMANDAL WITH REFERENCE SLOKA IN HINDI

1) Types of Drustigatha roga 190
2) Description of Timira Kacha Linganash 191
3) Symptoms of Timira based on patalas by Vagbhata 192
4) Symptoms of Timira based on patalas by sushrutha 194
5) Symptoms of Timira Kacha Linganash based on dosha by Sushrutha. 196
6) Symptoms of Timira Kacha Linganash based on dosa by vagbhata. 197
7) Treatment Principles of Timira Kacha Linganasha 198
8) Vataja Timira Chikitsa 205
9) Pittaja Timira Chikitsa 207
10) Kaphaja Timira Chikitsa 208
11) Sanni Pathaja Timira Chikitsa 209
12) Parimlayi and Raktaj Timira Chikitsa 209
13) Kaphaj Linganasha Shastra Chikitsa 210
14) Pitta Vidagdha drusti 213
15) Kapha Vidagdha drusti 213
16) Dhooma darshi 217
17) Ushna Vidagdha drusti 217
18) Amla Vidagdha drusti 217
19) Hraswajadya 217
20) Nakulandhya 217
21) Nakthandhya 218
22) Aupasargika Linganash 218
23) Bahya Linga nash 218
24) Abhighataj Linganash 219
25) Nayanaabhighatha 219

26) Cataract 222
27) Classification of cataract 225
28) Senile Cataract 225
29) Congenital or developmental cataract 228
30) Traumatic cataract 228
31) Osmotic cataract 229
32) Cataract due to systemic disorders 229
33) Complicated cataract 229
34) Toxic cataract 229
35) metabolic cataract 230
36) Syndermatotic cataract 230
37) Cataract with multiple syndromes 231
38) Cataract surgery 231
39) Terminology of uveal tract lesions 235
40) Congenital abnormalities of Uveal treact 236
41) Iritis 237
42) Cyclitis 239
43) Choroiditis 240
44) The pupils 243
45) Retina 245
46) Injuries of retina 245
47) Retinitis 246
48) Retinopathies 247
49) Neo Plasms of Retina 249
50) Vascular disorders of retina 250
51) Retinal changes in blood disorders 251
52) Degenerative conditions of Retina 252
53) Detachment of Retina 253
54) Diseases of optic nerve 253
55) Papillitis 254
56) Papilloedema 254
57) Retrobulbar optic neuritis 255
58) Optic atrophy 255
59) Tumours of optic nerve 255
60) Aqueous affections 256
61) Vitreous lesions 256
62) Errors of refraction 266
63) Myopia 267
64) Hypermetropia 270
65) Astigmatism 271
66) Presbyopia 272
67) Accommodation of Lens 273
68) Dayblindness (Hemaralopia) 275
69) Colour blindness 276
70) Night blindness (Nyctalopia) 276
71) Amaurosis 277
72) Amblyopia 277
73) Hemianopia 277
74) Diplopia 278
75) Phthisisbulbi 278
76) Internal Ophthalmo plegia 279

77) External Opththalmo plegia 279
78) Colour haloes 279
79) Dim Vision 279
80) Blindness profile and its controle 280
81) Ku Poshana Janya Netra Vikara 281
82) Eyediseases in common infections 284
83) Injuries to the eye lids and eyeball 288
84) Mechanical Injuries 288
85) Chemical Injuries 291
86) Thermal Injuries 293
87) Electrical Injuries 293
88) Radiational Injuries 293
89) Burns of eye lids 294
90) Burns of conjunctiva and cornea 294
91) Paralysis of Extrinsic ocular muscles 295
92) Binocular vision 297
93) Diplopia 297
94) Types of Ocular Deviation 298
95) Varieties of Ocular Palsies 300
96) Concomitant squint (Non Paralytic)J 301
97) Nystagmus 303
98) Diseases of the Orbit 304
99) Periostitis 304
100) Orbital Cellulitis 304
101) Tenonitis 305
102) Tumours of orbit 305
103) Uni ocular proptosis 305
XVII 1) Lekhana sadya roga 307
2) Bhedhana Sadya roga 309
3) Chedana sadya roga 310
XVIIINETRA KRIYA KALPA 314
1) Seka 315
2) Aashchyotan 316
3) Pindi 317
4) Bidalaka 317
5) Anjana 321
6) Akshi Tarpana 323
7) Putapaka 325
XIX 1) Anjana yoga from sushrutha utthara sthana 335
2) Anjana yoga from Astanga Hrudaya 341
3) Anjana yoga from charaka samhitha 342
4) Anjana yoga from Rasa Ratna samucchaya 344
5) Anjana yoga from chakradatta 345
6) Anjana yoga from Basava rajeeya 349
7) Anjaya yoga from Netra darpan 350
8) Anjana yoga from Bhaishjya Retnavali 351
9) Anjana yoga from sarangadhar samhitha 354
XX EXAMINATION OF EYEBALL 383
XXI OPHTHALMIC INSTRUMENTS 389
XXII A MODEL CASE SHEET OF SHALAKYA

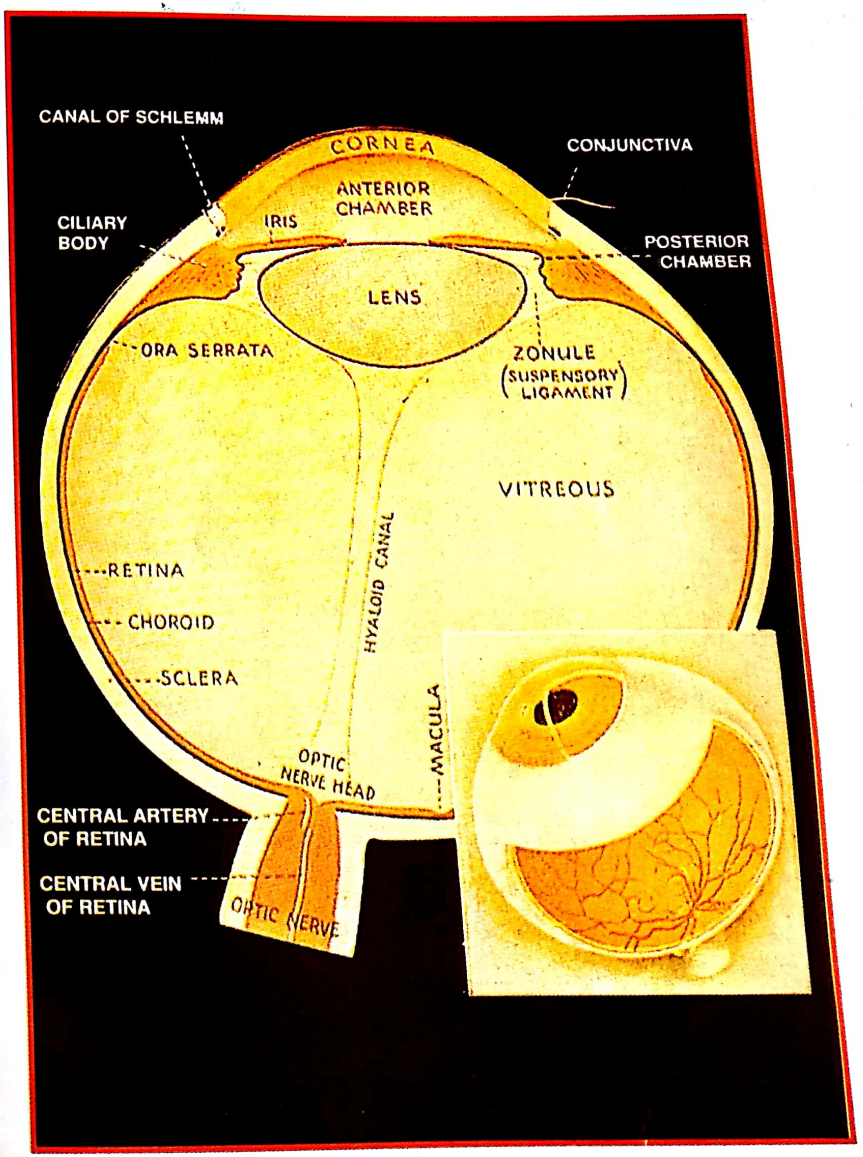



बाल आंजनेय स्वामि (शेषु) प्रसन्न

गणेश स्तुति

शुक्लाम्बरधरं विष्णुं शशिवर्णम चतुर्बुजम्
प्रसन्न वदनम ध्ययेतसर्व विघ्नोपशांतये

धन्वंतरि प्रार्थन

नमामि धन्वंतरि मादिदेवम
सुरा सुरैर्वन्दित पाद पद्मम
लोके जारा रुग्भय मृत्युनाशम
दातार मीशं विविधौशधीनाम

रागादि रोगा: सहजा: समूला
येनाशु सर्वे जगातोप्यपास्त:
तमेक वैद्यं शिरसा नमामि
वैद्याग मज्ञांश्चा पितामहादीन

Black

INTRODUCTION TO AYURVEDA

Ayurveda is the science of life, it is the God gifted very ancient and the first medical science which was memorised and composed by the originator Brahma (Swayambhoo) and considered it as the branch of Atharvana veda (Upaveda to atharvana veda and treated it as panchama veda). It is explained as 3 principled (3 sutra Hethu - Linga-Aushada) and 8 branched medical science (Astanga Ayurveda)

Ayurveda is the first and the Oldest medical science, existing since or before the human creation. It is aimed to1) Protect the health by giving the knowledge of preventive health principles,2) Protect or cure the diseases by explaining the differrent types of treatment-procedures and principles (Maintanence of health and correction of ill health Swasthasya swastha rakshanam-aaturasya vikara prashamanam)

The Eight branches of Ayurveda are

1)	Kaya Chikitsa	(General Medicine)
2)	Balaroga Chikitsa	(Paediatrics)
3)	Graha roga Chikitsa	(Demonology)
4)	Urdwanga roga Chikitsa	(E.N.T., Ophthalmology)
5)	Shalya Chikitsa	(Surgery)
6)	Visha Chikitsa	(Toxicology)
7)	Rasayana Chikitsa	(Rejuvenative therapy)
8)	Vajee karana Chikitsa	(Aphrodisiacs)

Among the Astangas, Urdwanga Chikitsa or shalakya chikitsa or uttamanga chikitsa or jathrurdwa roga chikitsa or E.N.T. and ophthalmology is explained as the best for existing in the shiras which is the Seat for all the vital organs (Prana, Indria, Marma etc.)

The shalakya tantra gives the detailed discription of the diseases of the following parts 1) Ear diseases 2) Nose diseases 3) Throat diseases (Lips - Teeth, Gums Tongue Palate Throat proper etc) 4) Eye diseases and 5) Shiro rogas. All these are sensory organs seated in the shiras so only this branch of the medicine is given prime importance among the 8 branches of Ayurveda Again in this branch ophthalmology (Netra roga vigyana) is having utmost importance because eye is the organ for visual sensation, if vision is lost merely every thing is lost - A blind man, though rich cannot enjoy the world, so only it is explained that " Sarvendrianam Nayanam Pradhanam".

आयुर्वेद निरुक्ति

हिताहितं सुखं दुःखं आयुः तस्य हिताहितम
मानंच तच्चा यत्रोक्तं आयुर्वेद स उच्यते

अष्टाङ्गायुर्वेद

काय बाल ग्रहोर्ध्वाङ्ग शल्य दंष्ट्राजरावृषान
अष्टावङ्गानि तस्याहुश्चिकित्सायेशु

उत्तमांग या शिरः

प्राणा : प्राणभृतां यत्र श्रिताः सर्वेन्द्रियाणि च।
यदुत्तमांगमंगानां शिरस्तदभिधीयते॥

चरक

सर्वेन्द्रियाणि येनास्मिन् प्राणा येन च संश्रिताः ।
तेन तस्योत्तमांगस्य रक्षायामादृतो भवेत् ॥

वाग्भट

शालाक्यतन्त्र की निरुक्ति

शलाकया यत्कर्म क्रियते तच्छालाक्यम्।
शालाकायाः कर्म शालाक्यम्, तत्प्रधानं तन्त्रमपि शालाक्यम् ॥

डल्हण

शालाक्यं नामोर्ध्वजत्रुगतानां श्रवण नयन वदन
घ्राणादिसंश्रितानां ध्याधीनामुपशमनार्थम

सु.सू.1

नेत्र-शारीर

विद्याद् द्वयङ्गुल-बाहुल्यं स्वांगुष्ठोदरसम्मितम् ।
द्वयङ्गुलं सर्वतः सार्ध भिषङ्नयन-बुद्बुदम् ॥
सुवृत्तं गोस्तनाकारं सर्वभूतगुणोद्भवम् ।

(सु. उ. 1-10)

नेत्र का पांचभौतिकत्व

पलं भूवोग्नितो रक्तं वातात् कृष्णं सितं जलात्।
आकाशादश्रुमार्गाश्च जायन्ते नेत्रबुद्बुदे॥

(सु. उ. 1-11)

कृष्णमण्डल-दृष्टि मण्डल प्रमाण

नेत्रायामत्रिभागन्तु कृष्ण मण्डलमुच्यते
कृष्णात् स्तममिच्छन्ति दृष्टि दृष्टि विशारदाः

(सु. उ. 1 - 12,13)

नेत्रभाग

मण्डलानि च सन्धींश्च पटलानि च लोचने ।
यथाक्रमं विजानीयात् पंचषट् च षडेव च ॥

(सु. उ. 1/14)

नेत्रमंडल

पक्ष्मवर्त्मश्वेतकृष्णदृष्टीनां मण्डलानि तु ।
अनुपूर्वंतु ते मध्याश्चत्वारोत्या यथोत्तरम् ॥

(सु. उ. 1-15)

नेत्रसन्धि

पक्ष्मवर्त्मगतः सन्धिर्वर्त्मशुक्लगातोपरः ।
शुक्लकृष्णगातस्त्वन्यः कृष्णदृष्टिगतोपरः ॥
तथा कनीनकगतः षष्टश्चापाङ्गः स्मृतः ।

(सु. उ. 1-16)

नेत्रशारीरःपटल

द्वे वर्त्मपटले विद्याच्चत्वार्यन्यानि चाक्षिणिक्ष
जायते तिमिरं येषु व्याधिः परमदारुणः॥

(सु. उ. 1/17)

तेजो जलाश्रितं बाह्यं तेष्वन्यत् पिशिताश्रितम्
मेदस्तृतीयं पटलमाश्रितं त्वस्थिचापरम्॥
पंचमांशसमं दृष्टेस्तेषां बाहुल्यमिष्यते॥

(सु. उ. 1/18)

नेत्र का बन्धन

सिराणां कण्डराणां मेदसः कालकस्य च ॥
गुणाः कालात् परः श्लेष्मा बन्धनेक्षणोः सिरासुतः ॥

(सु. उ. 1/19)

नेत्ररोग की साधारण सम्प्राप्ति

सिरानुसारिभिर्दोषै विगुणैरूर्ध्वमागतैः ॥
जायन्ते नेत्रभागेषु रोगाः परमदारुणाः ॥

(सु. उ. 1/20)

सर्वरोगनिदानोक्तैरहितैः कुपिता मलाः ।
अचक्षुष्यैर्विशेषेण प्रायः पित्तानुसारिणः ॥
सिराभिरूर्ध्वं प्रसृता नेत्रावयवमाश्रिताः ।
वर्त्मसन्धिं सितं कृष्णं दृष्टिं वा सर्वमाक्षिवा ॥

वाग्भट

नेत्र रोगों के पूर्वरूप

तत्राक्षिलं ससंरम्भमश्रुकण्डूपदेहवत् ॥
गुरूपातोदरागाद्यैर्जुष्टं चाव्यक्तलक्षणैः ॥
सशूलं वर्त्मकोषेषु शूकपूर्णाभमेव च ॥
विहन्यमानं रूपं वा क्रियास्यक्षि यथापुरा ॥
दृष्ट्वैव धीमान् बुध्येत दोषेणाधिष्ठितं तु तत् ॥

(सु. उ. 10)

नेत्र रोग का निदान

उष्णाभितप्तस्य जलप्रवेशाद्दूरेक्षणात् स्वप्नविपर्ययाच्च ॥
प्रसक्तसंरोदनकोपशोकक्लेशाभिघातादतिमैथुनाच्च ॥
शुक्तरणालाम्लकुलत्थमाषनिषेवणाद्वेगविनिग्रहाच्च ॥
स्वेदादथोधूमनिषेवणाच्च छर्दिर्विघाताद् वमनातियोगात् ॥
बाष्पग्रहात् सूक्ष्मनिरीक्षणाच्च नेत्रविकारान् जनयन्ति दोषाः ॥

(सु. उ. १ म अ.)

उष्णाभितप्तस्य जलप्रवेशाद्दूरेक्षणात् स्वप्नविपर्ययाच्च ॥
स्वेदाद् रजो धूमनिषेवणाच्च छर्दिर्विघाताद् वमनातियोगात् ॥

शुक्तरणालाम्बुकुलत्थमाषादविण्मूत्रवातागमनिग्रहाच्च ॥
प्रसक्तसंरोदनशोकतापाच्छिरोभिघातादतिशीधपानात् ॥
तथा ऋतूनां च विपर्ययेण क्लेशाभितापादतिमैथुनाच्च ॥
बाष्पग्रहात् सूक्ष्मनिरीक्षणाच्च नेत्रे विकारं जनयन्ति दोषाः ॥

भावमिश्र

यथाः- उष्णाभितप्तस्य जलप्रवेशाद्
दूरेक्षणात् स्वप्नविपर्ययाच्च ।
स्वेदाद्रजोधूमनिषेवणाच्च
छर्दिर्विघाताद् वमनातियोगात्
द्रवान्नपानातिनिषेवणाच्च
विण्मूत्रवातक्रमनिग्रहाच्च ।
प्रसक्तसंरोदनशोकतापा
च्छिरोभिघातादतिमद्यपानात्
तथा ऋतूनांचविपर्ययेण
क्लेशाभितापादतिमैथुनाच्च ।
बाष्पग्रहात् सूक्ष्मनिरीक्षणाच्च ।
नेत्रे विकारांजनयन्ति दोषाः ।

योगरत्नाकर

नेत्र रोग संख्या

नव सन्ध्याश्रयास्तेषु वर्त्मजास्त्वेकविंशतिः ।
शुक्लभागे दशैकश्च चत्वारः कृष्णभागजाः ॥
सर्वाश्रयाः सप्तदश दृष्टिजा द्वादशैव तु ।
बाह्यजौ द्वौ समाख्यातौ रोगौ परमदारुणौ ॥
भूय एतान् प्रवक्ष्यामि सङ्ख्यारूपचिकित्सितैः ॥

The Ancient Literary references of Shalakya Tantra :-

1) Rujashwa & Kanwa were treated for the blindness by the Ashwini Kumaras - Rugveda 1-116-9 to 16 shlokas.
2) Paravruja was treated for the blindness by Indra. Rugveda-1-111-8.
3) Nahusha was treated for the deafness by Ashwini kumaras Rugveda 1-116-16.
4) Dadeechi got shira sandhanam by Ashwini kumaras.
5) Shiro mardana (in shira shoola) ref:- paraskara guhya sutra.
6) In shukla yajurveda samhitha mukha pakam (stomatitis), Arma (pterigium etc.) are explained.
7) Description of Netra shareeera in brhadaranyaka is as follows.

Raktha Raji- Adhipathi (protector) Rudra

Jala	"	Parchanna
Kaneenika	"	Surya
Shukla Mandala	"	Chandra
Krishna mandala	"	Agni
Ado varthma	"	Pruthwi
Urdwa varthma	"	Akasha

8) Atharvana vedic references
   a) Description of different parts of shalakya (E.N.T. Eye)
   b) Description of Nava Dwaras.
   c) Description of Karna shoola.
   d) Discription of Gandamala-manyaja 55 types and galaja 77 types.
   e) Krimi (of Ear, Eye, dantha, mukha)-shodhana with apamarga.
   f) Synonyms of Netra given as chakshu - Chakshmani-Netra Akshi etc.
9) Description, usage, utility of Anjanas explained in Ithareya brahmana.
10) In Chakshushyopanishath 40 to 45 mantras are explained for the improvement of vision through suryopasan.
11) The references are also available from vishnu purana, Agni purana, Geetha, Ramayan and Maha Bharath etc.

By the above references it is obvious that the science of shalakya tantra (medical & surgical) is existing since time of vedas.

Description of Shalaka - Shalakya tantra:-

Neither charaka nor sushrutha defined the word " Shalakya ", but Dalhana has given the meaning as, Shalakayah yath karma kriyathe taccha shalakyam " shalaka is an instrument used frequently in the diagnostic and treatment procedures of this branch so only it is named as shalakya and the science (tantram) is named as shalakya tantram (" Trayathe anena ithi Tantram - the science that protects the body is explained as tantram.)

Shalaka is an instrument used to pierce or to cut the Netra patalas (Tunics of eye ball) Though it is mentioned as Netra patalas it is also applicable to the ear nose and throat (Shivadasa Sena)

The science that deals with the discription and treatments of shravana (ear), Nayana (eye), vadana (mouth) and ghrana (Nose), which are situated above the Jathru (Greeva moola or Akshakasti or clavicle) is named as shalakya tantra.(Sushrutha)

Synonyms
(1) Shalakya Tantram
(2) Urdwanaga Chikitsa
(3) Jathru Urdwa Chikitsa
(4) Utthamanga Chikitsa.

(1) Shalakya Tantra
It is the science in which " Shalaka " is used frequently for the diagnosis as well as treatment of ear nose throat and eye diseases, which are seated above the Clavicle.
(2) Urdwanga or Jathru Urdwa Chikitsa :- It is the science that deals with the organs seated above the Jathru /clavicle) so only named as Jathru Urdwachikitsa or Urdwanga Chikitsa.
(3) Utthamanga Chikitsa :- Shiras (Head) is explained as Utthamangam for the existence of pranas Indrias and its belongings in it, so only shalakya Chikitsa is named as Utthamanga Chikitsa.

While describing the importance of uttamanga, vagbhata compared the shiras to the root of tree and body to the stem of the tree. If the root is nourished tree survives, if not destroys, like wise if the head is protected health is maintained, if not death follows. So only it is advised to protect the shiras against the injuries and diseases and it is explained as utthamanga chikitsa.

" The specialists of shalakya is known as shalakini or shalaki ".

4) **Galava :-** 1) He also attended the Rishies assembly (gathering) which was conducted near by Himalayas.2)He has written the Shalakya tantra, Sarvaloka Chikitsa, Rigveda Krama patha, Shiksha pranayana,Vyakarnana, KamaShastra etc.3)He is the disciple of Dhavanthari (Dalhana's reference)

5) **Sathyaki :-** 1) Dalhana mentioned his name as the author of shalakya text.2) His name is famous - He introduced the coucching system of treatment for cataract, even now this method is practising by some people in north India.(The tradition is known as sathyakeeya sampradaya or Sathiye. 3) According to him Netra rogas are. 80.4) He is the brother of Lord ShriKrishna and friend of Arjuna. 5) He mentioned shirah kampa as incurable disease.

6) **Chakshushyena tantram : -** The reference is given by Gananatha sena and Shrikantha as it is a book on Shalakya tantra.

7) **Bhoja :-** He worked on shalya and shalakya, book is known as Bhoja samhitha or Bhoja prabandha, the references are given by Gayadasa and Dalhana.

8) **Bhrugu Tantra :-** The Book is not available now, his yogas are present in the available shalakya books for the treatment of Timira, shukra, etc.

9) **Krishnathreya :-** Son of Atri and Chandrabhaga, Because of different references the exact identity is difficult. The reference is given by Srikantha datta and shivadasa sena. These people mentioned so many yogas of Atreya, in their texts.

10) **Shaunaka Tantram :-** The Book is not available, His name is famous in the history but the perfect identity is difficult as the author of shalakya text.1) According to chakrapani & Dalhana he is known as the author of Shalakya text.2) He attended the rishi parishad which was conducted at near by Himalayas.3) He is the author of the book Bhriha.devatha.4) His shalakya references available in Sushrutha Shareera 3-32 (Dalhana commentory) charaka sutra 11th chapter (Chakrapani. comm) Shaunaka, Bhadra Shaunaka, madra Shaunaka etc names available in the History. Acharya Gananatha sena said that above people are not one they are separate individuals.

" Neither Nimi Tantra Nor other books available.

NETRA SHAREERAM

(Anatomy of eye - Ayurvedic aspect)

Synonyms :- Netra, Nayana, Chakshu, Akshi, Netra Golaka, Nayana budbuda, Akshi golaka, Drusti, Linga etc.

Netra uthpathi : - It is gyanendria adhistanam meant for rupa grahanam (for the perception of vision) .

1) Indrias derived from atma, in particular Netra Indriam derived from agni maha bhuta Sushrutha.
2) Satwa guna + Raja guna + Agni bhutha = Chakshurendriam (A.H)
3) Drusti is formed by the essence of Kapha, Raktha and Panchamaha bhutas. Shukla Mandalam - by the essence of Kapha (Pithruja) Krishna Mandala by Raktha (Mathruja), and Drusti mandala By both (A.Sangraha).
4) Drusti formed by the essence of pancha maha bhutas with agni bhuta predominence.

Mamsa	-	By pruthwi maha bhuta
Raktha	-	Agni
Krishna Mandalam	-	Vayu
Swetha Mandalam	-	Jala
Ashru Margam	-	Aakasha

Anatomical words of Netra available in old Samhitas:-

Pakshma (eye lashes), varthma (eye lids), swetha mandala (Sclera - bulbar conjunctiva), Krishna Mandal (Cornea - iris), Drusti mandala (pupil - Lens - retina), Pakshma Varthma sandhi (Lid Margins), Krishna drusti sandhi (Pupillary margin), Kaneenika sandhi (inner canthus) Apanga sandhi (outer canthus), Patala (Tunics,) Ashru Pinda (Lacrimal gland), Ashru Sira (Lacrimal Ducts), Ashru Vahini (L. Canaliculi) Netra nadi (Optic nerve).

TRANSLATED WORDS AVAILABLE IN LATEST BOOKS

Sautrika Patala (Fibrous coat), Raktha vahini maya ranjitha patala (Vascular layer), Nadi Patala (Nervous Layer), Bahya patala (Sclera), Krishnamandala, (Cornea), Taramandalam (Iris), Madhya Patala (Choroid), Sandhana mandalam or Tanthu samuha (Cilliary body), Sandhana peshi (Cilliary muscle), Kaneenika Sankochaka (constrictor Pupillae), Kaneenika Vispharaka (Dilator Pupillae) poorva jala maya rasa Khanda (Anterior chamber), Jalamaya rasa or Tejorasa (Aqueous humour), Pashchima khanda (Posterior chamber), Sandra medo drava (Vitreous humour), Drusti peetha (Macula Lutea), Nadisheersha (optic disc), drusti vithana or Drusti patal (Retina), Bhru (eye brow), Tala bandhan (Suspensary ligament) Drusti Patalantharbhaga (ora serrata), Netracchada or varthma (eye lids), Ashru dwara (punctum), Ashrunala (Lacrimal canaliculi), Ashru aashaya (lacrimal sac), Ashru pinda (Lacrimal gland), Nasa gatha Ashru vahika (Naso Lacrimal duct).

8) Videhadipa keerthitha - Nimi Praneetha - videha vachanath these 3 words are generally used by the commentators - That indicates they are one but called differently.

9) As per Brahma vyvartha purana, Janaka is the disciple of lord Surya.

10) According to shalihothri samhitha - Ist part 104 page Janaka and videha were explained as different persons.

11) In Gada nigrah he used the names of Nimi and videhadipa, word as synonyms so it is very difficult to conclude whether Nimi Janak and videha are one or different. But majority accepts that they are one.

Nimi's period :-

1) He Studied shalakya (Ayurveda) from Indra, along with Aathreya, Kashyapa, Dhanwanthari, Alambayan. So Nimi and above Acharyas were of same period. A.S. Sutra Stana 2nd page.

2) In Chaithra ratha vanam - In a Meeting he participated along with Athreya, Kankayan etc. Cha-Sutra Stana 26 Chapt.3-7 Pages.

3) In Alochana gosti he participated along with varyovid and Kankayan Kashyapa Samitha sutra, 27 Page.

4) He Lived 200 yrs before Maha Bharatha Yuddham (Baudha Jathaka Kathas)

5) He lived 320- 350 years before Dhanwanthari (puranas).

6) Because of Vashista Abhishapa he lost his body so they were(Nimi and Vashista) of same period.

7) Nimi (the king of Ayodya and) vikukshi shashada, pururava were of same period.

Because of inperfect history, it is not possible to fix the time of Nimi.

A story related to Nimi :- (Reference) Bhagavatha Navama Scanda (9th Scanda) Trayodasha Adyaya (13th chapter)

Once the king of videha - Nimi - proposed to conduct a yagyam along with Brahmins. He asked Rajarshi vashista to be as purohith to complete the yagyam. But because of previous appointment with Indra (Deva Raja) he got ready to go to heaven and said to Nimi to wait upto his arrival. Vashista did late so Nimi Completed the yagyam with other Brahmins. After his arrival Vashista heard the news, got angry and cursed Nimi to lost his body. Devatas were pleased with Nimi's yagyam and blessed him for rebirth. But Nimi refused to enter into his old body, then devates told him to stay in the eye lids of the people. The opening and closing of eye lids is termed as Nimesha, it is derived from the word Nimi for his presence in the eye lids.

For taking rebirth he is called as Janaka. His dead body was undergone Manthama so he got named as Mithi, he lost his body by vashista Abhishapa and remained without body so he was named as Videha. (king of Videha) By staying in eye lids and performing Nimeshana kriya (opening and closing of eye lids) he is named as Nimi .

2nd story :- Once videha raja-Rajarshi Janaka Conducted Alambha yagya along with Brahmins - Bhagavan Amshumali cursed him to lost his sight - Janaka did Tapas, Lord surya was pleased and taught Chakshurveda (Science of Opthalmology) to Janaka, like that Shalakya tantra was brought to earth.

Other Rishies who worked on Shalakya

1) **Kankayana tantram : -** It is not available now, the book reference is given by Dalhana.
   1) He attended the meeting which was arrranged by Dhanwantari (Dalhana)
   2) He is the Doctor of Bahleka (Bahleeka Bhishak) (Charak)
   3) He had so many disciples (Gadanigraha Ist part 103 Page)
   4) He Participated in the meeting (Panditha sabha)along with Nimi, Bhoja etc. which was conducted near by Himalayas (Himavath Parvatha Parshwa).
   5) The Medicine Kankayana vati might be his remedy.
   6) He was at Romapada assembly (Aasthana vaidya) (Palakapya Hastyayurveda)
   7) 4 yogas were mentioned by him - (reference History of Indian medicine 2nd part - 465/466 pages)

2) **Karala Tantra :-** Written by A) Karala Bhadra or a) Karala bhatt, It is not available, the book reference is given by Gireendhranatha Mukhopadyaya and Shri, Gananada sena. He is also named as Karala Janaka Ref: (Shalihothra) According to him Netra rogas are 96 (Ref : Chakrapani), Nimi was his teacher. (Ref:- Astanga Sangraha Sutra Sthana)

3) **Garghya :-** In the History Garghya name reference is available at different places, and identity is very difficult.
   1) He attended the maha rishies meeting which was arranged near by Himalayas.
   2) He was in the assembly of Romapada (Palakapya Hastyayurved).
   3) Kashyapa, panini and yask mentioned his name .
   4) Garghya, Galava Nimi, Kankayan were of same period (Dalhan)
   5) He is the author of shalakya tantra (Harishastri in A. Hrudaya).
   6) He is also expert in vastu and vyakarana.

Note :- 1to 6, Translated names for extra ocular muscles and 7to 10 " " Nerves, they are

1) Bahyasta sarala or sarala bahir netra chalani or bahir darshini (Lateral rectus Muscle).
2) Antasta sarala or Saralantar netra chalani or Antar darshini (Medial rectus muscle).
3) Urdwasta sarala or sarala urdwa netra chalani or adho darshini (inferior rectus).
4) Urdwasta vakra, vakrodwa netra chalani or vakrordwa darshini (superior oblique muscle).
5) Adhasta vakra or vakradho netra chalani or vakradho darshini (inferior oblique muscle) 6) Druk nadi (optic nerve) 7) Netra Chestani nadi (Oculo motor nerver) 8) Katakshinee nadi (Trochlear nerve) 9)Tridhara nadi (Trigeminal nerve)

Netra Shareer :-

Nayana budbudam (eye ball) is almost in round shape and resembles the teet of a cow (Go sthanakram) it is formed by the essence of Panchamaha bhutas (Pancha bhutha prasadajam) with Agni bhutha predominence.

Netra pramanam :-

"I angula =Breadth of thumb (individuallly)(Swa angustodara Sammitham) Bahulyam =2 angulas and sarvatah pramana 2 1/2 angulas and the commentry is as follows but not confirmatory

1) Bahulayam of Netra :-
or
Agra pashchath pramanam
or
Antah pravesha pramanam = Dwi angulas (Two angulas)
or
Antero Posterior diameter (some authors)

2) Sarvatah Pramanam
Aayama and Visthara
a) Aaayama or
Poorva Pashchima Pramanam or = 2-1/2 angulas (Dalhana 3-1/2 angula
Antero Posterior diameter or
Vertical diameter

b) Visthara or
Utthara dakshina pramana or = -do-
Horizontal diameter

Note :- Discription of Natra sharera having controversy. Ex. some authors discribed the aayam - visthara means circumference of eye ball, and the distance between kaneenika to apanga.

3. Krishna mandalal pramanam
(Netraayama tri bhaganthu krishna mandalamucchyathe)

A) = Netra Aayama / 3 = 5/2/3 = 5/6 angulas

(B) Dwi yava pramanam (Dalhana)

4) Drustimandala Pramanam :-

a) (Krishnaath saptha micchanthi drusti)
Krihsna mandala pramanam / 7
= 5/6/7 = 5/42 angulas (S.U. 13)

b) (Navama stharakamsho drusti)
Krihsna Mandala pramanam / 9
5/6/9 = 5/54 angulas (SU. sutra)

c) Masura dala pramanam

d) Artha masura dala pramanam (Sarangadhara teeka)

5) Patala pramanam :-
Drusti pramanam / 5 (Pancha mamsha samam drusti)
5/42/5 = 1/42 angulas

Eye ball is formed by the essence of pancha mahabhutas, the following parts are formed by the corresponding bhutha predominence.

Part of the eye	Bhutha predominence
1) Mamsa	Pruthwi maha bhutha
2) Raktha	Agni "
3) Krihsna Mandalam	Vayu "
4) Swetha mandalam	Jala "
5) Ashru margam	Aakasha "

Parts of Nayana budbuda (eye ball)

1) Mandala	Circles of eye ball	-	5
2) Sandhies	Junctions of "	-	6
3) Patalas	tunics of "	-	6

NETRA MANDALA

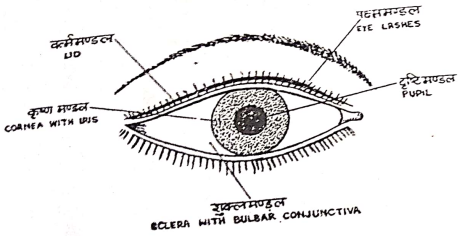

NETRA SANDHI

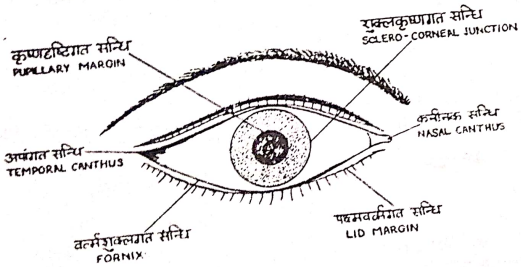

A) Mandalas

Five in number, having circular form, arranged in " anu purva " order (From with out to inwards) Ex. Pakshma mandalam is the outer most part and the drusti mandalam is the most interior part.

1)Pakshma mandalam - Circle of eye lashes
2) Varthma mandalam - circle of eye lids
3) Swetha or Shukla Mandam - Sclera and bulbar conjunctiva.
4) Krishna Mandalam - Cornea and Iris

(Infact cornea is colour less fresh and transparant, but appears black due to the iris which is exactly behind)

5) Drusti mandalam - (pupil - lens - Retina.)
1) It is in the size of masura dala 2) Formed with the pancha maha bhutas
3) Having vivara Akruthi (circular or hole like)
4) Shines like khadyotha (Spark like) 5) Covered by a layer infront
6) Cool things or items are helpful or suitable.

Note :- Detailed description is given at Drusti rogas.

B) Sandhies : - Junctions betweeen mandalas, 6 in number, they are
1) Pakshma varhtma sandhi -(Lid margins) junction between eye lid and eye lashes.
2) Varthma shukla sandhi - Fornix (superior & inferior) originally it is the fold of conjunctival sac, but appears to be sandhi of varthma and shukla mandala (If we take palpebral conjuctiva the internal lining of varthma as varthma, and shukla mandala as bulbar conjunctiva its juction is exactly the fornix).
3) Shukla Krishna sandhi - (Limbus) sclero corneal junction.
4) Krishna drusti sandhi - exact identity is not possible, but can be taken as pupillary margin. 5) Kaneenika sandhi - inner canthus, It is the junction of 2 lids at Nasal side (nasa sameeepa sthitha sandhi (Dalhana), 6) Apanga sandhi - outer canthus. It is the junction of 2 lids at temporal side. (Bhru pucchantha sthitha sandhi) (Dalhana)

c) Patalas :- 2 varthma patalas (eye lids)
4 Akshi patalas
Total 6

Netra patalas :- It is the site for the dreadful disease timira (immature cataract) and Linganaasha (Mature cataract) exact correlation is not possible to patalas. But can be understood asthe tunics of eye ball which are responsible for the refraction (Refractive media).

Ist patala :- Tejo jalaashrayam
Tejo :- Alochaka pittashraya Rakthadhathu.
Jala :- Twak aashraya rasa dhathu.

The cornea + aqueous humour which is the Ist layer of Refractive media can be correlated to the Ist patala.

(Teja - bright transparant cornea, Jala - Transparant, watery aqueous humour)

2nd Patala

PISHITHAASRITHAM (musclular layer)

The second layer of eye ball, Iris, cilliary body and (choroid) which is behind the cornea can be compared to 2nd patala, probably for containing cilliary muscle constrictor and dilator pupillae muscles, which are responsible for accommodation, contraction and dilatation of pupil.

3rd Patala :-

MEDO AASHRITAM (Fatty Layer)

It is the layer, that should be interior to musclular layer, for the correlation different opinions present, they are as follows.

a) Lens is explained as 3rd patala for its position next to uvea (2nd layer).
b) Vitreous is explained as 3rd patala for appearing like medas (fat).
c) Lens, and vitreous together explained as 3rd patala by most of the authors.

4th Patala :-

ASTI PATALA (Bony layer)

Exact correlation is not possible, different opinions are here under.

a) Some authors explained Lens as Asti Patala because of its solid appearence and gving seat for the dreadful disease timira (Videha said that Timira vyadhi is patalashritha vyadhi)
b) Some authers named it as Akshi patala and told Retina as 4th patala which is responsible for rupa garahanam (Visual perception)
c) Some authors explained the 4 patalas as the tunics of lens which is the seat for Timira vyadhi (Cataract).

Note :- Some sanskrit Commentators counted the number from interior to exterior as Asti Aashraya " Ist patala
Medo " 2nd patala
Mamsa " 3rd patala
Tejo Jala " 4th Patala

It is opposite to the previous explanation. Because of the different opinions, exact correlation and conclusion of patalas is not possible.

Vagbhata :- He has not mentioned the number of sandhies, and not explained the pakshma mandala in mandalas.

Bhavamishra :- He has not explained the number of sandhies.
Sarangadhara :- First mentioned the sandhies as 4 and the 5th Kaneenika sandhi explained during the discription of the disease and left the 6th Apanga sandhi (5 sandhies explained).
Yogarathnakar :- He explained just like Sushrutha but counted the Netra Patalas as 4 (he left the 2 Bahya Patalas)

Netra Kriya Vigyan

Indriartham	Gyanendriam		Predominent Bhutamsha
Shabda	Experienced by	Shravan indriam	Akasha
Sparsha	"	Twak "	Vayu
Rupa	"	Nayana "	Agni
Rasa	"	Jihwa "	Jala
Gandha	"	Ghrana "	Pruthwi

One Indiriam receives its specific Indriartham only - because of common bhutha predominence between them.

Ex. eye (Nayanendriam) Receive Rupam because of Tejo predominence.
For perception of Indriartham by Indrias the following things are needed.

Aatma - Manas - Indrias - Indriarthas

If this chain is interrupted, objects are not received

Ex.:- In the absence of concentration (Anya manas while thinking some thing else), a person can't identify the things though he has observed.

Aatma along with manas stimulates the Alochaka pitta which resides in the eye, by that external objects are focussed and stimulus carried through the vata vahini srotas and with the Interference of Indria bhudhi (Darshana Bhudhi) only the objects are visualised and distinguished accordingly.

NETRA GUHA (Orbit)

Synonyms :- Shrungataka, Bhruchakra , Akshikuta ,Netra guha

Contents of shrungataka (orbit) according to Ayurvedic science.

1) Eye ball (Netra)
2) Eye lids (Varthma)
3) Veins arteries nerves (Sira, damani, Nadi)
4) Kosha - (Sacs :- conjunctival sac & Lacrimal sac etc)
5) Ashruvaha shrotas (Lacrimal gland and Lacrimal apparatus.)

Clear discription is available about the Lacrimal secretion and its flow in samhitas.

1) Lacrimal fluid is secreted by Ashru pinda (L.gland)
2) Through sira (Ashru pranalika) (Jala vahini) the fluid reaches Netra sandhi (Videha) or varthma shukla sandhi (Vagbhata) (i.e. fornix)
3) From Netra sandhi the fluid collects in the Kaneenika sandhi (inner canthus) From here the fluid is eliminated out

CONTENTS OF ORBIT THAT BINDS THE EYE BALL

Eye ball is fixed properly in the orbit by the following contents.

1) Sira (Veins arteries and Nerves)
2) Kandara (Tendons and Ligaments)
3) Meda - orbital fat
4) Kalakasti - Fascia that is attached to the bony cavity
5) Sleshma bandana - especially the eye ball is supported by the orbital fat.

ANATOMY OF ORBIT (AKSHI GUHA - NETRA GUHA)

The orbits are a pair of pyramidal cavities, situated one on each side of nose, it appears like dathura flower. Orbits are formed by the combination of following 7 bones

1) Frontal bone (Lalata asthi) 2) Sphenoid bone (Jathukaasthi)
3) Ethmoid bone (Bharbharaasthi) 4) Maxilla (Urdhwa Hanu asthi)
5) Palatal bone (Talu asthi) 6) Lacrimal bone (Ashru asthi)
7) Malor bone or zygomatic bone (Gandaasthi.)

Measurements of orbit :- Antero posteriorly -5 to 8 cm. Vertically (at base) and Horizontally (at base) 4 c.m.

Parts of orbit :- 1) Base 2) Apex 3) Roof (Superior wall) 4) Floor (inferior wall) (5) Medial wall) 6) Lateral wall.)

1) Base :- It is known as orbital margin, quadrangular in shape directed forwards. laterally and slightly downwards.

Formed above by 1) Supra orbital margin of frontal bone
Laterally by 1) Frontal process of zygomatic (mainly)
2) Zygomatic process of frontal (partly)
Inferiorly by 1) Zygomatic bone (Lateral half)
2) Maxilla (Medial half)
Medially by 1) Anterior Lacrimal crest of the frontal process of maxilla.
2) Medial end of the supra orbital margin of frontal.

2) **Apex :-** It corresponds to the optic canal which is behind and towards medially, it is at the medial end of the superior orbital fissure.

3) **Roof** :- Triangular and concave, separates the orbital cavity from anterior cranial Fossa.

Formed by : a) Orbital plate of frontal bone, infront
b) Under surface of lesser wing of sphenoid, behind

It contains :- 1) Lacrimal fossa for the orbital part of Lacrimal gland.
2) Trochlear spine or fossa -Gives attachment to superior oblique muscle of orbit.
3) Optic canal - transmits optic nerve (Drusti nadi) and ophthalmic artery.
4) A common tendinous ring gives origin to intra ocular muscle

4) **Floor :-** Formed by 1) Orbital plate of maxilla (mainly)
2) Orbital plate of zygomatic bone, antero laterally
3) Orbital Process of palatine bone, posterio medially

It separates the orbital cavity from maxillary air sinuses.

It contains :- 1) Infra Orbital groove and canal for the Transmission of infra orbital vessels and nerves.2) Upper opening of Naso Lacrimal canal at antero medial angle 3) A small depression, lateral to the upper opening of Lacrimal canal gives origin to inferior oblique muscle of orbit.

4) Inferior orbital fissure:-Lies between the floor and lateral wall posteriorly. It transmits 1) Maxillary division of Trigeminal nerve (5th cranial nerve) 2)Zygomatic nerve 3) Branches of spheno Palatine ganglion 4) Infra orbital artery 5) Branches from inferior ophthalmic vein to the pterigoid venous plexus.

5) Medial Wall :- QuadriLateral in shape, medial walls of the two orbital cavities are almost parallel to each other.

Formed by (from before backwards)
1) Frontal process of maxilla. 2) Lacrimal bone
3) Orbial plate of the labrynth of ethmoid bone. 4) Body of sphenoid.

It separates the orbital cavities from ethmoidal air sinuses and the anterior part of sphenoid air sinuses.

It contains :- 1) Lacrimal groove for lacrimal sac, this groove separates the orbital cavity from Nasal cavity.

2) Anterior lacrimal crest of the frontal process of maxilla gives attachment to medial palpebral ligament, lacrimal fascia and gives attachment to orbicularis oculi.

3) Posterior lacrimal crest of the lacrimal bone gives attachment to lacrimal fascia and gives origin to lacrimal head of orbicularis oculi.

4) Anterior and posterior ethmoidal foramina for the transmission of corresponding vessels and nerves.

6) Lateral Wall :- It is the thickest of all parts of orbit and separates the orbital cavity from middle cranial fossa, formed by 1) orbital surface of the frontal process of zygomatic bone infront 2) orbital surface of the greater wing of sphenoid, behind.

Contains :- 1) Openings for zygomatico facial and zygomatico temporal nerves. 2) A small tubercle, lower to the superior orbital fissure, gives origin to intra ocular muscles of the orbit.

3) Superior orbital fissure lies between lateral wall and roof posteriorly, gives transmission for 3rd (Netra chestanee nadi, oculomotor) 4th (Katakshinee nadi-Trochlear Nerve, 6th (Netra parshwaki Nadi-Abducent nerve) and Ist part of trigeminal nerve). Ophthalmic vein, recurrent lacrimal artery, sympathetic fibres from cavernous sinus and cilliary ganglian.

In Brief :- The follwing openings (foramina) Present in <u>orbit</u>

1) Optic foramina for optic Nerve
2) Superior orbital (foramina) Fissure for 3,4,5 (Ist division) and 6th cranial nerves.
3) Inferior orbital (Foramina) fissure for 2nd divison of 5th cranial nerve.
4) Anterior and posterior ethmoidal foramina for corresponding vessels and nerves.
6) Lacrimal canal
7) Openings for zygomatico temporal and zygomatico facial nerves.
8) Supra orbital fissure | for corresponding vessels and nerves.
9) Infra orbital fissure

Contents of orbits

1) Eye ball and intra orbital part of optic nerve
2) Tenon's capsule (it forms a socket in which eye ball moves, it extends from limbus to the attachment of optic nerve.)
3) Extra ocular muscles for the movement of eye ball in different directions (4 Recti muscles and 2 oblique muscles).
4) Lacrimal gland and lacrimal sac.
5) Ophthalmic artery with its branches.
6) 3rd, 4th, 5th (ist and 2nd branches only) and 6th cranial nerves
7) Branches from carotid and cavernous plexus of sympathetic.
8) Cilliary ganglian 9) Orbital fat and fascia

(Description will be given at relevent chapters).

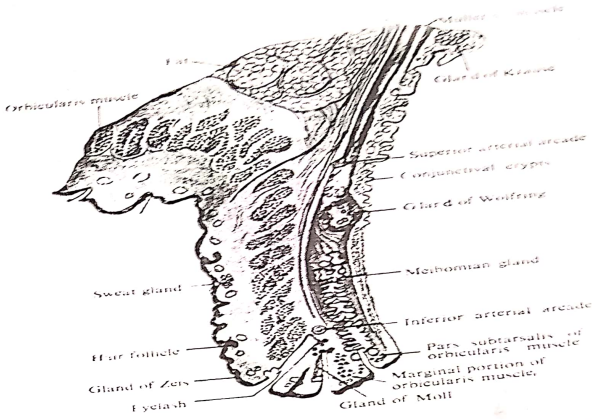

Fig 10.4 Vertical section through th

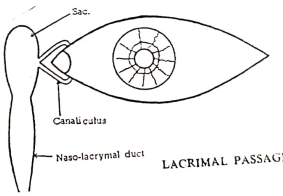

LACRIMAL PASSAGE

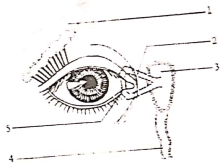

Lacrimal system: *1*—lacrimal gland, *2*—lacrimal duct, *3*—lacrimal sac, *4*—naso-lacrimal duct, *5*—lacrimal punctum

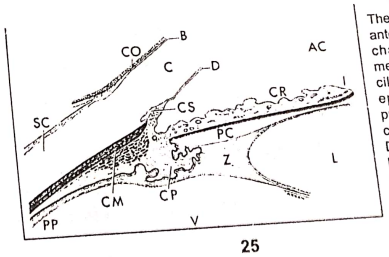

The region of the angle of the anterior chamber:AC, anterior chamber; B, Bowman's membrance; C, cornea; CM, ciliary muscle, CO, corneal epithelium; CP, ciliary processes; CR, iris crypts; CS canal of Schlemm; D, Descemet's membrance; I, iris; L, lens; PC, posterior chamber; PP, pars plana of ciliary body; SC, sclera; V, vitreous; Z, zonule of Zinn

The above mentioned structures are supported in the orbit by orbital fat. The periosteum lining the bony walls of the orbit is called peri orbitan; infront the orbital base is partially closed by a septum extending from the upper and lower orbital margins to the tarsal plates known as septum orbitale.

Arterial supply :- Ophthalmic artery branch of Internal carotid artery.

Veins :- Drain into ophthalmic veins

Nerve Supply

Motor:-

Superior rectus muscle	=	4th cranial neve
Lateral rectus muscle	=	6th cranial nerve
rest of 4 muscles	=	3rd cranial nerve

Sensory :- 1st and 2nd divisions of Trigeminal Nerve (Ophthalmic nerve and maxillary nerve)

Anatomy of eye lids

The eye lids are mobile tissue curtains placed infront of the eye ball, for protective functions, formed from before backwards by skin (Anterior part), loose connective tissue, muscle, tarsal plate, fascia and conjunctiva (posterior part). the eye lashes are attached to its margins, the lids contain glands, blood vessels, lymphatics and nerves.

The parts of eye lid can be divided like the following :

1) Cutaneous layer 2) Muscular Layer
3) Fibrous Layer 4) Mucous layer

1) Cutaneous layer :- It contains the skin of the eye lid which is extremely delicate, highly elastic and is covered with fine downy hairs. On looking straight or upwards a horizontal fold is visualised in the upper eyelid. Underneath the skin is the loose areolar tissue with no fat and is loosely attached to its underlying muscle and permits for easy accumulation of oedematous fluid or for the extravasation of blood underneath the skin.

2) Muscle layer :- Underneath the skin and cutaneous tissue is the muscle layer which consist of

a) Orbicularis oculi muscle :- It is an oval sheat of concentric muscle fibres, it covers the lids and the orbital margins.By contraction of this, the lids are firmy closed it is supplied by zygomatic nerve branch of facial nerve.

b) Levator palpebrae superioris - Present only in upper lid. Arises from the apex of orbit, passes underneath the roof and is inserted into the skin, upper parts of tarsus, fornix, conjunctiva and mid points of lateral and medial orbital margins. It is helpful for raising the upper lid (opening of eye) and is supplied by upper division of occulomotor nerve (3rd cranial)

3rd Palpebral muscle of Muller :-

These are sheets of plain muscles one on each lid, in the upper lid the muscle arises from the surface of levator palpebre superioras and is inserted in to the upper margin of the tarsal plate. In the lower lid muscle arises from the fascial sheath of the inferior rectus and is inserted in to tarsal plate. It is supplied by cervical sympathetic.

3) **Fibrous layer** :- underneath the Orbicularis Muscle is the fibrous layer. consist of.

a) Septum orbitale :- it is a thin membrane of connective tissue extending from the proximal border of tarsal plate to the periosteum around the orbital margin. It is perforated by vessels and nerves entering the lids from the orbit.

b) Tarsal plate :- It is a thin plate of dense connective tissue one in each eye lid. Larger in upper lid, smaller in lower lid. It is present in betweeen muscle layer and mucous layer and responsible for its firmness.

Its connections to orbit.:-

It is connected to the lateral walls of orbit by medial and lateral tarsal ligaments and to the upper and lower borders of orbit with an aponeurotic fibrous layer known as palpebral fascia.The plate contain numerous meibomian glands (Sebacious glands) secretes oily secretion on to the lid margin.

4) Palpebral conjunctiva is thin, vascular and closely adherent to the tarsus.

Glands of the eye lids :-

There are 3 types of glands in th eye lids.

1) **Meibomian glands** :- Elongated glands, vertically placed in the tarsus and also known as tarsal glands, 30 to 40 glands in upper lid and 20 to 30 glands In the lower eye lid these are modified sebaceous glands, Secret olly secretion and opens to the lid margin just infront of its sharp posterior border.

2) Glands of zeis :- These are sebaceous glands developed as out growths of the epithelial wall of the hair follicles of the eye lashes, situated on the lid margin and opens into the follicles of the eye lashes.

3) Glands of Moll :- These are modified sweat glands, lie between the cilia on the lid margin, ducts open either into ducts of zeis or into follicles of cilia, and not directly on to the the surface of lid margin.

Lid margin : - It is the Anterior thick border of eye lid, the Anterior margin is rounded from which eye lashes originates and posteriorly sharp margin present. In betweeen anterior margin and openings of the meibomian glands there is a grey line konwn as inter marginal sulcus, Lid margins unite medially and laterally and form medial canthus and lateral canthus, at medial canthus a rounded space knwon as lacus lacrimalis, is present which is occupied by a small reddish elevation known as caruncle .

Eye lashes :- Stouter than hair and are arranged in 2 to 3 rows in upper lid and 1 to 2 rows in lower lid, the roots are deeply embeded in the connective tissue of the lid margin, upper lid lashes are curved forwards and upwards and lower lid eye lashes are downwards and forwards.

Arterial supply :-

1) Lacrimal Palpebral branches of ophthamic artery.
2) Facial artery
3) Superficial temporal artery
4) Infra Orbital artery.

Venous drainage :-

1) Opthalmic vein
2) Temporal vein
3) Facial vein

Lymphatic drainage :-

Outer half drains into pre auricular lymph glands, inner half drains into sub maxillary lymph glands.

Sensory nerve supply :-

Ist - 2nd branches of trigeminal nerve

Motor (1) Orbicularis oculi supplied by branches of facial nerve.
(2) Levator palpebre superioris Supplied by the branches of oculo motor.
(3) Palpebral muscle of muller supplied by the nerves derived from cervical sympathetic.

LACRIMAL APPARATUS

The Lacrimal apparatus consits of a secretory portion (the lacrimal gland,) and an excretory portion which collects the tears and drains them into the nose.

1) **Lacrimal gland :-** It is a serous gland situated at the upper and outer part of the orbit, in a depression of the orbital plate of frontal bone known as the fossa for lacrimal gland. Anteriorly the gland is deeply divided into two upper orbital part, and lower palpebral part (Situated beneath the outer part of the upper conjuctival fornix), the ducts of the Lacrimal glands are about border of the tarsal plate of the upper lid.The histological structure resembles the salivary gland

Accessory Lacrimal glands:-

The small glands exactly resembles the lacrimal glands.

1) Glands of krause :- About 20 in upper lid and 8 in lower lid deeply situated in the conjuctiva near the lateral part of fornix.
2) Glands of wolfring :- Few in number, situated near the upper border of the tarsal plate.

Blood Supply :-

Arterial Supply : - Lacrimal branch of ophthalmic artery and infra orbital branch of maxillary artery.

Venous drainage :- Lacrimal vein that opens into superior ophthalmic vein.

Lymphatic draiage :- Conjunctival & palpebral lymph nodes pass into pre auricular lymph nodes.

Nerve supply

1) Sensory :- Lacrimal branch of the ophthalmic division of trigeminal nerve.
2) Sympathetic :- Carotid plexus of cervical sympathetic
3) Motor :- Facial Nerve

Lacrimal Passage

it consists of

1) Lacrimal puncta (Upper - Lower) 2) Lacrimal canaliculi (upper - lower)
3) Lacrimal sac -1 4) Naso Lacrimal duct -1

1) Lacrimal puncta :- 2 small openings one on each lid margin, 6mm from inner canthus, visible when lids are slightly everted.

2) Canalicul :- 2 in number, starts from puncta as a tubular passage 1-2mm verticle portion, and 6 to 7 mm horizontal protion. The two (upper - lower) Canaliculi open into the Lacrimal sac.

3) Lacrimal sac:- 13mm long and 6mm wide sac, situated in the lacrimal fossa, 2 canaliculi open at its lateral wall, inferiorly it is continuous with naso Lacrimal duct.

4) Naso Lacrimal duct:- Continuation of the sac, moves downwards and ends in the inferior meatus of the Nose.

Arterial supply: -(1) Palpebral branches of ophthalmic artery
2) Angular branch of facial artery.
3) Infra orbital & spheno palatine branches of internal maxillary artery .

Venus return:- Above into angular and infra orbital veins, below into pterigoid plexus and internal maxillary vein.

Lymphatic drainage:-Drains into sub maxillary lymphnodes.

Nerve supply :- Nasocilliary nerve & anterior superior alveolar nerve.

Sympathetic :- Sympathetic nerves in the orbit.

LACRIMAL PASSAGE

Lacrimal glands secret the lacrimal fluid
Through Lacrimal ducts drains into Superior fornix of conjunctival sac
By gravity it comes to Inferior fornix of conjunctival sac
and collects at Lacrimal Lake of inner canthus,
Then through Puncta enters into Lacrimal Canaliculi
From both canaliculi it opens into Lacrimal Sac
Through Naso Lacrimal duct enters into Inferior meatus of Nose.
Like this the lacrimal fluid finally reaches the nose and evaporated by the heat of inhaled air.

CONJUNCTIVA

Conjunctiva is a thin layer of mucous membrane which lines the under surface of eye lids and is reflected on to the anterior part of eye ball, forming a sac called conjunctival sac. It is named differently according to site they are

1) Palpebral conjunctiva
   a) Marginal b) Tarsal c) orbital
   a) Marginal - Lid margin to sulcus subtarsais.
   b) Tarsal - Conjunctiva that covers the tarsal plate
   c) Orbital - rest of the conjuctiva that covers the eye lid.

2) Fornix, Fold of conjunctiva formed by the reflection of the mucous membrane from the lid to the eye ball.

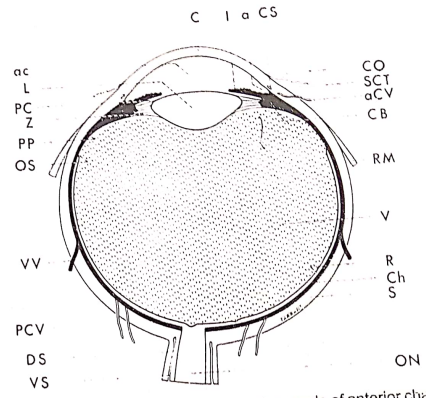

Diagram of a longitudinal section of the eyeball: a, angle of anterior chamber; ac, anterior chamber; aCV, anterior ciliary vessel; C, cornea; CB, ciliary body; Ch, choroid; CO, ocular conjunctiva; CS, canal of Schlemm; DS, dural sheath; I, iris; L, lens; ON, optic nerve; OS, ora serrata: PC, posterior chamber; PCV, posterior ciliary vessel; PP, pars plana; R, retina; RM, rectus muscle; S, sclera; SCT, sub-conjunctival tissue; V, vitreous; VS, vaginal sheath; VV, vortex vein; Z, zonule

EXAMINATION OF THE EYES AND THE VISUAL FUNCTIONS

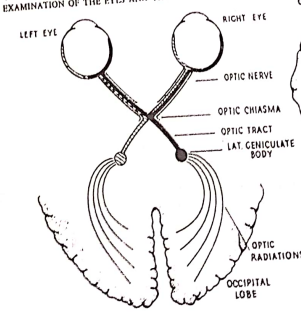

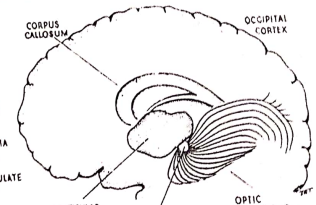

DIAGRAMS TO SHOW THE ARRANGEMENT OF THE VISUAL TRACT

3) Bulbar conjunctiva - It covers the anterior part of eye ball upto the limbus.

4) Conjunctiva of the Limbus
Conjunctiva that covers the Limbal area (Sclero corneal junction)

5) Plica semilunaris - It is a crescentric fold of conjunctiva at inner canthus.

(The marginal Tarsal and Limbal conjunctiva firmly fixed to subjacent tissues and Bulbar, orbital, fornix conjunctiva loosely attached to the underlying tissues.)

Histology :-
1) Epithelial layer 2) substantia propria a) adenoid layer b) fibrous layer.

Arterial supply :- Anterior and posteior conjunctival vessels.
venous :- Palpebral and ophthalmic veins.
Lymphatic :- Lymphatic channals of skin
Nerve supply :- sensory - a) cilliary nerve, b) Lacrimal nerve c) supra & infra trochleor nerves d) sympathetic plexus.

ANATOMY OF EYE BALL

Eye ball may be considered to be a highly differentiated end organ of optic nerve, which is a sensary nerve, eye balls are two, and placed in a quadrilateral bony cavity known as orbit. It is slightly assymmetrical sphere

Topography of eye ball
Antero posterior diameter -] 24.15mm (outer) 24.12mm (inner)
or
Sagittal diameter

Transvers diameter - 24.13 mm
Vertical diameter - 24. 48 mm
Circumference - 74.91 mm
(Dimensions are 1/2 mm less in ladies)
weight of the eye ball 7.5 grams
Volume of the eye ball 6.5 cc

Eye ball is merely a round structure consisting of an inelastic wall with a cavity inside, the wall is formed of 3 coats or tunics, they are
1) Outer fibrous coat, (2) middle vascular coat, 3) Inner nervous coat.

1) Fibrous coat :- It is outer inelastic supporting membrane of eye ball.
a) Anterior 1/6th part, transparent cornea .
b) Posterior 5/6th part, opaque sclera.

a) Cornea :- It is the clear, colourless smooth, transparent, anterior 1/6th part of outer fibrous coat, looks elliptical anteriorly and circular posteriorly, its curvature is not uniform, central part is (4 mm) in sphierical, thinner, optical zone and the flattened, thicker part is peripheral zone.

Horizontal diameter	11.7 mm
Vertical diameter	10.6 mm
Radius of anterior curvature	7.8 mm
Radius of posterior curvature	6.8 to 7 mm

Thickness
Peripherally 1.1 mm
Centrally o.6 mm

Micro anatomy of cornea :-
Cornea is composed of five layers from out to inwards
1) Epithelial membrane (2) Bowman's membrane
3) Substantia propria (Stroma) (4) Descemet's membrane
5) Endothelial membrane.

1) Epithelium :- It is regarded as the continuation of bulbar conjunctiva. 1/10 of the total thickness of cornea (50 to 100 u) stratified squamous in structure, superficially flattened, middle polygonal, deeper columnar cells and are arranged paralelly in uniform order thus prevents the admission of water salts, respiratory gases into the substantia propria (Self repairing zone)

2) Bowman's membrane :- It is a thin homogenous membrane, separates the epithelium from substantia propria, Once destroyed it cannot be regenerated. Thickness is 10 to 14 u.

3) Substantia propria - (Stroma)
The thickest of all layers, 9/10th of corneal thickness, may be regarded as forward continuation of sclera, stroma comprises of regularly, equidistantly arranged thin fibres of collagen, by this regularity of stromal components only the transparancy of cornea is maintained.

4) Descemets membrane :- 6 u in thickness, it is thin elastic membrane, separates stroma from endothelium. It is very resistant to infection and it can regenerate if destroyed.

5) **Corneal endothelium :-** It is a single layer of hexagonal cells, aimed to control the stromal hydration.

Blood supply :- Cornea proper is Avascular except 1-2 mm of its periphery (from circum corneal arterial plexus (derived from anterior ciliary arteries.)

Nutrition to cornea: (1) From circum corneal plexus
2) Diffusion from aqeous humour (3) from tears.

Nerve supply :- Corneal tissue is the most sensitive of all the body tissues.
1) Long cilliary nerves, the branches of Naso ciliary of Trigeminal nerve, gives 60 to 80 minute branches those spread from limbus to cornea, the fibres are non medullated for optical reason.

Sclera :- Sclera forms the posterior 5/6th part of fibrous wall of eye ball. It is pale white, strong, opaque and slightly elastic layer which maintain the contour (shape) of the eyeball
Its average thickness is 1mm. It is made up of bundles of collagenous fibres with connective tissue corpuscles, it is covered by tenon's capsule and episcleral tissue, 4 recti muscles are inserted into sclera infront of the equator and 2 obliqe muscles behind the equator of the eye ball.

The inner surface of sclera is separated from choroid by a potential space called **supra choroidea**. Sclera gives 2 openings one Anteriorly (to join with cornea) and another one posteriorly the **Lamina cribrosa,** for the exit of optic nerve at posterior opening 2/3 of slcera continued as dural sheet of optic nerve, 1/3 mixes with choroidal tissue, Sclera is perforated by many vessels (a) Long posterior cilliary arteries (b) short posterior ciliary arteries (c) Anterior ciliary arteries (d) Veinae verticose (6) Long and short ciliary nerves. Though sclera traversed by many blood vassels, has a little vascular supply, but episcleral tissue contains more blood supply.

c) Limbus :- It is a transition zone between cornea and sclera. It is about 1mm wide, epithelium is thick, upto 10 or more layers, stroma losts its regular arrangement here, The marginal vascular plexus derived from anterior ciliary vassels, channel of schlemm present in the Limbus. The medial boundary of Limbus is formed by scleral spur and trabecular mesh, through the pores of trabecular mesh only it communicates with anterior chamber, allowing the usual drainage of aqueous from anterior chamber to general circulation to maintain normal intra ocular pressure. (18 to 24 mm Hg)

2)VASCULAR LAYER (Uveal Tract)

It is second or middle layer of eye ball, highly vascular, supplies nutrition to the 3rd layer (Retina). It is termed as uveal tract. Formed of 3 parts (1) Iris, (2) Ciliary body, (3) Choroid.

Iris and cilliary body or together called as Anterior Uvea, The Choroid is called as posterior Uvea.Anatomically above 3 parts are continuous and so the disease of one part easily spreads to the another.

a) Iris :- It is a circular, pigmented diaphragm hanging in between cornea (Anteriorly) and lens (posteriorly) with central perforation (pupil). Iris divides anterior compartment of eye ball into two (a) Anterior chamber (the chamber betweeen iris and cornea) (b) Posterior chamber (the chamber between iris and Lens), its peripheral part is attached to the Anterio medial part of ciliary body.
It is made up of 4 layers from out to inwards.
1) Layer of endothelium (2) Iris stroma (3) Muscular layer (constrictor pupillae -dilator pupillae) (4) Layer of pigments
Anterior surface of Iris is uneven and shows many crypts and fissures.

Spinctor pupillae or constrictor pupillae muscle is made up of circular fibres, situated close to the pupillary margin, supplied by Oculomotor nerve responsible for the constriction of pupil. Dilator pupillae muscle consists radial fibres extending from cilliary body to pupillary margin supplied by the cervical sympathetic nerves which is responsible for the dilatation of pupil.

Pupil : It is the circular central perforation of the iris about 3 to 4mm in diameter, large in young and smaller in the aged, It regulates the amount of light admitted into the eye, it becomes small (Contracted) in day time or in bright illumination and becomes big (dilated) at nights and in dim illumination, with the Action of constrictor pupilae and dilator pupillae muscles only constriction and dilatation of pupil takes place.

Blood Supply :- Greater vascular ring of iris formed by posterior and anterior ciliary arteries, gives branches to ciliary body and iris, the branches of iris converge at pupillary margin and form small circle of iris.

Nerve Supply
1) oculomotor nerve
2) Naso ciliary branch of ophthalmic division of Trigeminal nerve
3) Sympathetic nerve.

b) Ciliary body :- It is the middle part of vascular coat, Triangular in cross section with its base directed forwards and medially, the Apex becomes continuous with the anterior part of choroid . From the middle of the base the Iris arises. The lateral part of the base forms a part of the angle of anterior chamber.

Outer aspect of triangle contain ciliary muscle with 3 types of muscle fibres (meridional, radial and circular) in the Anterior half of inner surface contain 60 to 70 longitudinal folds knowon as ciliary process - secretes aqueous humour. Inner surface of cilliary body is covered by 2 layers of cubical epithelium to which fibres of suspensory ligament of Lens is attached.

Blood supply :- Greater ring of iris
(Formed by Anterior and posterior ciliary arteries)

Nerve Supply :- Sensory - Trigeminal nerve branches.
Motor :- Oculomotor nerve.

c) Choroid :- Choroid forms the major portion of uveal tract posteriorly, lying in between sclera and retina, starting from posterior limit of ciliary body (at the level of ora serrata) to the opening of optic nerve. It consists of connective tissue with pigment contain chromatophores outer surface is separated from retina by an elastic "Bruch's membrane".

Choroid can be divided into 5 layers as follows:

1) Lamina supra Choroidea
(attached to sclera by loose connective tissue)

2) Layer of large vessels.

3) Layer of middle sized vessels.

4) Layer of choroidal capillaries.

5) Lamina vitrea or bruch's membrane.

Function : - To give nourishment to retina and vitrious.

Blood Supply :- Short posterior ciliary arteries.

Venous return :- 4 vortex veins.

Nerve Supply : :- Trigeminal nerve branches.



Different layers of Retina

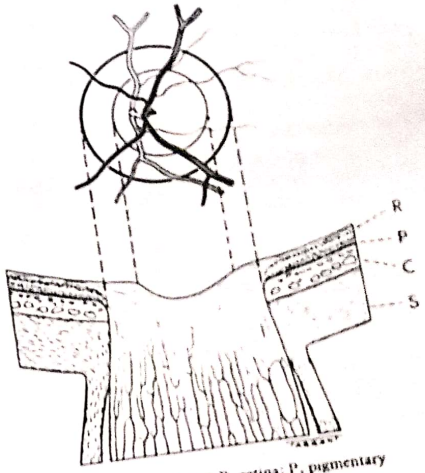

Physiological cup: R, retina; P, pigmentary epithelium; C, choroid; S, sclera

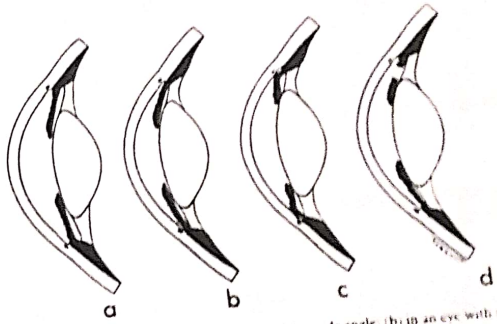

The anterior chamber and its angle (a) in a normal eye with a wide angle, (b) in an eye with a narrow angle, (c) physiological iris bombe with a semi-dilated pupil, (d) restoration of the patency of the angle after peripheral iridectomy

b) 3rd layer Nervous Coat (Retina)

The retina is a thin delicate membrane, contains a layer of nerve fibres, that continue as optic nerve. It is placed in between hyaloid membrance of vitreous (internally) and choroid (externally), It extends upto the Anterior end of choroid (ora serrata) in the living eye it is transparent and have faint purple-red colour, becomes opaque and white immediately after death. At the posterior pole of the retina presents a yellow spot, called macula lutea, 1-2 mm in diameter with central depression (Fovea centralis), this is the area of maximum visual discrimination, About 3mm innner side to the posterior pole of eye, pale round or oval area, the head of optic nerve (optic disc)present with central depression (physiological pit or cup) here the blood vessels of retina enter and leave the eye ball.

The thickness of retina is about 0.5 mm
Near optic disc 0.2 mm
at equator 0.1 mm

retinal arteries have no anastomosis hence in occlusion of central artery there is no compensatory collateral circulation and so blindness results.

Micro anatomy of retina :-
8 layer of nervous elements. 2 layers of supporting tissue (Fibres of muller)
Blood supply :- 1 to4 layers have no direct blood supply, derive nutrition by diffusion from chorio capillaries, remaining from central artery branches of ophthalmic artery.
Venous drainage :- 1 to 4 vortex veins, remaining central veins, cavernous sinus.

The layer of retina from out to inwards :-

1) Layer of pigment epithelium :-
Single layer of hexagonal cells, contains melanin pigment and resting on bruch membrane.
2) Layer of rods and cones - the end organs for visual sensation.
3) External limiting membrane
4) Outer nuclear layer :- consisting of arborizations of the axons of the rods and cones nuclei and dendrites of the bipolar cells.
5) Outer plexiform layer :- Consisting of arborizations of the axons of the rods and cones nuclei and dendrites of the bipolar cells.
6) Inner nuclear layer :- Bipolar cells which are rod bipolars connecting with rods, cone bipolars connecting with cones associated elements which are two types a) Horizontal cells b) amacrine cells.

They inter connect different cells with one another.

7) Inner plexiform layer :- consisting of arborization of the axons of bipolar cells with the dendrites of ganglion cells.
8) Layer of ganglion cells :- Consisting of large ganglion cells
9) Nerve fibres layer :- Consisting of axons of ganglion cells.

These fibres are non medullated and are continued as optic nerve fibres.

10) Internal limiting membrane
1 to 8 stops at optic disc
9 is continued as optic nerve

Rods - Cones

There are the organs for visual sensation, cones are 7 millions and rods are 75 to 170 millions. At fovea centralis cones are tightly packed, here cones density is about 150000/mm2 -out side the macula cones density is 5000/mm2 and gradually becomes negligible towards periphery. Rods are absent at fovea centralis, appears from 0.1 mm of fovea and having greatest density 160000/mm². from 5mm of fovea. Rodes are sensitive to low illumination responsible for night vision (scotopic vision,) cones are sensitive to bright illumination responsible for day light and colour light (Photophic vision.)

Visual Pathway :-

The long fibres originating from all ganglian cells of retina meet together and form as optic nerve and come out of the eye ball through Lamina cribrosa. The both optic nerves (left & Right) form optic chiasma, here the fibres from nasal half of each retina crosses to join the optic tract of opposite and the fibres from temporal half of retina proceeds to the same side . The two optic tracts from chiasma moves out wards backwards, wind round the cerebri to end in the lateral geniculate bodies.From which new fibres for the optic radiation originates, the optic radiations on either sides pass through the posterior portion of the internal capsule and end in the calcarine cortex surrounding the calcarine fissure in the occipital lobe, which is also known as visual cortex.

CAVITY OF EYE BALL

The cavity of eye ball is divided into two compartments by crystalline lens with its suspensory ligament - a small anterior and large posterior compartments. Anterior compartment further divided into two chambers by the Iris, anterior chamber and posterior chamber, it contains aqueous humour.

Posterior Compartment :- Contains transparent jellly like structure known as vitreous humour, which separated from retina by hyaloid membrane, gives support to the interior of eye and helps in the formation of retinal images properly, Avascular so no inflammatory changes occurs, only possibility of degenerative changes.

ANTERIOR CHAMBER

Boundaries

Anteriorly - Endothelial layer of cornea
Posteriorly - Cilliary body - Iris - Pupillary aperture

Normal Depth:- 2.5 mm (in central part)
It s angle and depth having importance in the maintanence of normal intra ocular pressure.

Posterior Chamber

Boundaries - Anteriorly Iris
Posteriorly - Lens supensary ligament
Laterally - Ciliary body.

Aqueous humour :- From ciliary process of ciliary body aqueous is diffused into posterior chamber.

Clear, watery alkaline fluid, density slight more than water,
volume in Anterior chamber is 0.25 cc
Volume in posterior chamber is 0.06 cc

Composition :- It consists mostly water and all the minute traces of the diffusible constituents of plasma, the protein content is negligible and sodium Ascorbic acids are in higher concentration

AQUEOUS CIRCULATION

Aqueous circulation is having important role in the maintanence of normal intra ocular pressure (Normal pressure 16 to 23 mm Hg)

It is secreted from the blood in the cilliary process of ciliary body. enters into posterio chamber, via pupil it enters into Anterior chamber, moves towards the angle of Anterior chamber, from here through the pores (Spaces of fontanna) of trabecular mesh enters into schlemm's canal of limbus. Then through the Aqueous Veins,episcleral veinous plexus, absorbs into general circulation.

LENS

Lens is a transparent, biconvex structure with rounded border (equator), the main function is to converge the light rays to form image on retina properly, anterior surface is less convex than posterior surface, it is kept in its position by suspensory ligaments or zonule which is extending form ciliary body, its position is posterior to iris and anterior to vitreous, it is made up of Lens fibres and enclosed in an elastic capsule.

Lens axis deviates from visual axis by about 4°, underneath the lens capsule there is a single layer of cubical epithelium from which the lens fibres are developed and arranged concentrically around the axis like the scales of an onion. Central part of lens which is hard is known as nucleus and peripheral part which is soft is known as cortex.

Axial diameter 3.5 to 4mm - equatorial diameter 8 to 10 mm
weight of lens approx 0.2 grams - Volume of Lens approx - 0.163 ml

Parts : (1) Capsule - (a) zonular lamellae or pericapsular layer to which suspensory ligament is attached (b) Capsule proper.
(2) Subcapsular epithelium - It is a single layer of epithelium from which the Lens fibres are developed and it is situated underneath the anterior capsule only.
(3) Lens (fibres) substance :- Lens fibres are developed from sub capsular epithelium and arranged concentrically arround the axis like the scales of an onion, centrally placed cells known as nucleus and peripherally placed cells known as cortex. Lens fibers while moving from equator to Anterior and posterior poles coverge at a point and form sutures, cortical sutures are multi radiated and nucleus sutures are tri radiated, Anteriorly Y shaped and posteriorly inverted Y shaped. Lens fibres doesn't exfoliate collected even from foetal life and are tightly burried at the nucleus.

Embryonic fibres — In the interior nucleus
Foetal fibres
Infantile fibres
Adult fibres
} Arranged from interior to Exterior gradully.

So only by age the lens nucleus becomes hard flat (due to tightly crushed lens fibres at nucleus) hypermetropic with increased density, so only lens appears as grey, it is a physiological process, ultimately causes lental sclerosis.

Chemical Composition

63% to 69% water 35 to 36% proteins crystallines albuminoid 1% lipoids, in organic ions, carbo hydrates, ascorbic acid, glutathione and amino acids.

NETRA ROGA SAMANYA NIDANAM

(Common aetiology of eye diseases)

Nidana means **"Roga karana"** (The cause of the disease)

Sushrutha, Vagbhata, Bhavamishra, Yogaratnakara, Dalhana, Saranga- dhara, etc. Acharyas given the list of roga karanas which are practically observed by them, they are as follows :-

1) Ushnabhitapthasya jala praveshath:-

Exposing, or drinking cool water immediately after exposing to heat, because of immediate opposite exposures the eye muscles affects and causes the eye diseases.

2) Doorekshanath :-

(Looking at the very distant objects regularly for a long time)

Eye can visualise the things upto some distance without any strain, by seeing the very distant objects for a long time, the accommodative capacity of eye will be distorted, leads to eye disorders

3) Swapna viparya yaashcha :- Abnormal sleeping habits.

Diwa swapna - Day Sleeping causes kapha vitiation

Nishi Jagara - Night prousal causes vata and pitta vitiation.

and produces Hyperamia, watering of eyes, oedema, eye strain and headache etc.

4) Prabaktha samrodhana :- (Continuous weeping), It causes excessive stimulation to Lacrimal gland, by that the gland secrets more fluid that washes away the nutrients and bacterio static activity of conjunctival sac so that conjuctival sac and Lacrimal apparatus looses the stamina against the diseases, finally it causes xerosis and the diseases of Lacrimal apparatus.

5) Koppa (Excessive anger) pitta vitiates and causes pitta vikaras in the eye

6) Shoka (grief) vata vitiates and causes vataja netra vikaras in the eye

7) Kleshta - stress - suffering - pain:- Physical & mental exhaustion, vitiates both sharirara and manasa doshas, leads to eye diseases.

8) Abhighaatha :- Minute irritative injuries or contusion injuries or perforating injuries causes a great loss to the eye, If proper care is not taken blindness follow immediatley.

9) Ati Maithunna - indulging more sexual intercourse it causes dhathu kshya and eye diseases.

10) Shuktha Aaranala, amla, Kulutta, masha

If taken excessively causes netra vikaras because the above things are sandhana davyas having the following bad qualities

Shuktha	Having the alcoholic properties which are quite
Aaranal	Opposite to ojas
Amla	

Kulutha :- Kashaya rasa, Katuvipaka; if taken for a long time vitiates and causes rakthaja pittaj disorders of eye

Masha :- Guru madhura snigda - if taken for a long time causes kaphaj disorders of the eye.

11) Adharaneeya vega dhaarana (Vegaavarodha) Suppressing natural urges

It produces udavartha vyadhi that causes eye strain and other vataja eye disorders.

12) Atisweda :- Excessive fomentation or sudation to the eye :-

(Swedana Karma is comttra indicated to the eyes, if necessary mrudu sweda is suggested with perfect care) it causes pittaj Rakthaj disorder of eye

13) Dhooma nisevanath :- the eye either exposing to smoke or by smoking the tobaco (Tobaco amblyopia causes visual disordes, partial or total blindness)

14) Chardhir vighatath - Suppressing the vomiting urge leads to udavartha vyadhi that causes eye strain and visual problems. Suppressing vomiting leads to Kusta eye lesions etc.

15) Vamanathi yogath :- Indulging excessive vamana therapy. (Vamana ati yoga) Produces complication like protrusion of eye ball (Akshnor vyavruthi) and Retinal or sub conjunctival haemorrhages etc.

16 Bhashpa grahath :- Suppressing the tears produces ashruja udavartha in which doshas obstructed in the ashru vaha srotas and causes eye disease.

17) Sukshma nireeksha nath : observing the minute things regularly causes Strain to the ciliary muscles and lens results in visual problems.

Additonal points by Bhavamishra :

18) **Rajo dhooma nisevanath** :- Exposing to dust smoke causes pricking injury or foreign body sensation in the eyes.

19) **Athi sheeghgra Yaanath :-** Quick walking - it causes discomfort and strain to the body and eyes.

20) **Ruthunancha viparyayena** :- Not following the health principles of Ruthucharya.
Taking hot things in ushna ruthu - pittavitiates
Taking cool things in sheetha ruthu - Kapha vitiates

21) **Shiro Abhitapa :-** Head exposing to the hot produces Rakthaja and pittaja disorders of eye.

Additional points by yogarathnakar

22) **Ati dravanna panam:-** taking more liquid diet -Causes hypo vitaminosis leads to eye disorders

23) **Atimadya panam** :- Excessive intake of alcohlic preparations causes ojo kshaya and visual disorders.

Additional points by Dalhana;

24) **Avaak shira shayanam :-** Sleeping by putting the head in the down ward position than body. (cervical, Brachial neuralgia)

25) **Ucchitha shira shayanam :-** sleeping by putting the head in the up ward position than body. (cervical, Brachial neuralgia)

26) **Jwara abhitapa :-** Due to high fever or sun stroke, head including eyes are afffected and causes the eye diseases.

Additional points from Hareetha samhitha.

27) Excessive intake of ushna, Kshara, katu rasa, food or drugs, causes eye diseases.

Additional points by Sarangadhara

28) **Bhaaswara vasthu veekshanam ;-** The eye exposing to bright things - causes, Timira and other eye diseases.

29) **Midhyaahara vihara causes eye diseases,**

Additional point by Vagbhata.:-

30) **Pada peedana:-** (Not wearing the chappals) foot massage with hot oils or hot water, causes eye diseases.

The Above causes can be grouped as follows :

a) Doshaja b) Aganthuja

a) 1) Shareera doshaja karana. 2) Manasa doshaja Karana.

1) Shareera dosaja karanas, Ex midhyaahara vihara, vegavarodha, swapna viparyaya - ruthu viparyaya, etc.
2) Manasa doshaja Karanas - kopa, shoka, klesha, etc.

b) Aganthuja karanas

1) Instrumental Penetrating injuries
Contusion injuries

2) Injury to eye by dust particles, Foeign bodies, bhaaswara vasthu veekshanam etc.

3) Injury to eye due to the factors those causes eye strain.
1) ushnabhitapthasya jala praveshaath (Sudden opposite exposures)
2) Doorekshanath (Seeing the very distant objects)
3) Bhashpa graha (Suppressing the tears)
4) Sukshma nireeekshana. (Seeing the minute very nearer objects)

Demonstration of netra Nidana according to Sushrutha's Classification (7 types of classification)

It can be implied to the netra nidana as follow :

1) Adibala pravruttha vyadhies (hereditory disorders)
2) Janmabala pravruttha vyadhies (Congenital disorders)
3) Doshabala pravruttha vyadhies (Bodily & mental disorders)
4) Kala bala pravruttha vyadhies (Seasonal a) Normal b) abnormal)
5) Swabhaavabala pravruttha vyadhies (Degenerative disorders)
6) Daiva bala pravruttha vyadhies (Traumatic injury due to exposure of Bright and spiritual things)
7) Sanghatha bala pravruttha vyadhies (Traumatic disorders)

1 to 5 - Doshaj
6 & 7 - Aaganthuja disorders.

Description :

1) Adi bala pravruttha vyadhies (Hereditory disorders)
The diseases which are carried to their generation due to beeja dosha (Sperm -ovum) are grouped under this classification, Ex. - Night blindness (Nakthandhya).
2) Janma bala pravruth vyadhies (Congenital disorders) arises due to (1) Malnutrition to pregnant lady (dauhrudaapachara Krutha)
Ex. Micro cornea or Megalo cornea or Kerato conus, congenital myopia or Hypermetropia Congenital cataract, ptosis, congenital dacryo cystitis, etc.
3) Dosha bala pravruttha vyadhies

Shareera - Amashaya gatha | Manasa - Rajo doshaja
Pakwashaya gatha | Tamo doshaja

The diseses which arises due to dosha vitiation can be grouped under this classification.

4) Kala bala pravrutha vyadhies

a) Vyapanna - Diseases arises due to Vikrutha ruthu
Ex. Abhjshyandha (abnormal seasonal changes)

b) Avyapanna - Diseases arises due to prakrutha ruthu
(Common seasonal changes).

5) Swabhava bala pravrutha vyadhies (Degenerative changes)

a) Kalaja - Normal changes by age.
ex:- Presbyopia - Senile Cataract, Arcus senilis

b) Akalaja - earlier changes due to some pathology.
Ex: cataract in adults (Diabetic cataract), Visual problems in children etc.

6) Daiva bala pravruttha vyadhies

Diseases arising due to observing the bright light or graha or Devata etc. (Divya Tejo moorthi drashana) Ex : cataract or blindness which arises due bright things exposure, can be grouped under this.

7) Sanghatha bala pravruttha vyadhies (Traumatic disorders)

Shastra krutha — Instrumental injuries
Vyala krutha — animated injuries

Injury of any origin causes eye diseases quickly - if proper care is not taken blindness may follow.

Modern - classification :

1) Prenatal :- - Hereditary (Adibala pravruttha)
- Congenital (janmabala pravruttha)

2) Post Natal :

a) Physical injuries
b) Chemical injuries
c) Mechanical injuries
d) Parasitic Injuries

] Doshabala & Sanghatha bala

e) Degenerative disorders (Swabhava bala Pravruttha vyadhies)
f) New growths, Cysts, Tumours, abscess, etc. Dosh bala pravruttha and Sanghatha bala pravruttha.

Samaanya poorva rupam of netra rogas :-

A) Samanya poorva rupa (common features of poorva rupa)
B) Visesha poorva rupa (Specific features for every disease).
Poorva rupam or Avyaktha rupam - partial manifestation of the diesease, if it is suppressed in this stage the diseases can be controlled easily

Samanya poorva rupa :

Prior to the manifestation of the disease, most of the diseases of eye having the following signs and symptoms.

1) Aavila - Dirty eye with discharges (Malayuktham)
2) Sa samrambha - Angry look with watering of eyes.
3) Kandu - Itching sensation
4) Upadeha - Sticking of eye lids due to organised discharges
5) Guru - Heavyness of lids (in kapha predominence) (chemosis of lids)
6) Uusha - Burning sensation (in pitta predominence)
7) Toda - Pricking pain (In vata predonimnce)
8) Raga - Hyperaemia (red eyes in Raktha predominence)
9) Shoola in varthma kosha pain in the eye lids
10) Shooka poornabham - Foreign body sensation.
11) Vihanya manam rupam - Visual diturbance
12) Kriya haani - Difficulty in opening closing the lids and improper visualisation.

By observing the above symptoms it can be understood that Dosha dooshya sammurchana has completed and the disease is going to arise, If ,proper medication is given inthis stage it is very easy to control the dosha vitiation or manifestation of disease

Samanya samprapthi of netra rogas :-

According to sushrutha :-The vitiated vatadi doshas propogates through the channels of sira - damani towards the utthamangam (Shiras-Head) and into the eyes and produces dreadful diseases in the eyes.

2) According to vagbhata

The vitiated vatadi doshas associated with pitta dosha, propogates through the Channels of sira - damani towards shiras and enter in the parts of the eye like varthma, sandhies, shukla mandala, krishna mandal, drustimandala to the all parts, and produces dreadful diseases in the eyes.

3) In traumatic lesion first disease occurs later doshas vitiates.

CLASSIFICATION OF EYE DISESES

1)	According to Sushrutha and Yogaratnakar	76 diseases
2)	According to Vagbhata and Darangdhar	94 diseases
3)	According to Charaka and Karala	96 diseaes
4)	According to Bhavamishra	78 diseases
5)	According to Satyakee	80 diseases

CLASSIFICATION OF EYE DISEASES ACCORDING TO SUSHRUTA AND VAGBHATA

	Sushrutha	Vagbhata
	76	94
1) Sandhi gatha	9	9
2) Vartma gatha	21	24
3) shukla gatha	11	13
4) Krishna gatha	4	5
5) Sarvaja	17	16
6) Drustigatha	12	27
7) Bahya	2	
Total	76	94

NETRA ROGA VARGEEKARANA

(Classifications of eye diseases)

1) According to doshas :-

a) Vatika netra rogas 10 (b) Paithika netrarogas 10

c) Kaphaj " 13 (d) Rakthaja " 16

e) Sannipathaj " 25 (f) Bahya " 2

(a) (b) (c) (d) (e) (f)

10 + 10 + 13+ 16+ 25 + 2 = 76

a) Vatika netra rogas -10

Sadhya - (curable)	5	1) Vatika Abhishyandha, 2) Vatika Adhimanda, 3) Shushkakshipaka, 4) Anyatho Vata 5) Anila Paryaya, (1 to 5 sarvagatha rogas)
Yapya -	1	Vatika kacha, (1- Drustigatha roga)
Asadhya - (incurable)	4	1) Gambheerika (Drustigatha), 2) Hathadhimanda (Sarvagat), 3) Nimesha (varthma gatha), 4) Vata hatha varthma (Varthma roga).
Total	**10**	

b) Paithika netra rocgas - 10

Sadhya (curable)	6	1) Paithika abhisyanda 2) paithika adhimanda, 3) Amladyushitha (1 to 3 sarvagatha), 4) shukthika (Shukla gatha), 5) Dhoomadarshi, 6) Pitta vidhagdha drusti (5 and 6 Drusti gatha).
Yapya	2	1) Parimlayi kacha, 2)Neela kacha(1 to 2-Drustigatha roagas)
Asadhya (incurable)	2	1) Paithika jala srava (1-sandhigatha), 2) Hraswajaadya (1-sarvagatha)
Total	**10**	

c) Kaphaj netra rogas -13

Sadhya	11	1) Shleshmaja upanaha, 2) Krimi grandhi (1 to 2-sandhi gatha), 3) Klinnavarthma, 4) Lagana, 5) Phothaki (3 to 5 varthmagatha), 6) Shuklarma, 7) Pishtaka, 8) Balasa Graditha (6 to 8 shukla gata), 9) Kaphaj abhishyanda, 10) Kaphaj adhimantha.(9 & 10 sarvagata) 11) Shleshma vidagdha drusti (1-drustigatha),
Yapya	1	1) Kaphaj kacha - (1- Drustigatha)
Asadhya	1	1) Kaphaj netra srava (1 Sandhigatha)
Total	**13**	

D) Rakthaja netra roga -16, They are as follows

Sadhya (Curable)	11	1) Parvani (1 sandhi gatha roga), 2) Klista varthma, 3) Anjana Namika (2 and 3 varthma gatha), 4) Sirajala, 5) Arjuna, 6) Shonitarma(4-5-6 shukla gatha), 7) Avrana shuka (1krishna gatha), 8) Rakthaja Abhishyandha, 9) Rakthaja, Addhimanda, 10) Sirothpatha, 11) sira harsha (8 to 11 sarva gatha),
Yapya	1	1) Rakthaja Kacha (1Drustigatha)
Asadhya Incurable	4	1) Rakthaj srava (1 sandhigatha), 2) Shonitharsha (1- Varthma gatha), 3) Ajakajatha 4) Savrana shukla (3 and 4 krishna gatha),
Total	**16**	

e) Sannipathaja netra rogas - 25, They are as follows

Sadhya - (Curable)	19		1) Uthsangini, 2) Kumbheeka, 3) varthma sharkara, 4) Arshovarthma, 5) Shushkarsha , 6) Arbuda, 7) Aklinna varthma, 8) Varthma avabandha, 9) Bahala varthma, 10) shyava varthma, 11) Bisa varthma, 12) varthma Kardama (1to12 varthmaja rogas)13) Sashopha Akshipaka 14) Ashopa Akshi paka (13 and14 Sarvaja), 15) Puyalasa (1sandhija), 16) Prastariarma, 17) Adhimamsaja arma, 18) Snayuarma, 19) sira Pitika (16 to 19 shukla gatha),
Yopya -	2	=	1) Pakshma kopa (Sandhigatha) 2) Sarvaja Kacha (Drustigatha-1)
Asadhya - (incurable)	4	=	1) Puyasrava 2) Alaji (2 sandhigatha) 3) Nakulandhya (1 Drusti Gatha) 4) Akshi Pakathyaya I1 Krishna gatha)
Total	**25**		

7) Bahyaja netra rogas- 2, They are as follow:-

Asadhya (incurable)	1) Sanimitthaj Linganasha 2) Animitthaj Linganasha

II. Classification of eye diseases according to shareera (Vitiated parts of eye ball)

a) Sandhigatha	-	9
b) varthma gath	-	21
c) Shuklagatha	-	11
d) Krishna gatha	-	4
e) Drustigatha	-	12
f) Sarvagatha	-	17
g) Bahya		2
Total		**76**

a) Sandhigatha rogas - 9 they are -
1) Puyalasa (2) upanaha, (3.4.5.6.) 4 types of netra srava (7) Parvani 8) Alaji (9) Krimi grandhi

b) Diseases of Varthma Mandal -21 :- They are

1) Uthsangini (2) Kumbheeka (3) Phothaki (4) Varthma sarkara (5) Arsho varthma (6) shushkarsha (7) Anjana namika (8) Bahala varthma (9) Varthmaavabhandha (10) Klishta varthma (11) Varthma Kardama (12) Shyava varthma (13) Praklinna varthma (14) Aklinna Varthma (15) Vatahatha varthma (16) Arbuda (17) Nimesha (18) Shonitharsha (18) Lagana (20) Bisavarthma (21) Pakshma Kopa.

c) Diseases of Shukla Mandala -11 They are

1)Prasthari arma (2) Shuklarma (3) Kshathaja Arma (Shonitharma) 4) Adhimamsarma (5) snayu arma (6) shukthika (7) Arjuna (8) Pistaka (9) Sirajala (10) Sira Pidaka (11) Balasa graditha.

d) Diseases of Krishna Mandal 4 , they are
1) Savrana shukla 2) Avrana shukla 3) Ajaka jatha 4) Akshi pakathyaya

e) Diseases of Drusti mandal -12, They are

1) Vataja Linganasha
2) Pittaja Linganasha
3) Kaphaja Linganasha
4) Rakthaja Linganasha
5) Sannipathaj Linganasha
6) Parimlayi
7) Pitta vidhagdha drusti
8) Kapha vidhagdha drusti
9) Hraswajadya
10) Nakulandhya
11) Dhcomadarshi
12) Gambheerika

f) Sarvaja netra rogas - 17, They are

1) Vataja Abhisyanda
2) Pittaja Abhisyanda
3) Kaphaja Abhishyanda
4) Rakthaja Abhishyanda
5) vatika adhimanda
6) Pittaja Adhimanda
7) Kaphaja Adhimanda
8) Rakthaja Adhimanda
9) Sashopha Akshi Paka
10) Ashopha Akshi paka
11) Shushkakshi paka
12 Hathaadhimanda
13 Anila paryaya
14) Anyatho vatha
15) Siroth path
16) Siraharsha
17) Amla dyushitha

g) Bahya - 2

1) Sanimittaj Linganasha
2) Animittaja Linganasha

III) Classicfication of eye disease according to sadhya- Asadhyatha.

1) Sadhya	-	52	Diseases
2) Yapya	-	7	"
3) Asadhya	-	17	"
	Total	**76**	"

a) Sadhya - 52 : Vataj 5, Pittaj 6, Kaphaj 11, Rakthaj 11, Sarvaja 19,
b) Yappya 7 : vataj 1, Pittaj 2, Kaphaj 1, Rakthaja 1, Sarvaja 2,
c) Asadhya 17 = Vataj 4, Pittaja 2, kaphaj 1, Rakthaj 4, sarvaja 6.

IV) CLASSIFICATION OF EYE DISEASES ACCORDING TO THE TREATMENT PRINCIPLE (KARMAANUSARA)

a) Chedhya vyadhies - 11, They are

1) Prasthari arma
2) Shuklarama
3) Raktharma
4) Adimamsarma
5) Snayuarma
6) Sirajala
7) Sira Pitika
8) Arsho Varthma
9) Shushkarsha
10) Arbuda
11) parvani.

b) Bhedhya Vyadhies - 5, they are

1) Anjana namika
2) Langana
3) Bisa varthma
4) Krimi grandhi
5) Shleshmopanaha

C) Lekhya vyadhies -9, They are

1) Uthsangini 2) Kumbheeka 3) phothaki 4) Varthma sharkara 5) Bahala varthma 6) Varthmaava bandha 7) Shyava varthma 8) Varthma Kardama 9) Klista Varthma

d) Vydhan Sadya vyadhies -15 , They are

1) Sirothpatha 2) Sira harsha 3) Sashopha Akshipaka 4) Ashopha akshipak (5) (6) (7) (8) Abhishyanda 4 types (9) (10) (11) (12) Adhimanda 4 types (13) anyatha vatho 14) Anila Paryaya (15) puyalasa

e) Ashastra krutha vyadhies - 12, They are

1) Shushkakshi paaka 2) kapha vidhadga drusti
3) Pitta vidhagdha drusti 4) Amladyushitha 5) Aavrana shukla 6) Shukthika 7) Arjuna 8) Pistak 9) Praklinna Varthma 10) Aklinna varthma 11) Balasa Graditha 12) Dhuma darshi ± 2 Bahya rogas.

f) Asadhya vyadhies -15 , They are

1) Hathadimanda 2) Nimesh 3) Gambheerika 4) Vatahath Varthma 5) Hraswajadya 6) Pitta jala srava 7) Kaphaja srava 8) Rakthaja srava 9) Ajakajatha 10) Shonitharsha 11) Savrana shukram 12) Puyasrava 13) Nakulandhy 14) Akshi Pakatyaya 15) Alaji + 2 bahyarogas.

g) Yapya rogas -7

1) Vatika kacha
2) Pittika Kacha
3) Kaphaja Kacha
4) Rakthaja kacha
5) Tridoshaja kacha
6) parimlayi kacha
7) pakshma kopa.

DISEASES OF NETRA SANDHIES (SANDHIGATHA ROGA)

9 diseases are explained, they are

1) Puyalasa - Acute Dacryo cystitis
2) Sleshmopanah - Lacrymal cyst or Iris cyst
(3) (4) (5) (6) 4 types of netra srava - Epiphora or chronic dacryocystitis
7) Parvani - Phlyctenular conjunctivitis
8) Alaji - Advanced stage of phlyctenular conjunctivitis
9) Krimi grandhi - Blepharitis

Note : 1) Among the 9 diseases, 5 diseases (4 types of netra srava and alaji) are asadya
2) 4 diseases (puyalasa - upanaha, parvani, krimigranthi) are sadya rogas

1) PUYALASA (ACUTE DACRYOCYSTITIS)

It is sannipataja vyadana sadya vyadhi, affected sandhi is kaneenika sandhi (inner canthus)

Clinical features :-

1) A suppurative cyst (pakwa shoha - sushrutha; vrana shopha - vagbhat) develops at kaneenika sandi, it is spreading type of cyst.
2) The cyst discharges foul sticky and purulent secretion.
3) Severe pricking pain, angry look, restlessness, etc. are present

Note : By the above acute inflammatory features, it can be corelated to acute dacryo cystitis

Treatment :

1) Shareera shodhana
2) It is vyadana sadya vyadhi (Raktha mokshana)
3) upanaha sweda at the lesion 4) Vrana shopha chikitsa
5) Chakshushya lepas 6) Anjana
   a) Kaseesa saindhava lavana, Aardraka + honey
   b) Above drugs + fine powders of Loha bhasma and tamra bhasma

According to modern

a) Incision and drainage of lacrimal abscess
b) Excision of lacrimal sac (Dacryo cystectomy)
c) Dacryo cysto rhinostomy

2) UPANAHA
(Lacrimal cyst or Iris cyst)

It is kaphaja, Bhedana sadhya vyadhi The affected sandhi is Drusti sandhi (Vagbhata has not mentioned the name of the affected sandhi)

Description:- of Sushruth -
A painless, non suppurative, bigger cyst originates in the drusti sandhi and have only itching sensation at the lesion.

Description of vagbhata :-
A painless, non suppurative, bigger, deep rooted, soft sticky, same coloured cyst develops and contain itching sensation, is explained as upanaha.

Note. : Exact corelation is not possible, drusti identity itself not clear so confirmation of drusti sandhi is also difficult. But most of the authors explained it as lacrimal cyst or Iris cyst .

Chikitsa It is bhedhana sadhya vyadhi :- (but according to modern excision is the treatment principle.)

A) Sushrutha

1) Bhedhana and then prathisarana with pippali, madhu and Saindhava lavana.
2) In bigger and painless upanaha " Bhedhana - Lekhana - Pratisarana"
3) In rakthanu bandhi upanaha Pracchana and Prathisarana has to do.

B) Vagbhata :-1) Sweda with Hot water
2) Bhedana with vreehi mukha shastra
3) Lekhana with mandalagra shastra
4) Pratisarana with pippali, madhu, Saindhava lavanam
5) Cleaning with hot water
6) Applicationof ghee + honey and bandaging.
7) After 5 days, bandage should open and Aschyotana has to do with the decoction of patra parta, and Aamalaki

C) Yogaratnaker :-

1) Chedana with mandalagra shastra (Four sided excision).
2) Pratisarana with pippali saindhava lavana and madhu

सन्धिगत रोग

पूयालसः सोपनाहः स्रावाः पर्वणिकालजी।
कृमिग्रन्थिश्च विज्ञेया रोगाः सन्धिगता नव ॥

1. पूयालस

पक्वः शोफः सन्धिजः संस्रवेद् यः
सान्द्रं पूयं पूति पूयालस सः

सु. उ.2 अ

पूयालसो व्रणः सुक्ष्मः शोफसंरम्भपुर्वकः
कनीनसन्धावाध्मायी पूयास्रावी सवेदनः ॥

अ. हृ. उ. 10 अ

2. उपनाह

ग्रन्थिनल्पा दृष्टिसन्धावपाकः
कण्डूप्रायो नीरजस्तूपनाहः ॥

सु. उ. 2 अ

कफेन शोफस्तीक्ष्णाग्रः क्षारबुद्बुदकोपमः ।
पृथुमूलः स्निग्धः सवर्णो मृदुपिच्छिलः ॥
महानपाकः कण्डूमानुपनाहः सनीरुजः ।

अ. हृ. उ. 10. अ

3 से 6) नेत्रस्राव सम्प्राप्ति और लक्षण

गत्वा सन्धीनश्रुमार्गेण दोषाः कुर्युः स्रावन् रुग्विहीनान् कनीनात्।
तान् वैस्रांवान् नेत्रनाडीमथैके तस्या लिङ्गं कीर्तयिष्ये चतुर्धा॥
पाकः सन्धौ संस्रवेद् यश्च पूयं पूयास्रावो नीरुजः स प्रदिष्टः॥
रक्तास्रावः शोणितोत्थः सरक्तमुष्णं नाल्पं संस्रवेन्नातिसान्द्रम् ।
पीताभासं नीलमुष्णं जलाभं पित्तास्रावः संस्रवत् सन्धिमध्यात् ॥

सु. उ. 2 अ.

"अश्रुस्रावः सिरा गत्वा नेत्रसन्धिषु तिष्ठति ।
ततः कनीनकं गत्वा चाश्रु कृत्वा कनीनके ॥
ततः स्रवत्यथास्रावं यथादोषमवेदनम्"-

विदेह

वाग्भट

वायुः कृद्धः सिराः प्राप्य जलाभं जलवाहिनीः ।
अश्रु स्रावयते वर्त्मशुक्लसन्धेः कनीनकात् ॥
तेन नेत्रं सरुग्रागशोफं स्यात् स जलास्रवः ॥

अ. हृ. उ. 10. अ

कफस्राव

कफात् कफास्रवे श्वेतं पिच्छिलं बहलं स्रवेत

अ. हृ. उ. 10. अ

रक्तस्राव

रक्ताद् रक्तास्रवे ताम्रं बहूष्णं चाश्रुसंस्रवेत् ।

पूयस्राव

पूयास्रवे मलाः सास्रा वर्त्मसन्धेः कनीनकात् ।
स्रावयन्ति मुहुः पूयं सास्रं त्वङ्मांसपाकतः ॥

अ. हृ. उ. 10. अ

7. पर्वणी

ताम्रा तन्वी दाहशूलोपपन्ना रक्ताज्ज्ञेया पर्वणी वृत्तशोफा ।

वर्त्मसन्ध्याश्रया शुक्ले पिटिका दाहशूलिनी।
ताम्रा मुद्गोपमा भिन्ना रक्तं स्रवति पर्वणी ॥

अ. हृ. उ. 10. अ

8. अलजी

जाता सन्धौ कृष्णशुक्ले अलजी स्यात् तस्मिन्नेव ख्यापिता पर्वलिङ्गं :

सु. उ. 2 अ.

कनीनस्यान्तरलजी शोफोरुक्तोददाहवान् ।

अ. हृ. उ. 10. अ

9. कृमिग्रन्थि

कृमिग्रन्थिर्वर्त्मनः पक्ष्मणश्च कण्डू कुर्युः क्रिमयः सन्धिजाताः ।
नानारूपा वर्त्मशुक्लस्य सन्धौ चरन्तोंतर्नयनं दूषयन्ति ॥

सु. उ. 2 अ.

अपांगे वा कनीने वा कण्डूपक्ष्मपोटवान् ॥
पूयास्रावी कृमिग्रन्थिर्ग्रन्थिः कृमियुतोर्तिमान् ॥

4 TYPES OF NETRA SRAVA

Chronic dacryo-cystitis - Epiphora - Lacrimation

The vitiated doshas by vitiating Ashruvaha srotas causes painless Netra srava through Kaneenika sandhi. It is also Known as Netra nadi

Netra sravas are 4 types.

1) Kapha or shleshma srava 2) Pitta srava 3) Raktha srava
4) Pooya srava or sannipataja srava. (No vataja srava)

Note : - Vagbhata in Astanga sangrah has mentioned Jala srava by the vitiation of vata so he explained jala srava instead of pittaja srava.

1) Kapha srava :- Painless, whitish, sticky and solid eye discharge
2) Raktha srava :- Semi solid, bulk, hot and blood stained eye discharge
3) Pooya srava (Tridoshaja) :- Pus discharge comes due to suppuration of twak Mamsa and Raktha
4) Pitta srava :- a) Yellowish or bluish, Hot, watery eye discharge (Vagbhata mentioned jala srava instead of pitta srava)

(b) Jala srava :- watery discharge due to vitiation of vata in varthma shukla sandhi, and kaneenika sandhi associated with pain, redness and oedema .

Note :- Netra sravas can be compared to chronic dacryocystitis, epiphora etc

Treatment :- 4 types are Asadhyam, but can be tried like the following 1) Grahi Shodhana rasayan yogas 2) Sira vyada 3) Prakshalan with (a) In kaphaja Srava, Madhu + triphala kashaya (b) Pitta and Rakthaja srava, Ghritha + Triphala Keshaya 4) Anjan :-Triphala varthi anjana 2) Babbula patra concentrated decoction

7) PARVANI : PHLYCTENULAR CONJUNCTIVITIS (P. KERATITIS)

It is Rakthaja, chedana sadhya vyadhi, The affected sandhi is shukla krishna sandhi. (Vagbhata - varthma shukla sandhi)

Description :- Sushrutha

A small, nodular, (Vrutha shopa), copper coloured (red colour) nodule or Shopha Arises in shukla Krishna sandhi by the vitiation of raktha dosha, it associate with pain and burning sensation.

Vagbhata :- A small, round, copper coloured pitica (follicle or nodule) resembling the mudga, originates in varthma shukla sandhi - associated with pain and burning sensation - if the nodule (pitica) is excised it bleeds.

Chikitsa :- 1) Swedana 2) Chedhana like arma and 3) Residue has to scrape by Lakhana or pratisarana with saindhava lavana + madhu etc drugs.

8) ALAJI

Advanced condition of Phlyctenular Conjunctivitis (P. Keratitis)

It is the advanced stage of parvani in which all the symptoms appear. More severely than parvani, affected sandhi is krishna shukla sandhi. According to sushrutha and "Kaneenika sandhi" according to vagbhata, it is a deep rooted infection with more pain, and burning and said to incurable disease

Comparision

Parvani	Alaji
1) Smaller nodule	Bigger nodule
2) Superficial lesion	Deep rooted lesion
3) Raktha doshaj	Sanni pathaja (Tridoshas
4) Vedana + (mild)	Vedana + + + (Severe)
5) Daha + (mild)	daha +++ (Sever)
6) Sadhya Vyadhi (curable)	Asadhya vyadhi (incurable)
7) Simple lesion	Complicated lesion.

Phlyctenular Conjunctivitis (Parvani alaji)

It is a type of allergic conjunctivitis in which one or more small nodules develops on limbal conjunctiva

Predisposing factors - Pathology :-

1) Under nourished children with enlarged lymph glands of neck
2) Un hygienic surroundings
3) Endogenous toxins like Tuberculois, infected tonsil adenoids may cause the disease.
4) Section of phlycten show triangular area of infiltration, the apex of the triangle being towards the deeper layers

Symptoms :- Discomfort irritation lacrimation of the eye, conjunctival discharge and photophobia

Signs :- Small greyish nodule appear near the limbus with peripheral hyperaemia

Treatment :- 1) Cause should be treated. (T. B, Tonsils, Adenoids etc.)
2) Precautions of corneal ulceration
3) Treatment principles of conjunctivitis should follow.

KRIMIGRANDHI (BLEPHARITIS)

Yogaratnakar called it as Jantha grandi

It is kaphaja Bhedan Sadhya vyadhi affected sandhi is "Pakshma varthma" "sandhi" (eye lids margins) but according to vagbhata affected sandhi is "Kaneenika and Apanaga Sandhi" (inner and outer canthus).

Description :- Different types of Micro organisms, parasites, maggots etc, by vitiating pakshma varthma sandhi (kaneenika - apanga sandhi by vagbhata) Produces smaller cysts, on the eye lid margin the infection(Krimi) spreads, into the varthma shukla sandhi and interior of eye. The associated symptoms are 1) Irritation 2) discomfort. 3) itching sensation 4) Burning sensation 5) Falling of eye lashes 6) Purulent secretion from the lesion (eye lid margin)

Treatment (chikitsa):- a)Swedan 2) Bhedan 3) Prathisaran with Saindhava lavan + madu 4) Anjan with the varthi prepared with triphala, tuttha, kasesa and saindhava lavana.

Note :- It is corelated to Blepharits (Inflammation of lid margin), it need only anti inflammatory treatment but not incision and drainage (Bhedan) like above if pustules are formed, those should be drained.

WATERING OF EYE (NETRA SRAVAS) (EPIPHORA - LACRIMATION)

a) Epiphora : -Means watering of eyes due to obstruction to out flow of tears through lacrimal apparatus into inferior meatus of nose

b) Lacrimation means watering of eyes to excessive secretion of tears.

Causes of epiphora

1) Stenosis of the punctum, particularly the lower punctum either Congenitally or Acquired 2) Evertion of the lower punctum due to laxity of orbicularis occuli muscle as in old age, facial paralysis and ectropion. 3) Obstruction in Lacrimal canaliculi due to calculus or infection by Fungus etc. 4) obstruction in the sac due to tumour of the sac or following removal of the sac.5) Obstruction in the naso- Lacrimal duct due to chronic dacryo cystitis, nasal polyp, maxillary antrum tumour which is pressing on the duct.

Causes

1) Reflex causes :- (a) Due to sensory stimulation of the structures of the eye ball.

eg :- corneal foreign body, corneal ulcer, Keratitis, exposure to dust, smoke or irritant gasses.

(b) Due to stimulation of optic nerve, eg : Exposure to " bright light ." etc

(c) Due to stimulation of the sensory nerves of the eye muscles.
eg :- Eye strain.

(d) Due to stimulation of the nasal mucosa. eg: Nasal catarrh.

2) Action of parasympatho mimetic drugs eg:- Pilocarpine and physostigmin.

3) Diseases of Lacrimal gland

4) Emotional & Psychical effects.

Dacryocystitis (Puyalasa or puya srava)

It is the inflammatory condition of the Lacrimal sac

Dacryo Cystitis :-
- 1) Congenital (in the new born)
- 2) Primary { Chronic / Acute
- 3) Secondary { in Adults / in Infants.

I) Congenital dacryocystitis :-

This condition is due to failure in canalization of Naso Lacrimal duct, the lumen being blocked by epithelial debris

Signs :- (1) Epiphora (Watering of eye)

2) Muco purulent discharge through punctum by pressing over the sac area.

3) Slight distention of Lacrimal sac

4) The discharge is sterile at first later becomes infected

Symptoms :-Discomfort, watering , foul sticky discharge at inner canthus

Treatment :- 1) Sharp pressure over the sac area, 5 to 6 times a day to evacuate the pus and has to put antibiotic drops, 2) By gentle pressure over sac area may force the sac contents down, thus the patency of Naso Lacrimal duct is achieved.

3) Probing of Naso Lacrimal duct has to do, if delayed causes cicatrical obliteration of duct

II) Chronic primary dacryocystitis

Predisposing factor :- Stricture of Naso Lacrimal duct due to narrowing of bony canal assocaited with inflammed nasal mucosa, Hypertrophied inferior turbinate, deviation of Nasal septum and by the pressure of the Nasal polyp etc.

Exciting factor :- Infection of stagnated sac contents by the pneumo coccus, streptococcus and staphylo coccus.

Pathology :- Because of stagnation of sac contents followed by the infection, the sac epithelium thickens and becomes atonic, the sac contents are at first watery, later on mucoid, afterwards become muco purulent.

Symptoms :- Epiphora and discomfort at inner canthus.

Sign :- Can be discribed in 3 stages

1) **Catarrhal State ;-** Watering of eye, conjunctival hyperaemia at affected inner canthus, little regurgitation of fluids through punctum by pressing over the sac area, on syrenging fluid regurgitates with flakes of mucus through punctum, no local swelling on the sac area is found.

2) mucocele stage :- Watering of eyes, conjunctival hyperaemia Swelling of sac area with no tenderness, mucoid material comes through punctum when pressed over the sac area and some times both lacrimal canaliculi may be blocked and sac contents are retained (No regurgitation through punctum) Known as encysted mucocele.

3) Pyocele or suppurative stage :- epiphora, increased conjunctival hyperaemia, mucopurulent discharge comes through punctum when pressed over the sac area.

Complications :- Actue dacryocystitis, corneal ulcer, chronic conjunctivitis

Treatment : - 1)Probing the Naso lacrimal duct and syringing the sac with antibitic solution like pencillin 50000 units /cc of distilled water, if the disease is not controlled, surgical correction has to do by following method.
1) Dacryocystectomy (Sac is removed, life long epiphora remained).
2) Dacryo cystorhinostomy (medial wall of the sac is anastomosed with the mucous membrane of the middle meatus of nose)

ACUTE PRIMARY DACRYOCYSTITIS

It is an acute suppurative inflammation of Lacrimal sac, commonly observed as a complication of chronic dacryocystitis (some times occur spontaneously)

Causative agents :- Strepto coccus haemolyticus, pneumo cocus and staphylo coccus aureus.
Patholoy :- The sac get full with frank pus, infection also spreads to periphery and causing pericystitis, finally lacrimal abscess forms, that bursts on the skin and cause Lacrimal fistuia, as soon as pus drained out the inflammation subsides.
Symptoms :- Severe pain, hot sensation over the sac area, fever and watering of eye.

Signs :- 1) Marked swelling, tenderness, hot and redness over the sac area (2) oedema of eyelids (3) No regurgitation of sac contents through punctum (4) chemosis of conjunctiva (5) Enlargement of sub maxillary lymphglands (6) Formation of Lacrimal abscess, that may burst and cause lacrimal fistula (7) Patient feels comfort after pus discharge. 8) If the condition is not treated it recurs after some time with complications.

Complications :
1) Osteomyelitis of Lacrimal bone
2) Lacrimal fistula may open into nose
3) Orbital cellulitis (4) Facial cellulitis
5) Cavernous sinus thrombosis

Treatment

a) Before abscess Formation
1) Hot compress over the sac area
2) Systemic and Local Broad spectrum antibioics.
3) Analgesic 4) Symptomatic treatment

b) When Abscess formed
1) Vertical incision over sac area to drain the pus 2) Dacryo-cystectomy

c)After fistula formation
1) Excision of Fistulous passage
2) Dacryo cystectomy or dacryo cystorhinostomy

Secondary Dacryocystitis
In infants :- due to tuberculosis or syphilitic affections of surrounding bones.

In adults :-
a) Trachoma
b) Tuberculous or Syphilitic affections
c) Leprosy.

Treatment :- Causative diseases should be treated, local and symptomatic treatment should give.

BLEPHARITIS (KRIMI GRANTHI)

It is the Inflammatory condition of the eye lid margins (Sub Acute or chronic inflammation)

Predisposing factors :-
1) External irritants - Exposure to dust, smoke and cosmetics
2) Eye strain due to refractive error.
3) Un hygienic conditions.
4) nature of the skin. (Seborrhoea - Allergic factors (eczema)
5) Excessive - carbhoydrates in take.

6) Septic focus - From peripheral inflammatory conditions like chronic dacryo-cystitis, chronic conjunctivitis.

7) Parasitic infection:- eye lashes are covered with black nits of the pediculis pubis and the lid margin becomes red and irritable

8) Exciting causes are infection with coagulase positive staphylo coccus.

TYPES

A) Squamous Blepharitis (B) Ulcerative Blepharitis.

Squamous Blepharitis	Ulcerative Blepharitis
1) It is not essentially infective condition, but caused by metabolic causes, un hygienic factors eye strain and seborrhoea of the scalp	1) It is an infective condition caused by coagulase positive Staphylo coccus - in which Suppurative inflammation of the Ciliary follicle with glands of zeis and moll is observed.
2) Scales formation (like dandruff) on the lid margin.	2) Yellowish crusts deposited ulcers with pus points seen.
3) on removing the scales hyperaemia appears, no Ulceration.	3) on removing the crust small ulcers with pus points are seeen.
4) Falling of eye lashes seen - but quickly replaced without distortion	4) Falling of eye lashes seen does not replaced, if replaced, become misdirected.

Complications :-

1) Madarosis falling of eye lashes or scanty eye lashes
2) Trichiasis - Misdirection of eye lashes (hardening of eye lashes)
3) Tylosis - Hypertrophy of lid margin.
4) Ectropion - Evertion of lid margin.

Treatment :- A) Local1) Removal of scales or crusts, application of 3% sodabicarb, lotion (2) Local & systemic antibiotics (3) after healing of ulcer hydro cortisone 1% ointment has to use as Antiallergic (4) Treatment of the complications.

B) General :- 1) Improvement of general health, giving of vitaminous food, removal of septic focus and correction of refrective errors.

SANDHI GATHA ROGAS

Total diseaes == 9
Curable == 4
Incurable == 5

S.No.	name of the disease	Treatment
1)	puyalasa	Vyadana sadya
2)	Sleshmopanaha	Bhedana sadya
3)	Parvani	chedana sadya
4)	Krimi grandhi	Bhedana sadya
5)	4 types of Netra sravas, Alagi	Asadya (in curable)
6)		
7)		
8)		
9)		

DISEASES OF NETRA SANDHI

Sl. No.	Name of the disease Modern name	Vitiated dosha Affected sandhi	Clinical feature	Treatment Principles
1)	Puyalasa (Acute dacryocystitis)	Tridoshas Kaneenika sandhi	Foul sticky pus discharge From a cyst ot Kaneenika	Vyadan Sadya
2)	Upanaha or sleshmopanaha or Iris cyst	Kaphaj Drustic sandhi	A painless bigger non Suppurative cyst with itching sensation	Bhedan Sadya Vyadhi
3)	Kaphaj netra Srava	kaphaj Kameenika Sandhi	Painless whitish sticky Solid eye discharge	Asadya
4)	Raktaj Netra Srava	Raktaj Kaneenika	Semi solid, bulk, hot Asadya Blood stained eye discharge	
5)	Puya srava	Tridosha Kaneenika	Foul sticky pus discharge from the eyes	Asadya
6)	a) Pitta srava (Sushrutha) b) Jala srava (Vagbhata) (4 types of sravas can be corelated to epiphora ,	Pitta kaneenika Vataj Kaneenika	Yellowish or bluish, hot Watery eye discharge. Watery eye discharge chronic dacryocystitis	Asadya Asadya
7)	Parvani (Phlyctenular conjunctivitis	Raktaja a) Shukla krishna sandhi (sushruth) b) Varthma shukla sandhi (Vagbhat)	A small red noduler growth with pain and burning Sensation	Chedan Sadya vyadhi
8)	Alaji Advanced stage of phlyctenular conjunctivits	Tridosha a) shukla Krishna sandhi (sushrutha) karneeni ka (vagbhat)	Features same as above but more severa	Asadya
9)	Krimi granthi (Blepharitis)	Kaphaj a) Pakshma varthma sandhi (sushruth) b) Kaneenika apang (vagbhat)	Small cysts formation with pain itching Burning disceomfort and falling of eye Lashes	Bhedan Sadya vyadhi

वर्त्मगत रोग

उत्सङ्गिन्यथ कुम्भीका पोथक्यो वर्त्मशर्करा ।
तथार्शोवर्त्मशुष्कार्शस्तथैवाजंननामिका ॥
वहलं वर्त्म यच्चापि व्याधिर्वर्त्मावबन्धकः ।
क्लिष्टकर्दमवर्त्माख्यौ श्यावर्त्म तथैव च ॥
प्रक्लिन्नमपरिक्लिन्नं च वर्त्मवातहतं यत् ।
अर्बुदं निमिषश्चापि शोणितार्शश्च यत् स्मृतम् ॥
लगणो विशनामा च पक्ष्मकोपस्तथैव च ।
एकविंशतिरित्येते विकारा वर्त्मसंश्रयाः ॥ सु. उ. 3 अ.

वर्त्मगत रोगी की सम्प्राप्ति

पृथग्दोषाः समस्ता वा यदा वर्त्मव्य पाश्रयाः ।
सिरा व्याप्यावतिष्ठन्ते वर्त्मस्वधिकमूर्च्छिताः ॥
विवर्ध्य मांसं रक्तं च तदा वर्त्मव्यपाश्रयान् ।
विकाराजनयन्त्याशु, नामतस्तान्निबोधत ॥

1. उत्सङ्गिनी

अभ्यन्तरमुखी बाह्योत्सङ्गोधो वर्त्मनश्च या ॥
विज्ञेयोत्सङ्गिनी नाम तद्रूपपिडकाचिता ॥ सु. उ. 3 अ.

2. कुम्भीकपिड़का या कुम्भीका

कुम्भीकबीजप्रतिमाः पिड़का यास्तु वर्त्मजाः ।
आध्मापयन्ति भिन्ना याः कुम्भीकपिड़कास्तुताः ॥ (सु. उ. 3/10)

3. पोथकी

स्राविण्यः कण्डूरा गुर्व्यो रक्तसर्षपसान्निभाः ।
पिड़काश्च रुजावत्यः पोथक्य इति संज्ञिताः ॥ (सु. उ. 3/11)

4. वर्त्मशर्करा

पिडकाभिः सुसूक्ष्माभिर्घनाभिरभिसंवृता ।
पिडका या खरा स्थूला सा ज्ञेया वर्त्मशर्करा ॥

(सु. उ. 3/12)

5. अर्शोवर्त्म वा वर्त्मार्श

एर्वारु बीज प्रतिमाः पिडका मन्दवेदनाः
सूक्ष्माः खराश्च वर्त्मस्थास्तदर्शोवर्त्म कीर्त्यते ॥

(सु. उ. 3/13)

6. शुष्कार्श

दीर्घोंकुरः खरः स्तब्धो दारुणो वर्त्मसम्भवः ।
व्याधिरेष समाख्यातः शुष्कार्श इति संज्ञितः ॥

(सु. उ. 3/14)

7. अंजननामिका

दाहतोदवती ताम्र पिड़का वर्त्मसम्भवा ।
पृथ्वी मन्दरुजा सूक्ष्मा ज्ञेयासांजननामिका ॥

(सु. उ. 3/15)

8. बहलवर्त्म

वर्त्मोपचीयते यस्य पिड़काभिः समन्ततः ।
सवर्णाभिः समाभिश्च विद्याद् बहलवर्त्म तत्

(सु. उ. 3/16)

9. वर्त्मावबन्ध वा वर्त्मबन्ध

कण्डूमताल्पतोदेन वर्त्मशोफेन योनरः ।
न समं छादयेदक्षि भवेद् बन्धः स वर्त्मनः

(सु. उ. 3/17)

10. क्लिष्टवर्त्म

मृद्वल्पवेदनं ताम्रं यद् वर्त्म सममेव च ।
अकस्माच्च भवेद्रक्तं क्लिष्टवर्त्म तदादिशेत् ॥

(सु. उ. 3/18)

11. वर्त्मकर्दम

क्लिष्टं पुनः पित्तयुतं विदहेच्छोणितं यदा ।
तदा क्लिन्नत्वमापन्नमुच्यते वर्त्मकर्दमः ॥

(सु. उ. 3/19)

12. श्याववर्त्म

यद् वर्त्म बाह्यतोन्तश्च श्यावं शूनं सवेदनम् ।
दाहकण्डूपरिक्लेदि श्याववर्त्मेति तन्मतम् ॥

(सु. उ. 3/20)

13. क्लिन्नवर्त्म

अरुजं बाह्यतः क्लिन्नं स्रवत्यपि ।
कण्डूनिस्तोदभूयिष्टं क्लिन्नवर्त्म तदुच्यते ॥

(सु. उ. 3/21)

14. अक्लिन्नवर्त्म वा पिल्ल

यस्य धौतानि धोतानि संबध्यन्ते पुनः पुनः ।
वर्त्मान्यपरिपक्वानि विद्यादक्लिन्नवर्त्म तत् ॥

(सु. उ. 3/22)

15. वातहत वर्त्म

विमुत्कसन्धि निश्चेष्टं वर्त्म यस्य न मील्यते ।
एतद्वातहतं विद्यात् सरुजं यदि वारुजम् ॥

(सु. उ. 3/23)

16. अर्बुद

वर्त्मान्तरस्थं विषमं ग्रन्थिभूतमवेदनम् ।
विज्ञेयमर्बुदं पुंसां सरक्तमवलम्बितम् ॥

(सु. उ. 3/24)

17. निमेष वा निमिष

निमेषणीः सिरा वायुः प्रविष्टो वर्त्मसंश्रयाः
चालयत्यतिवर्त्मानि निमेषः स गदो मतः ॥

(सु. उ. 3/25)

18. शोणितार्श

छिन्नाश्छिन्ना विवर्धन्ते वर्त्मस्था मृदवोङ्कुराः ।
दाहकण्डुरार्जापेतास्तेऽर्शःशोणितसंभवा ॥

(सु. उ. 3/26)

19. लगण

अपाकः कठिनः स्थूल ग्रन्थिर्वर्त्मभवोरुजः ।
सकण्डूः पिच्छिल : कोलप्रमाणो लगणस्तु सः ॥

(सु. उ. 3/27)

20. बिसवर्त्म

शूनं यद् वर्त्म बहुभिः सूक्ष्मैश्छिद्रैः समन्वितम् ।
बिसमन्तर्जल इव बिसवर्त्मेति तन्मतम् ॥

(सु. उ. 3/28)

21. पक्ष्मकोप

दोषाः पक्ष्माशयगतास्तीक्ष्णाग्राणि खराणि च ।
निर्वर्त्तयन्ति पक्ष्माणि तैर्घुष्टं चाक्षि दूयते ॥

(सु. उ. 3/29)

वाग्भट अनुसार

पक्ष्म तथा वर्त्म के २४ रोग–

....चलस्तत्र प्राप्य वर्त्माश्रयाः सिराः ।
सुप्तोत्थितस्य कुरुते वर्त्मस्तम्भं सवेदनम् ॥
पांसुपूर्णाभनेत्रत्वं कृच्छ्रोन्मीलनमश्रु च ।
विमर्दनात्स्याच्च शमः कृच्छ्रोन्मीलं वदन्ति तत् ॥
चालयन्वर्त्मनी वायुर्निमेषन्मेषणं मुहुः ।
करोत्यरुड़ निमेषोसौ वर्त्म यत्तु निमील्यते ॥
विमुत्कसन्धि निश्चेष्टं हीनं वातहतं हि तत् ।
कृष्णाः पित्तेन बह्वयोन्तर्वर्त्म कुम्भीकबीजवत ॥
आध्मायन्ते पुनर्भिन्नाः पिटिकाः कुम्भिीसंज्ञिताः ।

सदाहक्लेदनिस्तोदं रक्ताभं स्पर्शनाक्षमम् ॥
पित्तेन जायते वर्त्म, पित्तोत्क्लिष्टमुशन्ति तत् ।
करोति कण्डुं दाहं च पित्तं पक्ष्मान्तमास्थितम् ॥
पक्ष्मणां शातनं चानु पक्ष्मशातं वदन्ति तम् ।
पोथक्यः पिटिकाः श्वेताः सर्षपाभा घनाः कफात् ॥
शोफोपदेहरुक्कण्डूपिच्छिलाश्रुसमन्विताः ।
कफोत्क्लिष्टं भवेद्वर्त्म स्तम्भक्लेदोपदेहवत ॥
ग्रन्थिः पाण्डुररुक्पाकः कण्डुमान कठिनः कफात् ।
कोलमात्रः स लगणः किंचिदल्पस्ततोपि वा ॥
रक्तं रक्तेन पिटिका तत्तुल्यपिटिकाचिता ।
उत्सङ्गाख्या तथोत्क्लिष्टं राजिमत्स्पर्शनाक्षमम् ॥
अर्शोधिमांसं वर्त्मान्तः स्तब्धं स्निग्धं सदाहरुक ।
रक्तं रक्तेन तत्स्रावि छिन्नं छिन्नं च बर्धते ॥
मध्ये वा वर्त्मनोन्ते वा कण्डूसा रुग्वती स्थिरा ।
मुद्गमात्रासृज ताम्रा पिटिकांजननामिका ॥
दोषैर्वर्त्म बहिः शूनं यदन्तः सूक्ष्मखाचितम् ।
सस्रावमन्तरुदकबिसाभं बिसवर्त्म तत् ॥
यद्वर्त्मोत्क्लिष्टमुत्क्लिष्ट मकस्मान्म्लानतामियात् ।
रक्तदोषत्रयोत्क्लेशाद् वदन्त्युत्किल्ष्टवर्त्म तत् ॥
श्याववर्त्म मलैः सास्रै. श्यावं रुक्क्लेदशोफवत्
श्लिष्टाख्यवर्त्मनी श्लिष्टे कण्डूश्वयथुरागिणी ॥
वर्त्मनोन्तः खरा रूक्षाः पिटिकाः सिकतोपमाः ।
सिकतावर्त्म कृष्णं तु कर्दमं कर्दमोमम् ॥
बहलं बहलैर्मांसैः सवर्णैश्चीयते समैः ।
कुकूणकः शिशोरेव दन्तोत्पत्तिनिमित्ततः ॥

स्यात्तेन शिशुरुच्छूनताम्राक्षा वीक्षणाक्षमः ।
सवर्त्मशूलपैच्छिल्यः कर्णनासाक्षिममर्दनः ॥
पक्ष्मोपरोधे सङ्कोचो वर्त्मनोर्जायते तथा ।
खरतान्तर्मुखत्वं च लोम्नामन्यानि वा पुनः ॥
कण्टकैरिव तीक्ष्णाग्रैर्घृष्टं तैरक्षि शूयते ।
उष्यते चानिलादिद्विवडरुपाहः शान्तिरुद्घृतैः ॥
कनीनके बहिर्वर्त्म कठिनो ग्रन्थिरुन्नतः ।
ताम्रः पक्वोस्रपूयास्रूद् अलज्या ध्मायते मुहुः ॥
वर्त्मान्तर्मासपिण्डाभः श्वयथुर्ग्रथितोरुजः ।
स्रास्रौः स्यादर्बुदो दोषैर्विषमो बह्यतश्चलः
चतुर्विंशतिरित्येते व्यधयो वर्त्म संश्रयाः

VARTHMA ROGAS
(Diseases of eye lids)

NIDANA :-

Vitiated vatadi doshas individually or togetherly localise in the vessels of varthma, vitiates twak, raktha, mamsa and medas and causes different types of diseases in the eye lids:

1) Varthma rogas according to Sushruth are 21
2) Varthma rogas according to Vagbhata are 24

Sushrutha -21

1) Uthsangini	2) Kumbheeka	3) Pothaki
4) Vartma sharkara	5) Arsho varthma	6) Shushkarsha
7) Anjana namika	8) Bahala varthma	9) Varthmaavabandha
10) Varthma Kardama	11) Klistra varthma	12) Shyava Varthma
13) Praklinna varthma	14) Aklinna varthma	15) Vata hatha varthma
16) Varthma arbuda	17) Nimesha	18) Shonitarsha
19) Lagana	20) Bisa varthma	21) Pakshma kopa.

Vagbhata -24 diseases :-
Among 24, 15 are as like Sushruta's diseases, they are
Serial numbers - 1,2,3,4, (called it as Sikatha varthma), 5 (called it as varthmarsha), 7.8. 10. 12. 15. 16, 17, 19, 20, 21 (Pakshmoparoda).
The Extra 9 diseases are : 1) Alaji 2) Pakshma shaatha 3) Kruchronmeelana 4) Kukunaka 5) Shlishta varthma 6) Uthklista 7) Uthklishta varthma 8) Kaphothklista 9) Pittothklista.

1) UTHSANGINI (SUSHRUTHA) - UTHSANGA (VAGBHATA)

(Chalazian cyst - or meibomian cyst or Tarsal cyst)
" It is varthmaja - Tridoshaja lekhana sadhya vyadhi "

Signs - symptoms :-

One or multiple cysts originates commonly in the lower eye lid, if multiple cysts present the bigger cyst is encircled with others. (multiple chalazia.)

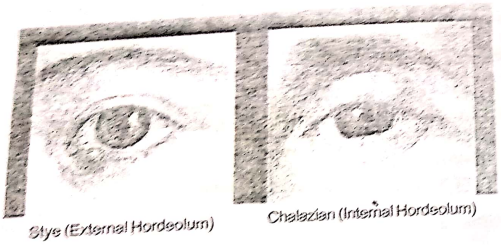

Stye (External Hordeolum) Chalazian (Internal Hordeolum)

Symblepharon

Congenital ptosis, more marked on the right side. Note the wrinkling of the forehead in the attempt to open the eye. (By courtesy of Kamel.)

Follicles in trachoma

Conjunctival Concertions

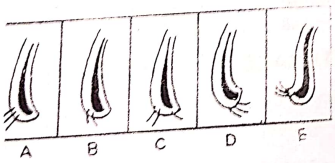

Section of the upper eyelid showing normal and abnormal positions of tarsus and eyelashes. A-Normal eyelid; B-Trichiasis; C-Distichiasis; D-Entropion; E-Ectropion (May and Worth

Description :

a) Abhyanthara Mukhi :- The Cyst opens toward the internal surface of eye lid (towards palpebral Conjunctiva)

Bahya uthsanga :- Cystic swelling is seen through the skin of eye lid

c) Adho Varthma :- Commonly originates in the lower eye lid

d) Kathina :- Hard Cyst
e) Manda vedana - with slight pain

f) Sraveth sraavam Kukkutanda rasopama :- Discharges fluid resembling egg yolk After suppuration or after incision,

Vagbhath ;- Red pitica arises due to raktha vitiation, among them a big pitica is encircled with the small piticas. He called it as uthsang.

(Summary :- One or multiple cystic swellings originates commonly in lower eye lid, swelling appears through the skin of eye lid but cyst opens towards palpebral conjunctiva, it flows egg yolk like fluid after suppuration or incision, is known as Uthsangini).

Chikitsa : - Lekhana Sadhya Vyadhi
Pitica if bigger Non suppurative (Apakwa) chedhana followed by Lekhana has to do pitica if smaller suppurative (pakwa) Bhedhana followed by Lekhana has to do.

After pradhana karma :- (Pashchath Karma)
1) Swedanam and 2) Prathisarana has to do with manashila kaseesa shunti maricha pippali rasanjana saindhava lavana + madhu, after 5-10 minutes, 3) prakshalana with Lukewarm water, then 4) Ghritha sekam & Bandhanam (Vranopachara has to do)

2) **Lagana** (Sushrutha) or **Nagana** (Bhava mishra) or **Alagana** (others)

CHALAZIAN CYST - MEIBOMIAN CYST - TARSAL CYST.

it is varthmaja Kaphaja Bhedan Sadhya Vyadhi.

Description :-

A small cystic swelling, resembling kola phala (Badari phala), originates in the eye lids, which is hard (kathima), stout (Sthula), painless (Avedanam), Sticky (Pischila), with itching sensation and doesn't suppurate (Apkwam).

Vagbhata mentioned it is white in colour and occurs due to the vitiation of kapha dosa. " Bhavamishra called it as nagana"

" It is also a cystic swelling or hard tumour of meibomian glands of eye lids "

Chikitsa:- Bhedhana Sadhya vyadhi and prathisarana should do with gorochana, Yavakshara, neela tuttha pippali + Madhu - and has to treat like Vrana (Ulcer)

Note : - 1) If the gland is bigger Bhedhana, kshara Karma and Agni Karma has to do.

2) Being the non suppurative cyst the treatment should be chedan lekhan and pratisaran instead of Bhedana (Others)

3. BAHALA VARTHMA (MULTIPLE CHALAZIA)

It is varthmaja Rakthaja Lekhana Sadhya vyadhi

Description :-

Hard - (kathina), same coloured and same sized papules originates in the eye lid completely and causes the eye lid thicker, is known as Bahala varthma.

Chikitsa :- Lekhana Sadhya Vyadhi.

1)Murudu Sweda 2) Pracchana 3) Lekhana and 4) Pratisarana

After 5 to 10 minutes 5) Ushnodaka prakshalana 6) Ghritha sekam and Bandhana, has to do

(Pratisarana dravyas are Manashila, Kaseesa, Shunti, Marcha, Pippali, rasanjana, Saindhava lavana + madhu)

Note ;- Specific site of the disease is not mentioned so it can be correlated to muliple chalazia or follicular conjunctivitis or A form of trachoma

CHALAZIAN CYST OR MEIBOMIAN CYST OR TARSAL CYST

It is a chronic inflammatory granuloma of meibomian gland. (Tarsal glands)

PATHOLOGY:- The staphylococcus is the commonest organism that enters into meibomian gland through its duct, as a result of low grade infection, the glandular tissue of the gland is replaced by granular tissue, leads to enlargement of the gland- the glandular secretion is jelly like (Fatty). If more then one cyst develops it is called as multiple chalazia.

AETIOLOGY:- Low grade infection often associatas with refractive errors.

SYMPTOMS :- Slight heavyness, pain or irritation
(The symptoms depending on the size of the cyst)

SIGNS:- 1) Small cystic or hard swelling, in the size of a pea, on the eye lid, a little distance away from the lid margin.

2) Swelling is fixed to the tarsus. skin is free with no signs of inflammation.

3) Tarsal conjunctiva is velvety or purple.

4) If the duct is affected the swelling is seen at the lid margin.

5) If it is secondarily infected called as internal Hordeolum.

Treatment :-

1) A very small chalazian may under go resolution.
2) Hot fomentation is suggestive.
3) Antibiotics Local as well as systemic, (Sulfonamides- chloremphenicol)
4) Bigger chalazian should be incised vertically under local anaesthesia and granulation tissue should be scooped out.
5) Very hard chalazia (comming at canthus) should be exicsed (very rare).
6) The bigger and recurrently arising cyst has to send for Histology to elicit the carcinoma (rare).

4) KUMBHEEKA PITICA (SUSHRUTHA)

Kumbhee Pitica (Vagbhata)

(Stye or zeis gland cyst or External Hordeolum).

It is **varthmaja sannipathaja Lekhana Sadhya vyadhi.**

Description :- Small papules (cysts) resembling the seeds of pomegranate fruit (Kumbheeka beeja Sadrusha pitica) originates in the eye lid margin (Varthmantha pitica), suppurates (get pakwam), discharges the fluid and bulges again (Admapayanthi bhinna).

Vagbhata :- Called it as Kumbhee pitica that originates in varthma due to vitiation of pitta dosha, the colour of pitica is RED AT FIRST AND THEN BECOMES BLACK.

Chikitsa :- Lekhana sadhya vyadhi.

A) Sushrutha's Treatment principle is like Uthsangini.

B) Vagbhata's Treatment principle is as follows :- 1) Lekhana 2) pratisarana 3) sekam with Aamalaki yastimadu, patola kwatha and ghritha.

Note : - 1) If is the cystic swelling of zeis gland that develops at the eye lid margin, known as multiple stye or External Hordeolum

2) Some body has commented it as chalazian (meibomian cyst) if so that may be marginal chalazian cyst that occurs at lid margins due to obstruction of duct of meibomian gland.

5) ANJANA NAMIKA

(Multiple stye or zeis gland cysts or External Hordeolum)

It is varthmaja Rakthaja Bhedana Sadhya Vyadhi.

Description : - Small (Sukshma), copper coloured (Tamra varna red colour) piticas (follicles) originates in the eye lid, the patient experiences daha (burning sensation) Toda (Pricking pain) and manda ruja (slight pain).

Vagbhata :- Sthira (fixed), mudga pramana, Tamra varna (Red) piticas (follicles), originates either inthe middle or in the margin of eye lid, due to vitiation of raktha dosha and exihibits the symptoms like daha (Burning), toda (Pricking Pain) and kandu (itching sensation). It is explained as Anjan namika.

Chikitsa :- It is Bhedhana Sadhya vyadhi.

Treatment Principle :-
1) Mrudu Sweda
2) Bhedhana
3) Pratisarana with Ela Tagara, manasila, saindhava lavana + madhu).

Note :-It can be compared to multiple stye (zies gland cyst) but vagbhata mentioned it' s Location as, not only margin of lid - but also middle of the eye lid if so it can be correlated to Chalazian also .

EXTERNAL HORDEOLUM OR STYE OR ZEIS GLAND CYST

It is a suppurative inflammation of the follicle of the eye lash including the glands of zeis.

The Causative agent is **coagulase positive staphylococcus.** Common in the adults, often occurs in crops, frequently associated with constipation and un corrected refractive errors, diabete's malnutrition (low socio econmic status.

Symptoms :- Acute pain in the lid margin, Heavyness and burning sensation.

Signs :- (1) Swelling, redness, marked oedema of effected lid margin.

2) Congestion and chemosis of neighbouring conjunctiva.
3) Finally a white pus point appears on the lid margin at the base of one of the cillia , indicates suppuration of the gland.
4) Enlargement of pre auricular lymph nodes.

Treatment :-
1) Hot compression to hasten suppuration
2) Broad spectrum antibiotics local/systemic (sulfa drugs or Ampicillin)
3) Pulling of affected cilia to drain the pus, if not a tiny Horizontal incsion should give at the affected area to drain the pus.
4) Treating the neighbouring inflammatory conditions.

6) POTHAKI

(Trachoma - follicular conjunctivitis)

It is **Varthmaja kaphaja Lekhana Sadhya vyadhi**

Multiple piticas (follicles) resembling **Raktha sarshap beeja** originates in varthma due to the vitiation of kapha dosha, associated symptoms are srava (Lacrimation,) Kandu (itching sensation), Gurutwa (heavyness of eye lid) and Ruja (Pain).

Vagbhata : Hard follicles resembling the seeds of **Swetha sarshapa** Originates in varthma due to the vitiation of kapha dosha. Associate symptoms are shopha (oedema), pischila srava (Sticky exudation), Vedana (pain), Kandu (itching) and Upadeha. (Membrane formation) due to collection of exudates

Note :- In the primary condition, follicles appears red (Raktha sarshapa), afterwards the colour changes into white (Swetha sarshap) so above two types of descriptions are not opposite.

Chikitsa : It is Lekhana sadhya vyadhi, Sushrutha suggested.

1) Pracchana 2) Lekhana 3) Pratisaran 4) Prakshalan 5) Seka and bandan 6) After Pracchan Lekhana The prathisarana has to do with fine powders of manashila, kaseesa, shunti, maricha, pippali, Rasanjan, saindhava lavana + madhu, after 5 to 10 minutes prakshalana with luke warm water, then seka with ghrita and Bandhana, is advised.

Other Seka yogas :- 1) Decoctions of khadhira, phalasha shigru twak.
2) Decoction of haridra, Daru haridra, Triphala, Yastimadu + madhu.

3) Aashchyotan with extracts of Aamra patra, jambu patra, etc.
4) Aaschyotan with Triphala, Khadhira + madhu.
5) Anjana with vidanga,Laksha, Daru haridra, Gyrika, Haritala, Manashila + Madhu.

Note : - If the disease is not controlled with above treatments Lekhana has to do again.

TRACHOMA

It is a kind of Keratoconjunctivitis (spontaneous affection of Keratitis and conjunctivitis) . It is a chronic contagious disease

Causative organism :- is chalamydia or Bedsonia group of organism (it is not a true virus, occupies an intermediate portion betweeen smaller bacteria and true virus and if affects the epithelium of cornea and conjunctiva produces inclusion bodies known as hallberstaedter prowazek (H.P. inclusion bodies).

It is common in the poor and in the dusty weather. Incubation period is 6 to 12 days, infection spreads by contamination with the conjunctival discharge through fingers, towels and flies etc.

Pathology :- Conjunctival changes are mostly seen in tarsal and fornix conjunctiva, marked congestion is seen, epithelium shows degenerative changes and the superficial cells exfoliate, in addition to degeneration there is **proliferation with papillary formation.** Submucoid tissue shows diffuse infiltration of lymphocytes which later on become aggravated to form follicles.

Corneal changes :- Pannus formation - cellular infitration of lymphocytes which invades the epithelium with corneal vascularisation leads to Superficial keratitis, corneal opacities, pannus formation, and other complications.

Symptoms :- Lacrimation, foreign body sensation, stickyness of eye lids (muco purulent discharge).

Signs :- Mac callan stages of trachoma (4 stages) Ist, 2nd stages :- corneal conjunctival changes explained in pathology.

3rd stage :- Stage of cicatrization, It Starts when healing starts. Follicles Atrophied, pannus retrogresses leaving opacities behind, scaring starts (horizontal white lines across the tarsus and palpebral conjunctiva, the line is known as cicatrical line of arlt).

4th stage : stage of complications :- Entropeon, Trichiasis, xerosis of conjunctiva, corneal opacities - corneal ulcer, chalazian etc.

Diagnostic criteria :- (1) Conjunctival papillary formation.
2) Pannus on cornea 3) Cicatrization of palpebral conjunctiva
Treatment 1) painting with CuSo4 if no corneal ulcer, painting with Ag No_3 if ulcer present. 2) Oral Local antibiotics 3) Atropine 1 % ointment if cornea is involved.

7.VARTHMA SHARKARA (LITHIASIS CONJUNCTIVAE)

It is **Varthmaja Sannipathaja** Lekhana sadya vyadhi, multiple small hard follicle is encircle with so many small follicles, is discribed as varthma Sharkara.

Vagbhata :- explained it in the of name of **Sikatha Varthma** in which multiple small follicles resembling the sand particles are observed.

Chikitsa - Lekhana and pratisarana.
Like uthsangini and Kumbheeka.
(It can be compared to Lithiasis conjunctiva or a form of trachoma.)

Lithiasis Conjunctivae:- Minute hard yellow spots on palpebral conjunctiva, it occurs due to accumulation of epithelial cells and inspissated mucosa in depressions, it never become calcareous but causes severe foreign body sensation.

8) ARSHOVARTHMA

A form of trachoma

It is varthmaja **Sannipathaja** chedan Sadhya vyadhi, pain full, small rough piticas (follicles or nodules) resembling the Ervaru beeja (kakadi beeja - cucumbar seeds) originates in the internal surface of the eye lid, is known as Arshovarthma (It develops on the - external aspect of eye)

Vagbhata called it as varthmarsha, in which vitiated **Raktha dosha** produces painful, burning rigid, oily red coloured masses (adimamsa) in the internal aspect of eye lid. The masses recurs even after excision

Chikitsa 1) Swedana 2) Chedhana 3) pratisarana with saindhava lavana, kaseesa and pippali 4) the residual part - should be burnt with shalaka, 5) If the residual part further remained, kshara pratisarana should be advised.

9) SHUSKARSHA

(Polyp of the palpebral Conjunctiva)

It is varthmaja Sannipathaja Chedan Sadhya Vyadhi.

A Lengthy, hard, rigid, troublesome, polyp (ankura) develops in the internal surface of the eye lid.

Chikitsa : - Chedhan Sadhya Vyadhi, like varthmarsha.

10) VARTHMA BANDHA OR VARTHMAAVABANDHA

(Imperfect closure of eye lids following inflammatory swelling or Angio neurotic oedema)

It is varthmaja Sannipathaja Lekhana sadhya vyadhi. It is condition in which imperfect closure of eye lids occur due to varthma shopha, associated with kandu (itching sensation) and alpa-toda (Slight pricking pain) - is known as varthma bandha.

Chikitsa :- 1) Lekhana - shotha hara chikitsa
2) Pracchana & Lekhana Pratisarana

11) KLISTA VARTHMA (Allergic Conjunctivitis)

It is varthmaja Rakthaja lekhana sadhya vyadhi:

The eye lids suddenly becomes soft, coppery red coloured with negligible pain, is known as klista varthma.

Videha explained that it is due to kapha and Raktha Vitiation in which the eye lids suddenly become red like japa pushpa (Hibiscus flower)

Chikitsa 1) Nidana Parivarjana (avoiding the allergic causes)
2) Lekhana and pratisaran 3) pracchana Lekhana and Pratisarana

12. Varthma Kardama

It is varthmaja Sannipathaja Lekhana Sadhya vyadhi.

If klista varthma get burnt by pitta dosha, klinnatwa or Ardhratha or Exudation increases, that is known as Varthma Kardama.

Klista Varthma (Raktha + Kapha) + pitta = Varthma Kardama (Kapha + Raktha + Pitta)

Note : It is secondary to Klista varthma in which more exudation or sticky lacrimation is observed.

Chikitsa : 1) Lekhana 2) Vrana shotha Chikitsa 3) Abhishyanda Chikitsa. should give.

13) SHYAVA VARTHMA

(Inflammatory Condition of eye lid)

It is sannipathaja lekhana Sadhya vyadhi. the eye lid completely (externally - Internally) inflames and become blackish (Shyama varna)

Signs & Symptoms : - Blackish discolouration of eye lids with pain, burning, itching, discharge and oedema

Vagbhata explained that it is due to the vitiation of Tridosha and Raktha dosha.

Chikitsa :- Lekhana Sadya vyadhi a) Lekhana b) Pratisarana
c) Vrana or shothahara Chikitsa

14) PRAKLINNA VARTHMA OR KLINNA VARTHMA

(A form of Blepharitis or allergic conjunctivitis)

It is varthmaja, Kaphaja, Ashastra Krutha, Sadhya vyadhi.

A Painless swelling (of external aspect) of eye lid, assoicated with itching pricking pain and sticky exudation (some body explained it as " pilla vyadhi")

Chikitsa - Aushadha Sadhyam - (Asastra Kruth)

1) It can be treated by medicines it self 2) Anjana Prepared with Triphala or phalasha pushpa or apamarga, rasa kriyanjan should prepare in copper vessel 3) Varthi anjan with kaseesa, samudraphena, Rasanjan , jathi pushpa + honey (yoganjan) 4) Srotonjan + honey 5) Vamshi moola kept in copper vessel, Triphala phalasha pushpa and apamaraga rasakriyaanjan 6) Amalaki phala swarasa Aashchyotan or rasakriya anjan 7) Abhishyanda chikitsa

15) AKLINNA VARTHMA

(Ankyloblepharon;Symblepharon ; Blepharo - phimosis)

It is sannipathaja Ashastra krutha, sadhya vyadhi - it is also named as " pilla vyadhi" Though there is no inflammation, and discharge, and the eye lids are perfectly cleaned, the eye lids sticks together is known as Aklinna varthma.

Chikitsa :- Aushadha Sadhyam - Ashastra Krutam

1) It can be treated by medicines it self 2) anjana like praklinna varthma 3) Anjan with tuttha, kajjali which is kept in copper vessel and in ghee. 4) Anjana with Samudra phena, Lavan, Shankha, mudga, & sweta maricha

ANKHYLOBLEPHARON

It is a condition where the lid margins Adhere together, it usually associate with symblepharan

a) 1) Congenital 2) Acquired. b) 1) Partial 2) Total

Treatment :- Surgical separation of lids or lid margins.

2) Symblepharon

It is a condition in which the lid becomes adhered to the eye ball (Adhesion between palpebral conjunctiva and bulbar conjunctiva). It is due to rawness of the conjunctival surfaces Ex:- in burns & Ulcerative conditions, and in membranous conjunctivitis.

Treatment :- operative separation

Blepharo Phimosis

It is a condition in which the palpebral fissure of the eye is diminished without adhesion, it is usually congenital, and observed at the inner and outer canthus.

16. VATA HATHA VARTHMA

(Lagophthalmos - ptosis)

It is varthmaj vataja Asadhya Vyadhi.

A) According to the description of sushrutha, the disease can be compared to Lagophalmos.

Description: - Due to vitiation of vata, the Kaneenika apanga and varthma shukla sandhi are paralysed so that the person can't able to close his eye lids properly, (pain may exist or not.) **"Varthma yasya na meelyathe"**

B) According to the description of vaghata and **Yogaratnaker,** the disease can be compared to the **ptosis. " Varthma yathu nimeelyathe "**

The kaneenika apanga and the varthma shukla sandhis are paralised when the lids are closed, so the person can't able to open his eye lids (eye lids dropped)

Chikitsa - Asadhya (Tarpan snehan Anjan etc, can try for the strengthening of muscles and nerves)

LAGOPHTHALMOS :

It is a condition in which the eye lids cann't be closed properly when the eyes are closed. (Improper closure of eye lids)

Causes :- (1) Congenital abnormalities of lid. 2) Paralysis of orbicularis oculi muscle (facial nerve palsy) 3) Cicatrical contraction of eye lid (trachoma), ectropion or proptosis are the causes commonly observed.

Treatment of Lagophthalmos:-

1) Application of ointment to keep the cornea moist, if not lead to exposure keratitis. 2) Tarsorraphy operation to narrow the palpebral aperture. 3). Cause should be treated.

PTOSIS

it is a condition in whcih the eye lids are dropped below its normal position (3rd cranial nerve palsy)

a) Unilateral or bilateral
b) Partial or total

Causes :- (1) Congenital maldevelopment of levator palpebrae superioris muscle.

2) Congenital weakness of superior rectus muscle.
3) Acquired ptosis due to **paralysis** (partial or total) of 3rd cranial nerve (oculomotor)
4) Paralysis of cervical sympathetic nerves that supplies to muller muscle.
5) Lack of support of upper eye lid, as in case of micro ophthalmos, shrunken eye ball etc.
6) Due to increased weight of upper eye lid as a result of Oedema - Hypertrophy - tumour, etc.
7) Trauma to levator muscle, etc.

Symptoms :- If the dropping of eye lid covers the pupil the only visual disturbance occurs.

Sign :-1) Lid covers most of the cornea (abnormal)
2) Palpebral fissure get narrowed.
3) To see the objects, head should be tilted back to draw the lids upwards.

Treatment :- Congenital ptosis, only by operative correction.

a) If muscle action is existing the length of the muscle should be reduced.

b) If levator muscle's action is abolished but superior rectus muscle is normal this muscle is attached to the anterior surface of upper tarsal plate.

c) If above two muscles are inactive, The frontalis muscle is attached to tarsal plate, by which the lid moves along with contraction of frontalis

Acquired ptosis - Cause should be treated.

16) VARTHMA ARBUDA
(Benign Tumour in the eye lid)

It is varthmaja, sannipathaja, sadhya vyadhi, a painless (Avedanam), irregular (Vishamam), red (Saraktham) cystic swelling (Grandhi) develops by hanging from the internal surface of the eye lid, is explained as Varthma Arbuda.

Vagbhata used the word " Mamsa Pindhabha shotha" instead of grandhi.

Chickitsa : Chedhana sadhya vyadhi.

Treatment Principle :

1) Swedana 2) chedhana 3) prathisarana with the fine powders of lavana, kaseesa and pippali 4) The residual part should be burnt with shalaka 5) if any residue remained again that should be scraped out by the application of kshara (prathisarana).

Note:- It is a curable disease so it can be corelated to benign tumour of eye lid

17) NIMESHA
(Blinking of eye lids)

It is varthmaja, vataja, Asadhya vyadhi. Vitiated vata enters the nimeshani sira and Sandhies of varthma - Causes painless, abnormal and increased movements of eye lids (Repeated opening and closing of lids)

Chikitsa :- Asadhya vyadhi.

BLINKING OF EYE LIDS.

For the movement (physiologically) of eye lids.

Orbicularis oculi-(Facial Nerve supply)

Superior rectus - (Oculomotor nerve) and

Levator palpebrae superioris (Oculomotor nerve) are responsible.

1) Either due to congenital anomalies of above nerves or
2) Reflex stimulations of cervical sympathetic nerves or
3) Sensory stimulation of the branches of Trigeminal nerve (Foreign bodies - inflammatory Focus (conmeal ulcer etc.)
4) Excessive stimulation of retina for exposing to dazzling light etc
5) Hysteria.

In above conditions we can see the vigorous movements of eye lids (Blepharo spasm) But in modern science there is no diseases for the abnormal vigorous movements of eye lids.

TUMOURS OF EYE LIDS

Benign tumours (Varthma Arbuda)

1) Papilloma :- There is a vascular mesodermal core surrounded by proliferated epithelium, rarely becomes malignant

2) Xanthelasma :- presence of xanthelasma cells in the subepithelial layers of the skin of eye lid

3) Molluscum contagiosum :- It contain Molluscum bodies which are oval highly refractile and derived from degeneration of the epithelial cell

4) Angiona :- Small localised nodule either capillary or cavernous in nature

5) Simple melanoma :- it affects the epidermis or the dermis of eye lid.

Malignant tumours
(Shonitharsha)

1) Epithelioma :- Derived from the epithelial cell of the skin of eye An ulcerative nodule develops at the lid margin

2) Rodent ulcer :- A small nodule covered by a crust which drops off at times to allow a small amount of serosanguineous discharge malignant but does nut metastasise.

3) Malignant Melanoma :- A slowly progressive pigmented lesion and invades the epidermis to form intra epiderma melanoma

Note : - **Benign tumours :-** not complicative need excision to controle the disease Malignant tumour complicative, need surgery and Radio therapy to treat the disease completely.

19) SHONITHARSHA

(Malignant tumour of eye lids (carcinoma of eye lid)

It is rakthaja Asadhya Vyadhi (Vata Raktaja - videha) in which red (tamra varna), soft - (mrudu) Mamsankuras (Granulation tissue or polypoidal mass) originates in the eye lids - Associated with pain (painless according to some authors) Burning sensation and itching sensation. It recurs even after excision

Treatment - Asadhya. (in curable)
(Chemotherapy and radiation therapy may give some result in the treatment of carcinoma.

20) BISA VARTHMA

(Porous oedema of eye lid)

It is Tridoshaja sadhya Vyadhi,
The skin of the eye lid is inflammed due to the vitiation of Tridoshas, and causes multiple small holes and oozing of inflammatory exudations through the varthma like in pot, so only known as Bisa varthma.

Chikitsa : 1) Bhedhana sadhya vyadhi.2) Pratisaran with saindhava, lavan, kaseesa, pippali, pushpanjan, manahshila, Ela and honey. (In general anti inflammatory treatment is given, if abscess is formed Bhedhana (Incision and drainage) is suggestive

21) PAKSHMA KOPA (SUSHRUTHA), OR PAKSHMOPARODA (VAGBHATA)

(Trichiasis with entropion)

It is sannipathaja **YAPYA** vyadhi.

The vitiated doshas by vitiating the roots of cilia (eye lashes) causes the eye lashes hard sharp and misdirected (Trichiasis), with inverted llidmargin (entropion) The hard sharp misdirected cilia prick and injures the cornea (Akshi Shotha) and produces severe complications
" Teekshnagrani Kharanicha " (Sharp and hard eye lashes)
" Nirvarthayanthi pakshmani " (eye lashes with lid margin is inverted).

Vagbhata :-

a) Romnaamanyani Va punah (Additional Production of mis shaped cilia) (upa pakshma mala - Distichiasis)

b) Tiirakshi shoyathe (eye becomes inflamed due to pricking of cilla to cornea etc.)

(soft eye lashes becomes sharp, eye lid margin is inverted so sharp cilia pricks or injures the cornea and produce corneal complications)

Chikitsa : 1) Sannipathaja yapya vyadhi
2) Shastra Karma 3) Agni Karma, 4) kshara Karma, 5) Aushada karma
(4 types of treatments)

a) Shastra karma
1) Sneha karma (Oleation)
2) utthana Shayanam (Sleeping on back)
3) eye has to close (Shut)

2 parts from the base, 1 part from margin of eye has to leave and cut the remaining middle part of skin of eye lid in the yava shape, suture it with Horse hair, apply ghritha + madhu for healing The sutured horse hair should tie to the fore head (lalatha bandhanam), after 5 days sutures has to remove and apply the gyrica churna for perfect healing.

2 and 3rd Methods (Shastra and Agni Karma)
If the disease is not controlled with shastra karma,kshara, Agni karma has to do.
4) Aushada Chikitsa.

Cut the misplaced eye lashes and apply the essence (Gandham) of hareertaki or Tuvaraka phala

As per Yoga ratnakar :-
The cilia are burnt with loha shalaka and apply the anjana (Pushpakaseesa got bhavana in Tulasi swarasa which was kept in copper vessel for 10 days has to use as anjana).

If the disease is not controlled by above treatments, Rechana, Aashchyotan, dhoom, nasya, lepa, Anjana, etc. should do.

Eversion of the punctum in a case of senile ectropion

Ectropion

Orbital cellulitis, (By courtesy of Jarrett.)

ENTROPION

Inversion of the (Rolling in) eye lid margin with its lashes is called entropion.

Types :- 1) cicatrical entropion - due to cicatrical contraction of the conjunctiva and tarsus, typically found in trachoma, burns and in injures of conjunctiva.

Treatment :- Tarsectomy.

2) Spastic entropion - Due to spasm of orbicularis oculi muscle, commonly found in the old, atrophy or absence of eye ball and prolonged bandaging

Treatment :- (Alcoholic injection to eyelid muscle (Wheeler's operation)

Signs & Symptoms:-

Corneal lesions, pain watering of eye photophobia or ignation, blurred vision and foreign body sensation

ECTROPION

Eversion of the (Rolling out) eye lid margin is known as ectropion

Types :-

1) spastic ectropion - seen in children with acute conjunctivitis, seen dated with blepharospasm

2) Cicatrical ectropion - following wounds, burns. Operative scars of eye lid.

3) Paralytic ectropion - Especially in lower eye lid due to facial paralysis

4) Senile ectropion - lower eye lid affects due to laxity of the skin and muscles in the old

Clinical features :-

Watering of the eye, conjunctival congestion, exposure Keratitis etc.

Treatment :- 1) spastic types - proper bandaging

2) Cicatrical types - Excision of the scar and skin grafting

3) Paralytic and

4) Senile types Plastic repair of the lower eye lid due to laxity of the skin and muscles.

TRICHIASIS
(Pakshma kopa)

This is a condition in which varying number of eye lashes are inverted (misdirected) causes injury to cornea and produce so many complications.

Causes:-

1) Congenital districhiases.
2) Spastic entropion,like in trachoma.
3) Blepharitis (ulcerative type)
4) Membranous Conjunctivitis (in diphtheria)
5) Scars due to injuries,operations, burns etc.
6) External hordeolum (stye)
7) Any other destructive diseases of lid margins.

Symptoms:-

1)Foreign body sensation (irritation) 2) Pain 3) conjunctival congestion 4) reflex blepharospasm 5) lacrimation 6) opacities and vascularisation of cornea 7) Corneal ulcers 8) photophobia.

Treatment:-

1) Misdirected cilia has to remove by epilation.
2) Destruction of hair follicle by diathermy or electrolysis (Galvano current is passed to the root of cilia by fine platinum needle.
3) plastic surgery.

ADDITIONAL DISEASES OF VAGBHATA

1) Kruchronmeelana

(Difficulty in opening the eyes (Blepharo spasm)

Vitiated vata enters the eye lids of sleeping person and causes difficulty to open the eye lids.

Associated symptoms are:-

Pain, Foreign body (Sandy) sensation, watering of eyes and feels happy by rubbing the eyes.

Chikitsa:-

Vatha hara chikitsa 1) swedana, 2) vasti 3) Snigda nasya 4) snigda dhooma 5) Snigda Anjana 6) The medicated ghee prepared with Draksha kalka + purana ghritam+ sugar.

2) **Alaji :-** A hard, red, cystic swelling develops on the external eye lid near Kaneenika sandhi, it suppurates, discharges the blood stained pus then gland bulges again. It can be compared to **External Hordeolum (stye) or lacrimal abscess.**

Chikitsa:- Like vrana shotha chikitsa.

3) Pakshma shaatha:- (Madarosis)

The vitiated pitta by vitiating the eye lid margins, causes burning sensation itching sensation and falling of lashes is known as pakshma shatha (congenital or Acquired, partial loss or Total loss of eye lashes)

Chikitsa :-

1) Canalisation of roots of cillia.
2) Jalaukavacharana at lid margins.
3) Vamana with milk and sugar cane juice
4) Nasya with the ghee prepared from Madhura sheetha Aushadha
5) Anjana with pushpa kaseesa churna, get bhavana in Tulasi swarasa and preserved in copper vessel for 10 days,

4) **Uthklista varthma -** (allergic conjunctivitis.)
Because of tridosha + Raktha vitiation the eye lid becomes dry (Atrophic changes)

Chikitsa - Abhishyandhi Chikitsa.

5) **Uthlista**

Eye lid becomes tender due to vitiation of rakta and is congested with follicles and capillary net formation.

Chikitsa - Shothahara chikitsa

6) **PittothKlista Varthma :-**

Because of pitta vitiation the eye appear red and tender and is associated with pain, discharge and burning sensation.

Chikitsa :- 1) Madhura ghritha snehana, and sira vyadhana, 2) rechan with trivrutha, 3) Lekhana, 4) Yastikashaya prakshalana 5) Dugda sechana.

7) KAPOTHKLISTA VARTHMA

Because of kapha vitiation the lid becomes rigid with sticky discharge and the lid margins sticked together.

Chikitsa :- Lekhana and pratisarana with kaseesa manahshila pippali Rasanjan + madhu.

Then vaman, Anjana, nasya, dhooma pana - Kaphahara therapy should give.

8) KUKUNAKA

(Ophthalmia Neonatorum or Acute conjunctivitis of infants.)

It is an eye lid disorder of children, arises during dentation period (Danthod bhava janya vikara) due to stanya dosha or prakopa

Signs, and symptoms :- Akshi shotha (oedema of eye ball) - Tamrakshi (red eyes), prakasha asahishnutha (photophobia), pain in the lids, sticky discharge from eye, itching sensation in the nose ear and eye (child is used to rub the above parts).

Sushrutha :- Considered the disease as varthma roga (under Abhishyanda) but not counted separately

Chikitsa :-

1) Raktha mokshana with Jalauka.
2) Lekhana with shephalika leaf.
3) Trikatu + madhu - pratisarana. (Local application)
4) Vamana with(Apamarga beeja, maricha, saindhava lavan, madhu+ stanya)
5) If the child cann't able to take the medicine it should be given to mother.
6) Parisheka with The decoctions of amra, Jambu, Aamalaki, ashmanthaka leaves
7) Ashchyotana with Triphala ghritha, Guduchi ghritha etc.
8) Varthi Anjan :- Manashila, Maricha, shankha, rasanjan, saindhava lavana, guda, madhu etc.
9) Varthi Anjan with murva yasti madhu, Amra twak - Satwam.
10) Gutikanjan with trikatu, palandu, Yastimadhu, Saindhava lavana, Laksha, gyrika with madhu.
11) Varthi Anjan with Nimba patra, Yastimadhu, Daru haridra, Tamra bhasma, lodhra + madhu.
12) Choornanjan :- Kanthaloha bhasma + ghritha or madhu or dugda.

Medicine to dhatri

1) Sneha panam (with medicated ghritha)
2) Vaman with pippali, sarshapa, saindhavlavan, yashtimadhu,
3) Rechan with the decoction of Hareetaki pippali draksha
4) Application of Musta, Haridhra, Daruharidra, pippali, to the breast
5) Gritha + sarsapa - dhoopam

(Varthma :- Lekhana - Raktha mokshan, parisheka, etc. should do)

9 SHISTA VARTHMA

The two eye lids sticked together with itching sensation, redness and oedema

Treatment :- Anti Inflammatory treatment.

KUNCHANA

(Bhavamishra - Yogaratnakar.)

The vitiated vatadi doshas causes varthma sankocha (Blepharo spasm) and the patient can not able to see the things.

It can be compared to blepharospasm in which the eye lids forcibly closed due to reflex stimulus

Congenital abnormalties of eye lids.

1) Coloboma of eye lid :- Triangular notching (Gaping) at the eye lid margin with out eye lashes and glands.

2) Epicanthus :- A perpendicular fold of the skin runs from the root of nose to the inner end, of the lower eye lid, concealing the medial canthus and caruncle. It causes difficulty in opening of eye lids and convergent squint.

3) Distichiasis :- Misdirected extra row of eye lashes which causes corneal lesions etc.

4) Ptosis :- Drooping of the upper eye lid, Usually due to paresis or maldevelopment of levator muscle

Inflammatory rare lesions of eye lids.

1) Syphilis of the eye lids :- A primary chancre occasionally occurs on one of the eye lids with pre auricular and submaxillary adenitis. skin rashes seen in secondary stage, gummatous tarsitis and nodules resembling chalazia forms on eye lid

Treatment :- Controling of the primary disease.

2) **Phthiriasis palpebrum :-** Eye lashes are covered with black nits of the pediculus pubis, eye lids become red and irritable

Treatment :-
1)Cleanliness at the lesion 2)Application of Ammoniated mercury.

3) **Vaccinia of the eye lids: -** a virus infection causes an ulcer covered with greyish exudate or crust at the lid margin with lymph adenitis.

4) **Herpes simplex or Febrilis :-**Occurs on the eye lids aswell as lips and nose, in the course of febrile affections.

5) **Herpes zoster ophthalmicus:-** Unilateral herpetic eruptions of the skin of eye lid along with the ophthalmic branch of Trigeminal nerve.

6) **Dermatitis of eye lid** :- inflammation of the skin of the eye lid which is spread from scalp, face etc.

Treatment :-

1) Cleanliness of the affected site
2) Controlling the peripheral lesions
3) Local application of hydrocortisone ointment.

7) Oedema of eye lids - It is due to

1) Trauma
2) inflammation
3) systemic - renal and cardiac disorders
4) Non inflammatory (angio neurotic oedema)

arises due to allergic causes, emotional factors and hormonal disturbances etc.

Sushruta's Classification of varthma roga

S.No.	Name of the disease			Treatment
	(Total disease s	=	21	
	Asadya	=	3	
	yapya	=	1	
	Ashastra Kruth	=	2	
	Shastra sadya	=	15	(9 Lekhan - 3 bhedan and 3 chedan sadya vyadhies)
1)	Vata hata varthma			Asadya
2)	Nimesha			
3)	Shonitarsha			
1)	Pakshma Kopa			Yapya
1)	Praklinna Varthma			Ashastra Krutha
2)	Aklinna Varthma			
1)	Utsangini			9 Lekhan Sadya vyadhies
2)	Kumbheeka			
3)	Varthma sharkara			
4)	Pothaki			
5)	Varthmaavabandha			
6)	Bahala varthma			
7)	Shyava varthma			
8)	Varthma Kardama			
9)	Klishta varthma			
10)	Lagana			3 Bhedan Sadya vyadhies
11)	Anjana namika			
12)	Bisa Varthma			
13)	Arsho varthma			3 Chedan sadya Vyadhies
14)	Shuska arsha			
15)	Arbuda			

Vagbhata's Classification of varthma roga

Total diseases	24
3 diseases	Asadya
1 "	Yapya
1 "	Aushada sadya (Ashastra Kruth)
19 diseases	shastra sadya

1)	Nimesha		3 - Asadya
2)	vata hatha Varthma		
3)	Varthma Arsha		
1)	Paksmopa rodha	-	1 Yapyam
1)	Krichronmeelan	-	1 Aushada sadyam
1)	Arbuda	-	1 Chedan
1)	Paksha shatha	-	1 Kuttana with needle like instrument
1)	Utsangini		6 diseases Bhedan sadya
2)	Anjana namika		
3)	Alaji		
4)	Bisa varthma		
5)	Lagana		
6)	Kumbheeka		
1)	Pothaki		11. Lekhan sadya Vyadhies
2)	Shyava varthma		
3)	Sikatha Varthma		
4)	Slista varthma		
5)	Kukunak		
6)	Babala varthma		
7)	Kardama varthma		
8)	Ithklista varthma		
9)	Pittoth Klista varthma		
10)	Kaphoth Klista varthma		
11)	Rakthoth Klista varthma		

DISEASES OF EYE LIDS (VARTHMA ROGAS)

S.No.	Name Modernname	Clinical features	Treatment Principle
1)	Utsangini (Chalazian or meibomian cyst)	One or multiple hard cysts commonly Originate in Lower eye lid, swelling Appears through the skin but pus point is internally, discharges egg yolk like secretion, occurs by the Vitiation of Tridoshas	1) Lekhan Sadya vyadhi 2) Pratisaran (chedana and Bhedana according to the condition)
2)	Kumbheeeka (zeis cyst or Stye)	Small papules resembling the seeds of pomegranate fruit develops at the lid margin, cyst discharges the pus and bulges again it occurs by the vitation of Tridosha (Sushruth), pitta dosha (Vagbhat)	1) Lekhan 2) Pratisaran 3) Sadya vyadhi
3)	Pothaki (Trachoma)	multiple follicles resembling Raktha sarshapa beeja, originates in varthma By the vitiation of **kapha dosha** (Su), follicles resembling swetha sarshapa originates in varthma (Vagbhata)	1) Lekhan 2) Pratisaran 3) Sadya vyadhi
4)	Varthma Sharkara (Lithiasis conjunctivae) or Varthma Sikatha (Vagbhat)	Multiple hard small follicles resembling sugar or sand particles develops in varthma, the bigger follicle is encircled by smaller follicles, it is Tridoshaja Vyadhi.	1) Lekhana 2) Pratisaran 3) Sadya vyadhi
5)	Arsho Varthma (A form of Trachoma)	Painful small rough follicles resembling Ervaru beeja, develop in eye lid by the Vitiation of **Tridosha** (Sushruth), **Rakta** (Vagbhat)	1) Chedana 2) Pratisaran 3) Sadya vyadhi
6)	Shuska arsha (Polyp of the Palpebral conjunctiva)	A lengthy hard rigid polyp develops in the internal surface of eye lid by the Vitiation of Tridoshas	1) Chedan 2) Pratisaran 3) Sadya vyadhi

7)	Anjana namika (Stye or zeis cyst)	Small red coloured follicles originates in the eye lid with pain burning sensation by the vitiation of **Raktha dosha**	1) Bhedana 2) Pratisaran 3) Sadya vyadhi
8)	Bahala Varthma (multiple Chalazia)	Hard same coloured same sized papules Originates in the eye lid, make it thicker by the vitiation of **Rakta dosha**	1) Lekhana 2) Pratisaran 3) Sadya vyadhi
9)	Varthma bandha (imperfect Closure of eye lid due to oedema)	Imperfect closure of eye lid due to Varthma shopha, associated with itching and slight pain, it occurs by the vitiation of **Tridoshas**	1) Lekhana 2) pratisaran 3) Sadya vyadhi
10)	Klista varthama (Allergic conjunctivitis)	The eye lids suddenly become soft, red and painful by the vitiation of **rakta (Rakta + Kapha)** dosha	1) Avoid the cause 2) Pracchana 3) Lekhana 4) Pratisaran 5) Sadya vyadhi
11)	Kardama Varthma (inflammed eye lid with Conjunctivitis)	klista varthma get burnt by pitta dosha and causes more exudation than klista Varthma . The vitiated doshas are **Rakta Kapha and pitta**	1) Lekhan 2) Vrana Chikitsa 3) Abhishyanda Chikitsa 4) Sadya Vyadhi
12)	Shyava varthma (Inflammed eye lid)	Eye lid becomes black due to **Tridosha vitiation,** clinical features are pain, burning, itching and oedema	1) Lekhana 2) Pratisaran 3) Sadya vyadhi
13)	Praklinna Varthma (Allergic Conjunctivitis)	Painless swelling of the eye with Itching sensation and sticky exudation It occurs by the vitiation of **Kapha dosha**	1) Ashastra kruta 2) Kaphaj Abhishyand aushada Chikitsa
14)	Aklinna Varthma (Ankylo-blepharm Symblepharon	Though there is no inflammation, no discharge and the eye lids are cleaned, the lids sticks together, it is by the Vitiation of **Tridoshas**.	1) Ashastrakrutha 2) Abhishyanda Aushada chikitsa

15)	Vata hata varthma (Logophthalmos, Ptosis)	Due to vitiated **vata** the apanga, the Kaneenika and varthma shukla sandhies are paralised and causes difficulty in opening and closing the eye lids	1) Asadya
16)	Varthma arbuda (Benign tumour)	A painless, irregular red cystic swelling developed by hanging from the internal surface of eye lids, by the vitiation of **Tridoshas**	1) Chedan 2) Pratisaran 3) Sadya vyadhi
17)	Nimesha (Blinking of eye lids)	Vitiated **vata** enters the nimeshani siras, sandhies of varthma and causes pain less abnormal movement of eye lids	Asadya
18)	Shonitharsha (carcinoma of eye lid)	Raktaj or vata raktaj disorder in which a red, soft - granulation tissue develops in varthma, recurs even after excision	Asadya
19)	Lagana (Chalazian or meibomian cyst)	A small cystic swelling resembling kola phala, develops in eye lid, which is hard stout, pain less, sticky with itching sensation, by the vitiation of **kapha dosha**	1) Bhedan 2) Pratisaran 3) Sadya vyadhi
20)	Bisa varthma (Porous oedema of eye lid)	Due to tridosha vitiation the eye lid inflammes and causes multiple small holes, like in pot through which inflammatory exudates oozes.	1) Bhedana 2) Pratisaran 3) Sadya vyadhi
21)	Pakshmakopa (Trichiasis with entropion)	The vitiated tridosha vitiate the roots of cilia and causes the eye lashes hard sharp and misdirected with inverted lidmargin, causes injury to cornea	1) Aushada Chikitsa 2) shastra Karma 3) Agnikarma 4) Ksharakarma 5) Yapya vyadhi

शुक्लगत रोग

अर्म

प्रस्तारि शुक्ल क्षतजाधिमांस - स्नायर्म संज्ञाः खलु पंच रोगाः।
स्युः शुक्तिका चार्जुनापिष्टको च
जालं सिराणां पिड़काश्चयाःस्युः ॥
रोगा बलासग्रथितेन सार्ध
मेकादशम्श्णोः खलु शुक्लभागे ॥ (सु॰ उ॰ 4/3 अ॰)

1. प्रस्तारि अर्म

प्रस्तारि प्रथितमिहार्म शुक्लभागे
विस्तीर्णं तनु रुधिरप्रभं सनीलम् ॥ (सु. उ. 4 अ:)

मृद्वाशुवृद्ध्यरुङ् मांसं प्रस्तारि श्यावलोहितम् ॥
प्रस्तार्यर्म मलैः सास्रैः (अ॰ हृ॰ उ॰ १० अ:)

2. शुक्लार्म

शुक्लाख्यं मृदु कथयन्ति शुक्लभागे
सश्वेतं सममिह वर्धते चिरेण। (सु उ 4/4)

कफात्शुक्ले समंश्वेतं चिरवृद्ध्यधिमांसकम्।
शुक्लार्म (अ:हृ:उ:१०अ:)

3. लोहितार्म या क्षतजार्म

यन्मांसं प्रचयमुपैति शुक्लभागे
पद्माभं तदुपदिशन्ति लोहितार्म ॥ (सु॰ उ॰ 4/5)

शोणितार्म समं श्लक्ष्णं पद्माभमधिमांसकम् ॥ (अ:हृ:उ:१०अ:)

4. अधिमांसार्म

विस्तीर्णं मृदु बहलं यकृत्प्रकाशं
श्यावं वा तदधिकमांसजार्म विद्यात् ॥ (सु॰ उ॰ 4/6)

शुष्कासृक्पिण्डवच्छयावं मन्मांसं बहलं पृथु॥
अधिमांसार्मतद् (अ:हृ:उ:१०)

5. स्नाय्वर्म

शुकलेयत् पिशितमुपैति वृद्धिमेतत्
स्नाय्वर्मेत्यभिपठितं खरं प्रपाण्डु॥ (सु॰ उ॰ 4/6 अ॰)

स्नावार्म स्नावसन्निमम् ॥ (अ:हृ:उ:१०)

6. शुक्तिका या शुक्ति

श्यावाः स्यु : पिशितनिभाश्च बिन्दवो ये
शुक्तयाभाः सितनयने स सुक्तिसंज्ञः ॥ (सु॰ उ॰ 4/7 अ॰)

पित्तं कुर्यात् सिते बिन्दुनसितश्याव पीतकान्॥
मलाक्तादर्शतुल्यं वा सर्व शुक्लं सदाहरुक्।
रोगोयं शुक्तिकासंज्ञः सशकृद्भेदतृड्ज्वरः ॥ (अ:हृ:उ:१०)

7. अर्जुन

एको यः शशरुधिरोपमस्तु बिन्दुः
शुक्लस्थो भवति तमर्जुनं वदन्ति॥ (सु॰ उ॰ 4/8 अ:)

नीरुक् श्लक्ष्णोर्जुन बिन्दुः शशलोहितलोहितः (अ:हृ:उ:१०अ॰)

8. पिष्टक

उत्सन्नः सलिलनिभोथ पिष्टशुक्लो बिन्दुर्यो भवति सपिष्टकः सुवृतः ॥ (सु॰ उ॰ 4/8 अ॰)

बिन्दुभिः पिष्टधवलैरुत्सन्नैः पिष्टकं वदेत् । (अ:हृ:उ:१०अ:)

9. सिराजाल

जालाभः कठिनसिरो महान् सरक्तः
सन्तानः स्मृत इह जालसंज्ञितस्तु ॥ (सु॰ उ॰ 4/8)

सिराजाले सिराजालं बृहद्रक्तं घनोन्नतम् (अ:हृ:उ:१०अ:)

10. सिरापिड़िका

शुक्लस्याः सितपिड़काः सिरावृता या-
स्ता विद्यदसितसमीपजाः सिराजाः ॥ (सु॰ उ॰ 4/9 अ॰)

तद्दाह-घर्षवन्ताः सिरावृताः
कृष्णासन्नाः सिरा संज्ञा पिटिका सर्षपोपमाः (अ:हृ:उ:१०अ:)

11. बलासग्रथित

कांस्याभो भवति सितोम्बुबिन्दुतुल्य
स ज्ञेयोमृदुररुजो बलासकारख्यः ॥ (सु॰ उ॰ 4 अ॰)

शोफस्त्वरुजः सवर्णोवहलोमृदुः
गुरुःस्निग्धोम्बुबिन्द्वा भो बलासग्रथितं स्मृतम् ॥ (अ:हृ:उ:१०अ:)

DISEASES OF SHUKLA MANDALA

(Diseases of sclera and bulbar conjunctiva)

11 diseases according to Sushrutha,
13 " " " Vagbhata.

they are

1) Prasthari arma
2) Shukla arma
3) Kshathaja arma
4) Adimamsa arma
5) Snayu arma

-5 types of arma.

6) Shukthika
7) Arjuna
8) Pistaka
9) Sira jala
10) Sira pidaka
11) Balasa graditha. **(Sushrutha)**

1 to 11 are common according to Sushrutha and Vagbhata, the other extra two diseases of Vagbhata are

12) Sirothpatha 13) Sira harsha.(But these 2 Diseases are explained by Sushrutha in Sarvagatha rogas.)

ARMA (PTERIGIUM)

" Iyarthi gacchathi ithi Arma "

The Gradually spreading extra membrane in shukla mandala (Mamsa Vruddhi) is Known as Arma

It is of 5 types, they are
1) Prasthari arma 2) Shukla arma 3) Kshataja Arma 4) Adimamsa arma 5) Snanu arma

1) PRASTHARI ARMA {progressive Pterigium}

It is sannipathaja, chedana sadya, vyadhi in which spreading type of membrane formed on shukla mandala

Sushrutha :-Thin spreading, Reddish blue coloured membrane formed in shukla mandal
Vagbhat :- a soft, quickly spreading, blackish, red, painless membrane formed by the vitiation of tridosha and Raktha dosha

Treatment :- Chedan sadya vyadhi (Excision of the arma)

2) SHUKLA ARMA :- (progressive Pterigium)

It is kaphaja chedan sadya vyadhi, in which a slowly growing, soft pale white coloured membrane develops on shukla mandala.

Treatment :- Chedan (Excision) Sadya vyadhi

3) KSHATAJA ARMA OR LOHITARMA OR SHONITHARMA (pterigium- Melanoma - Haemangioma)

It is raktaja chedan sadya vyadhi, in which soft red coloured membrane (Resembling the colour of Lotus flower) Develops on shukla mandala

Treatment: - Chedan (Excision) Sadya vyadhi

4) ADHIMAMSA ARMA

It is sannipathaj chedan sadya vyadhi in which a soft thick widely spreading chocolate coloured (yakruth varna) membrane develps on shukla mandala

Treatment : - Chedan (Excision) Sadya vyadhi

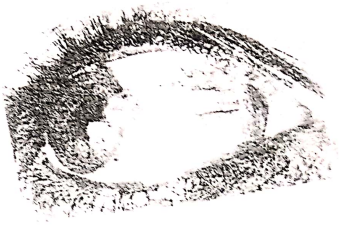

Pterygium

Pterygium - progressive stage.

Pinguecula

5) SNAYU ARMA

It is sannipathaja chedan sadya vyadhi in which a hard wide yellow coloured membrane resembling "Snayu" develops in shukla mandala.

Treatment :- Chedan (Excision) Sadya vyadhi

Note :- Among 5 types of Arma

a) Snayu arma and adhimamsaja arma are thicker wide with snayu and mamsa so chedana is advised b) But prasthari shukla kshataj arma are advised to treat with Lekhana anjanas as like in Avrana shukla or lekhana therapy for having thin and smaller membrane development on shuklamndala in white or blue or red or in brown colour.

1) In thin membranous Arma - Lekhana Therapy (Prasthari, Shukla, and Kshataja arma 2) Thick fibrous membranous arma (Adhimamsa and Snayu Arma) has to do.

Indications of Arma Chedan

1) Thicker wider spreading type of Arma
2) Arma like the thick Skin
3) When spreading on to the krishna mandala
4) Snayu and mamsaja Arma
5) When arma not responding to Lekhana theraphy

Poorva Karma to Arma Chedan
(Pre excision regimen of Arma)

1) Snena and sweda karma
2) Sharear shodhan (Vaman, Vrechan, vasti etc.)
3) Shiro Shodhan by Nasya Karma
4) Giving of oleus substances to eat or drink
5) Lavan pratisaran to disintegrate the tissue of the arma.

Pradhan Karma (Method of excision therapy)
Patient is asked to see towards Apanga (outer canthus) and eyelids should open widely
1) Sthanika mrudu sweda (Local light fomentation)
2) Separation of arma from the floor with Badisha (Hook)
3) Clear separation of Arma from the floor with a thread
4) Elevation of Arma with muchundi (forceps)
5) Arma is separated and cut at the krishna mandala then the flap is lifted to wards kaneenika sandhi and 3/4 th part is cut with mandalagra shastra by leaving the 1/4 th part as residue to prevent from the complications like Nadivrana Raktha srava Drustinash etc.

The residue should be scraped with the application of lekhan anjanas, afterwards .

Pashchath karma (post excision regimen) :-
1) Pratisaran with yavakshar, shunthi, maricha, pippali and lavan
2) Mrudu sweda
3) Ghritha sechan
4) Cheen bandan (eye bandage)
5) After 3 to 5 days bandage should open to observe the healing process
6) Vrana ropan chikitsa (wound healing therapy)
7) Treatment of the complications, if any..

After the excision of arma if pain is associated that should be treated with medicated milk prepared with 1) Aamalaki, yastimadu and milk Honey Aashchyotan has to do.

1) The decoction of karanja beeja as eye drops)
2) Application of (Shiro and netra lepa) yastimadu + Kamal Kesar + milk + ghee
3) The residual Part of Arma should be scraped by the application of Lekhana anjanas

Signs of Proper excision:-
1) Getting of Normal colour and vision.
2) Painless Movements of eye ball
3) Relief from pain, oedema, ulceration, discomfort and other inflammatory signs and symptoms.

Aushadhi Chikitsa of arma :-

(Prasthari arma, shukla arma and Kshataja arma)

1) All the lekhana anjanas mentioned for Avrana shula
2) Krishnadi puta Paka :- Maricha, Loharaja, Tamra, shankha, vidruma, saindhava lavan, srotoanjan kaseesa + Dadhi.
3) Pippalyadi gutikanjan :- Pippali, triphala ,laksha, Lohachurna, Saindhava lavan + Brungaraja swarasa
4) Marichadi lepa - maricha, Vibheetaki + Haridra swarasa
5) Pushpadi rasakriya - yashada pushpa, rasanjan, sita, dadhi, samudra phena, Shankha, saindhava lavan, gyrika, manashila, maricha + madhu.

Arma can be compared to the pterigium, a disease that occurs due to sub conjunctival degeneration, in which a triangular layer develops underneath the bulbar conjunctiva towards cornea in Horizontal meridian, develops either form inner canthus or outer canthus and spreads towards cornea.

Psuedo Pterigium	Pterigium
1) Inflammatory lesion	1) Degenerative lesion
2) Probe can be passed underneath the membrane	2) Probe Cannot be passed
3) Can develop in any Meridian	3) Develops only in Horizontal meridian
4) Stationary	4) Stationary or progressive
5) Can occur in any age	5) only in adults

Pterigium :-

It is a triangular fold of Conjunctiva, encroaching the cornea in the horizontal meridian, in the palpebral fissure, either from the nasal side or from the temporal side of the bulbar conjunctiva or from both the sides It is due to degenerative changes in the subconjunctiva tissue

It consist of head, neck and a body

Types :- a) Progressive pterigium 2) Non Progressive pterigium or Atrophic Pterigium

Progressive pterigium progresses in the cornea in the level of Bowman's membrane, which is destroyed.

b) Atrophic or Non- progressive pterigium. It is very thin with little vascularity, doesn't spread upto cornea (Stationery)

Symptoms :- No symptom appears unless it reaches the pupillary area. Occasionally there may be diplopia due to restricted movements of eye ball (Slight discomfort may present).

Treatment of pterigium :-

Stationary pterigium require no treatment, but in progressive pterigium surgery is conducted (1) Mc Reynold's transplantaion method (2) Excision of entire pterigium . (The Residual part is turned to 6 clock position and mattress suÿÿves are given to control the recurrence)

6) SHUKTHIKA OR SHUKTHI
(Xerosis or xerophthalmia)

It is pittaja Aushada sadya Vyadhi, Shukla mandala is spread with blackish white (shyava varna) Patches or dots, like in jala shukthi.

Vagbhata has given little more description as follows :

1) Eye appears dirty as the mirror with dust particles. 2) Blackish white or yellowish dots spread in shukla mandal.3) The Patient have pain, burning sensation in the eye and also associate with diarrhoea thirst and fever

Treatment :

1) It is Ashastra krutha vyadhi (has to treat with medicines only)
2) It should be treated like pittaja Abhishyanda vyadhi or Amladyushitha
3) The treatment principle is oral a) administratin of Triphala ghritha or Tilwak ghritha or purana ghritha for Virechana, b) Application of sheeta Anjanas like

a) Vydoorya, spatika, pravala, muktha, shankha, Raupya, swarna bhasma (Anyone or few of) + madhu as Anjanam. b) phalasha pushpa swarasa + Honey c) Rasakrianjan with yastimadu, Daruharidra and Rasanjan d) Lodra Drakha, Sharkara, kamala, yastimadu + Stanya e) Samudraphena + stanya f) Amalaki phala swarasa + ghritha g) Rasanjan + Stanya or madhu or ghritha

XEROSIS OR XEROPHTHALMIA
(Shukthika)

It is a degenerative condition characterised by dry lustreless condition of conjunctiva.

Causes :-

1) Local diseases of conjunctiva, ex trachoma, pemphigus, membranous conjunctivitis, Extensive burn of conjunctiva
2) Chronic exposure of Conjunctiva to dust and smoke due to Lagophthalmos, ectropion etc.
3) Nutritional diisturbances - especially Vitamin A deficiency
4) Exposure to chemicals, toxins etc.

Note :-

If it is neglected it may cause kerato malacia (degeneration of Corneal epithelium) corneal ulcer, Panophthalmitis etc.

Treatment ;-

1) Liquid paraffin drops in eyes 2) Improvement of general health
3) Oral administration of vitamin A through food or medicines
4) Deep intra muscular injection of vit. A 100000 units once a week (according to the neccssity)

7) Arjuna

(Sub conjunctival haemorrhage or mole or melanoma)

It is rakthaja Sadhya vyadhi in which red coloured dot or patch (Red colour as the blood of rabbit) Originates in shukla mandala.

Vagbhata : - Description is same as above but added the following words, soft painless red coloured dot in shukla mandala. (mole-melanoma commonly congenital - No need of treatment, traumatic lesions of conjunctiva like sub conjunctival haemorrhage, hamangioma need treatment

Treatment :-

1) Ashastra Kruth (Should treat with medicines only)
2) Traumatic subconjunctival haemorrhage naturally disappears within 7 days.
3) should treat like pittaja or Rakthaja Abhishyanda

4) Seka or Anjana:- With Ikshurasa, madhu, sugar, ksheera, Rasanjan, Yastimadhu, Saindhava lavana (few of the drugs.)

5) Aaschyotan :-

Sugar, Yastimadhu, madhu, sour things Nimburasa, saindhavalavana, Badari phala, Amla, Dadima (with few of the drugs)

6) Anjanas :-

a) Shankha + Sugar + madhu + Samudra phena.
b) Shankha or spatika or pravala or yastimadhu + madhu.
c) Rasanjan + madhu
d) Kaseesa + madhu
e) Saindhava lavana + madhu + Nirmali phala
f) Lekhana Anjanas.
g) Samudraphena, swetha maricha, manashila + mathulunga swarasa.
h) Kukkutanda twak, Lashuna,Trikatu, Ela, Karanja, beej.

8) PISTAK (Pinguecula)

It is Kaphaja Sadhya vyadhi in which shukla mandala is spread with white round and fresh papules (nodular eruptions, whitish like Rice flour and fresh like water) (Bhava Mishra described, it is due to kapha + vata vitiation)

Treatment :

1) Ashastrakrutha vyadhi. (Should be treated with medicines only)
2) Treatment can be given like kaphaja Abhishyanda Vyadhi except Raktha mokshana therapy.

3) Mahaushadadi Anjan:- Prepared with Shunti, pippali, musta, swetha maricha, saindhava lavana (equally) and grinded with mathulunga swarasa.
4) Kantakari (Varthaka) or shigru or Indravaruni or patola or kirathatiktha, or amalaki.

Any of the above durgs (fruits) after pakwa, the seeds should be removed and fill the fruit capsule with pippali and sauveeranjan. Kept it for 7 days after that the medicine should be collected and grinded with mathulunga rasa and used as Anjana.

9) SIRA JALA

(Haemangioma of the sclera or scleral staphyloma or congestion)

It is rakthaj chedan sadya vyadhi in which a hard big red coloured capillary net appears in shukla mandala, is known as siraajala

Treatment:-

Like Arma Vyadhi

a) In soft thin Smaller capillary net treatment is application of the Lekhan anjana or lekhana therapy.b) In Hard thick bigger Capillary net, Treatment is chedan and pratisaran Like in **"Arma"** (3/4th part should cut with mandalagra shastra and the residue (1/4) Should treat by the application of Lekhan anjanas).

10 SIRA PIDIKA (EPISCLERITIS - SCLERITIS)

It is sanni pathaja chedan sadya vyadhi, in which a white nodule encircled with capillary net is seen near the Krishna mandal (Limbal area) - (Sushrutha).

A nodule (resembling the Sarshapa beeja) encircled with capillary net is observed near krishna mandalam. Associated with Burning and foreign body sensation (Vagbhata)

Treatment :- Like sirajala (Like Arma)

BALASA GRADITHA

(Pinguecula, episcleral Rheumatoid nodule, parinauds conjunctivitis)

It is kaphaja Aushada sadya vyadhi, in which a hard painless nodule resembling the water bubble and shines like the bronze (kamsya) originates in shukla mandala (Sushrutha)

According to videha it is due to vitiation of kapha and vata dosha

Treatment :-

1) Ashastra krutha (Surgery is contra indicated) 2) Shareera shodhana (Vaman virechana etc.) and shiro shodhan (Nasya) 3) Application of the following kshara anjana a) Apakwa yava get bhavana in milk for 7 days get dried and should prepare kshara, then add saindhava lavan, tuttha and gorochana, get pakwam and use as anjan, b) Arjaka, asphotha, kapitta, bilwa nirgundi jathi pushpa - prepare kshara and add saindhava lavana, tuttha and gorochan, use as anjan c) Phaninjakadi kshara anjan.

EPISCLERITIS (Sirajala - sirapidika)

It is the inflammation of sub conjunctival episclera along with the superficial lamellae of sclera

Etiology :- 1) Associate with Rheumatoid arthritis , endogenous toxins allergic reactions like in tuberculosis.

Symptoms :- 1) Pain and discomfort in the eyes.
2) No discharge lacrimation and photophobia

Signs :- 1) A hard pinkish nodule develops sub conjunctivally, 2 to 3 mm away from the limbus

2) Nodule is tender and deeply fixed, never ulcerates.

3) Hyperaemia of the surrounding conjunctiva.

Complication - (1) Scleritis (2) Uveitis

Treatment :

1) Hydrocortizone acetate 1% drops and sub conjunctival injections (once in a week)
2) Elimination of septic focus.

DIFFERENTIAL DIAGNOSIS

	Episcleritis	Phlycten	Inflammed Pinguecula
1) Age	Elderly person	Young	Elderly person
2) Location	Away from the Limbus.	on the Limbus.	Away from Limbus, in Horizontal meridian
3) Tender ness	Present	Absent	Present
4) Ulceration	Absent	Present	Absent
5) Appeare nce	Pinkish Red.	Pinkish White	Pinkish white

SCLERITIS (Sirajala - Sira Pidika)

The inflmmation of the sclera is known as scleritis.

Etiology : -1) Toxic & allergic influences(Tubercular - Bacterial, septic focus)
2) Endogenous infections :- T.B, Syphilis, leprosy - Viral infection etc.
3) Secondary infections from pericular or intra ocular tissues
4) Exogenous infection ex :- conjunctival lesions.
5) Systemic & metabolic ex :- Rheumatoid arthritis.

Pathology :- marked infiltration of scleral Lamellae with lymphocytes and necrosis of the scleral fibres with ultimate thining of the sclera.

Symptoms - 1)Marked pain may radiate to the frontal region.
2) Lacrimation but no discharge.

Sign :-1) Pinkish red area with hyperaemia of surrounding conjunctiva.
2) The patch of scleritis is slightly elevated and markedly tender

Complications : - 1) Tongue shaped corneal opacity
2) Uveitis 3) Ciliary staphyloma.

Treatment : - Same as episcleritis.

Pinguecula :- Pistaka - Balasa graditha

This is a small raised yellowish white nodule occur in the bulbar conjunctiva, in the horizontal meridian, a little distance away from the limbus either on temporal or nasal sides

It may be due to chronic Exposure to dust and smoke Histologically it consist of proliferated elastic tissue undergoing degenerative changes

No symptom except slight discomfort

Treatment : - Not Required

Diseases of shukla mandal by Sushrutha

Total diseases = 11
1) Aushada sadya (Ashastra kruth) = 4
2) Shastra sadya - 7

S. No.	Name of the disease	Treatment
1 2 3 4	Shuktika Arjuna Pistaka Balasa Graditha	Aushada Sadyam (Ashastra Kruth)
1 2 3 4 5 6 7	Prasthari arma Shukla arma Kshathaja arma Adimamsa arma Snayu arma Sirajala Sira Pidika	1) Lekhan/Chedan 2) Pratisaran

Diseases of shukla mandal by Vagbhat

Total diseases = 13
1) Aushada Sadya = 6
2) Shastra Sadya = 7

1 Shuktika
2 Arjuna
3 Pistaka
4 Balasa graditha
5 Sirothpatha
6 Siraharsha
} Aushada Sadya (Ashastra Kruth)

1
2
3
4
5
6 - 5 types of Arma
} Chedan Pratisaran

7 Sira jala
Sira Pidika

Diseases of Shukla mandala

No.	Name of the disease Modern name	Main features	Treatment Principle
1)	Prastran arma (pterigium)	It is **sannipataj** vyadhi in which a thin, spreading reddish blue coloured membrane forms on shuklamandal (Sushrutha) soft, Spreading pain less blackish red membrane form on shukla manda (vagbhata)	Sadya vyadhi 1) Lekhan Pratisaran if not 2) Chedan pratisaran
2)	Shukla arma (Pterigum)	It is **kaphaj** vyadhi in which A slowly growing, soft, pale white coloured membrane develops on shuklamandal	Sadya vyadhi 1) LekhanPratisaran if not 2) Chedan-prati Saran
3)	Kshataja arma or Shonita arma or Lohita arma (Pterigium)	It is **Raktaja** vyadhi, in which a soft, red coloured membrane resembling the colour of of lotus develops on shukla mandala.	Sadya vyadhi 1) Lekhan, pratisaran 2)Chedan, Pratisaran
4)	Adhimamsa arma (pterigium)	It is **sannipataj** vyadhi in which A soft, thick, widely spreading, chocolate coloured membrana (yakruth varma) develops on shukla Mandala.	sadya vyadhi Chedan, pratisaran
5)	Snayu arma (Pterigium)	It is **sannipataj** vyadhi in which a hard, wide, yellow coloured membrane resembling the snayu develops in shukla mandal	Sadya vyadhi Chedan, Pratisaran
6)	Shuktika (Xerosis)	It is **Pittaja** Vyadhi in which Blackish white patches or dots (like in jala shukti or mirror with dust particles spreads in shukla mandala with pain burning and discomfort.	1) Ashastra kruth 2) Pittaja abhish yanda chikitsa 3) Sheeta anjanas 4) Sadya vyadhi

7)	Arjuna (Sub conjunctival haemorrhage, Mole, or melanoma)	It is **Raktaja** vyadhi, in which Red coloured dot or patch Originates in Shuklamandal (Red colour as the blood of rabbit)	1) Sadya Vyadhi 2) Ashastra Kruth 3) Pittaja or Rakta Abhisyandi Chikitsa.
8)	Pistaka (Pinguecula)	It is Kaphaj vyadhi in which shukla mandala is spread with white, round, fresh papules (Whitish like rice flour, fresh like water)	1) Sadya vyadhi 2) Ashastra kruth 3) Kaphaja abhisyanda Chikista
9)	Sirajala (Haemangioma of sclera or scleral staphyloma)	It is **Raktaja** vyadhi in which a A hard, big, red coloured capillary net seen in Shukla mandala.	1) Sadya vyadhi 2) Like Arma 3) Chedan, Pratisaran
10)	Sira pitica (episcleritis)	It is **Sannipataj** vyadhi in which a white nodule encircled with capillary net is seen in shukla Mandala.	1) Sadya vyadhi 2) Like Arma 3) Chedan, Pratisaran
11)	Balasa graditha (Pinguecula)	It is **Kaphaja** vyadhi in which a hard, painless nodule, resembling the water bubble, shining like bronze originates in shukla mandala.	1) Sadya vyadhi 2) Ashastra Kruta 3) Application of kshara Anjanas.

कृष्णगत रोग

सव्रणशुक्ल

निमग्नरूपं हि भवेत्तु कृष्णे सूच्येव विद्धं प्रतिभाति यद्वैव।
स्रावं स्रवेदुष्णमतीव रुक् च तत् सव्रणंशुक्लमुदाहरन्ति॥

(सु॰ उ॰ 5/4 म॰ अ॰)

सव्रणशुक्ल की साध्यासाध्यता

दृष्टेः समीपे न भवेत्तु यस्य न चावगाढ़ं न च संस्रवेद्धि।
अवेदनावन्न च युग्मशुक्रं तत् सिद्धिमाप्नोति कदाचिदेव॥
विच्छिन्नमध्यं पिशितावृतं वा चलंसिरासक्तमदृष्टिकृच्च।
द्विवत्वग्गतं लोहितमन्ततश्च चिरोत्थितं चापि विवर्जनीयम्॥
उष्णाश्रुपातः पिडका च कृष्णे तस्मिन् मुद्गनिभंच शुक्रम्।
तदप्यसाध्यं प्रवदन्ति केचिद् अन्यच्च यत्तित्तिरिपक्षतुल्यम्॥

(सु॰ उ॰ 5/5,6,7)

पितं कृष्णेथवादृष्टौ शुक्रंतोदाश्रुरागवत्।
छित्त्वा त्वचं जनयति तेन स्यात् कृष्णमण्डलम्।
पक्वजम्बुनिभं किंचित् निम्नं च क्षतशुक्रकम्॥
तत् कृच्छ्रसाध्यं याप्यं तु द्वितीयपटलव्यधात्।
तत्र तोदादि बाहुल्यं सूचीविद्धाभकृष्णता॥
तृतीयपटलच्छेदादसाध्यं निचितं त्रपैः॥

(अ॰हृ॰उ॰१०अ॰)

अव्रणशुक्र

सितं यदा भात्यसितप्रदेशे स्यन्दात्मकं नातिरुगाश्रुयुक्तम्।
विहायसोवाच्छमनातुकारि तदव्रणं साध्यतमं वदन्ति॥
गम्भीरजातं बहलं च शुक्रं चिरोत्थितं चापि वदन्ति कृच्छ्रम्॥

(सु॰ उ॰ 4/8 अ॰)

शुक्लशुक्लं कफात् साध्यं नातिरुक् शुद्धशुक्रकम्।

(अ॰हृ॰उ॰१०अ॰)

अक्षिपाकात्यय

संच्छाद्यते श्वेतनिभेन सर्वं दोषेण यस्या सितमण्डलं तु॥
तमक्षिपाकात्ययमक्षिकोपसमुत्थितं तीव्ररुजं वदन्ति॥

(सु॰ उ॰ 1/9 अ॰)

दोषैः सास्रैः सदृक् कृष्णं नीयते शुक्लरुपताम्॥
धवलाम्रोपलिप्ताभं निष्पावार्धदलाकृति॥
अतितीव्ररुजारागदाहश्वयथुपीडितम्
पाकात्ययेन तच्छुक्रं वर्जयेत्तीव्रवेदनम्॥

(अ॰हृ॰उ॰१०अ॰)

अजकाजात

अजापुरीषप्रतिमो रुजावान् सलोहितो लोहितपिच्छिलाश्रुः
विदार्य कृष्णं प्रचयोभ्युपैति तं चाजकाजातमिति व्यवस्येत्॥

(सु॰ उ॰ 1/10 अ॰)

आताम्रपिच्छिलासस्रुदाता म्रपिटिकातिरुक्।
अजाविद् सदृशोच्छ्रायकण्डिया वर्त्मसृजाजका॥

(अ॰हृ॰उ॰१०अ॰)

DISEASES OF KRISHNA MANDALA

(Diseases of cornea and iris)

A) According to Sushruth 4 Diseases	)(	B) According to Vagbhata 5 Diseases
1) Savrana shukla (Shukra)	)(	1) Kshatha Shukla
2) Avrana Shukla (Shukra)	)(	2) Shuddha Shukla
3) AjakaaJatha	)(	3) Ajaka
4) Akshi Pakathyaya	)(	4) Pakathyaya Shukra
		5) Sira Shukra.

1, 2, 3, 4, of Sushrutha and vagbhata are same but wording difference, The 5th disease of Vagbhata is the part of savrana shukla of Sushrutha . So the both classifications are merely same.

1) SAVRANA SHUKRA (SUSHRUTHA) (KSHATA SHUKRA (VAGBHATA) (ULCER CORNEA OR ULCERATIVE KERATITIS)

It is Rakthaja Asadhya Vyadhi (Sushrutha),
Pittaja Kasta sadhya vyadhi (Vagbhata)

Note : - (When doshas vitiate 3 rd patala of krishna mandal it becomes Asadhya) (Vagbhata)

Description : - The krishna mandala is vitiated (injured) form a small, round ulcer, with severe pain (as pierced by needle) and hot lacrimation.

1) The word Succhyeva Viddham is not only applicable to the nature of the pain (Suchividdha vath Shoola), But also to the shape of the ulcer (small, rounded pin pointed as pricked by the needle)

2) The Word **nimaghna rupam** donotes the inflammatory condition of krishna mandala in which it appears as dipped, or sunken

3) Ushnashrutha :- Discharges more hot lacrimation

4) Ateeva ruk :- With severe untolerable pain Vascularisation of cornea

5) Raktha rajinibham:- as a complication (Videha).

6) Because of inflammatory process, krishna mandala appears in red colour like pravala (videha), pakwa jambhuphala (Vagbhata)

7) The stages of the disease explained as

I) a) Utthana (simple superficial lesion) (b) Avagadha deep lesion) by sushrutha

II)	a) Vitiation of	Pradhama patala	-	Kasta Sadhyam
	b) " "	Dwitheeya patala	-	Yapyam.
	c) " "	Truteeya patala	-	Asadhyam

by " Vagbhata "

8) According to vaghata the severity of the disease increases by the progression of disease from Ist to IIIrd patala and become more complicated.

Sadhya Asadhyatwa of Savrana Shukla (Prognosis)

Sadhyam	Asadhyam
1) Vranam which is not nearer to drusti (not nearer to central cornea in which refractive media is not obsructed).	1) Vranam near to drusti (Central corneal opacity, refractive media will be obstructed)
2) Na avagadham (Uthana). not deeply spreaded or if pradhama patala (epithelial layer) only affected	2) Avagadham (deeply spreaded ulcer, if affects 2nd and 3rd patala i.e., stroma and endothelium)
3) Ashru srava rahitham (no Lacrimation)	3) Ashru srava Sahitham (with lacrimation)
4) Avedna (No pain)	4) Ativedanam (more pain)
5) Single ulcer	5) Multiple ulcers
6) Cornea if not perforated	6) cornea if perforated
7) No Iris prolapse	7) with Iris prolapse
8) Non Spreading ulcer	8) Spreading or serpiginous ulcer.
9) Sira rahitham (Avascular)	9) Sira yuktham (Vascularised)
10) Prakrutha Varnam(Transparent)	10) Vikrutha Varnam (Opacities)
11) Pitikaa rahitham (No extra growth)	11) Pitica yuktam (phlyctenular kerato conjunctivitis.)
12) Shotha rahit (Non inflammed)	12) Shotha yuktham (inflammed)

SIRA SHUKLA (A.H.)

It is explained by vagbhata as 5th disease of krishna mandala (4 common according to Sushrutha & Vagbhata). The symptoms of this disease are explained by Susrutha in savrana Sukra only.

It is due to the vitiation of 4 doshas (Tri doshas + Raktha), in which the Krishna mandalam is vascularised (Sira yuktha Shukram), signs and symptoms are toda (Pricking pain),Daha (Burning), sirajala (formation of cillary net on cornea) discharge of sheetha or ushna, swaccha or gadha ashru (tears), without specific cause

Treatment :-If the vision is not obstructed treatment should be given like Savrana shukara.

Vishista anjana :- Should prepare with pundareeka yastimadu Kakoli, simhee, loha, Haridra, rasanjan. The drugs should grinded with goat milk and has to fumigate with yava or Aamalaki patra by dipping in ghritha, should prepare for Anjana.

2) AVRANA SHUKLA or SHUDDHA SHUKLA
(Non ulcerated Keratitis, Corneal Opacities)

The word Avrana Shukra used by Sushrutha and shuddha shukra by vagbhata.
Rakthaja Sadhya vyadhi. (Sushrutha)
Kaphaja Sadhya vyadhi. (Vagbhata)

Avrana shukla is discribed as secondary to Abhishyanda vyadhi (Syandaathmakam), in which a part of Krishna mandala become white (a) like the thin fresh clouds in the sky (SU), b) like shankha, c) like shankha chandra kunda pushpa and thin fresh clouds (Madhava Kara).

Patient have negligible pain and Lacrimation (Burning sensation also present Madhavakara).

It is sadhya vyadhi But may Become Krichra sadhya when the disease is deeply spreaded (Gambheera), widely spreaded (Bahala) and long standing (Chirotthita).

3) AJAKAJATHA OR AJAKA
(Anterior staphyloma or Iris prolapse)

Ajakajatha - (Sushrutha)
Ajaka - (Vagbhata)

It is Rakthaja Asadhya vyadhi. (Kaphaja Asadhya vyadhi by Dalhana) A red painful growth (or pitica - vagbhata) resembling the dried pellet of excreta of a goat (Aja pureesha vath pitica) comes out by penetrating the Krishna Mandala, slowly growing in the nature, originates due to the vitiation of Raktha dosha and netra patalas (pradhama - Dwiteeya and Truteeya patalas).

The signs & symptoms are 1) severe pain 2) red sticky discharge 3) perforation of Krishna mandala and 4) Prolapse of a red pitica resembling Aja pureesha, and finally causes 5) blindness.

Generally it arises as a complication of savrana shukla and netra Abhighatha. (Anterior staphyloma is the Ist Stage and Iris prolapse is the next)

Though it is explained as Asadhya vyadhi, treatment can be tried like savrana shukla.

Treatment Principle of AjakaJatha:-
1) Snehan (2) Anjana (3) Nasya
(4) Raktha mokshana (5) Agni karma (6) Shastra karma.

A) Triphala ghritha - oral and for nasyam
B) Shukra uthseda Anjana - useful as Analgesic and for correcting the abnormal pigmentation of krishna mandala.

ANJANA - dravyas.
Narikelaasti, Bhallataka beeja, Harithala, vamshankura- According to Kshara vidhi kshara has to prepare with above drugs and has to do mardana and Bhavana with Hasti asti churna, and has to use as Anjana, after anjana vidhi eyes should be washed with Triphala Kashaya.

Agni karma :- If the disease does not respond to medical treatment, Agni karma has to do, in this process the prolapsed part has to burnt with swarna shalaka.

Shastra Karma:- The prolapsed or bulged part is cleaned well and the selected lateral part is pricked with a needle to irrigate the infected fluid, Go mamsa churnam+ Ghritha is filled, in the gap and bandaged. Bandage has to continue for 7 days. After 7 days if any raised part remains that should be scraped out - for shamana chikitsa, Ksheerisarpi is advised for nasya.

Treatment according to **Yogaratnaker :**

1) Sira mokshana 2) Rechana with Trivruth churnam (3) Vata hara ghritas for seka Aashchyotan Tarpana etc. (4) Netra Pooranam : Collect the periosteum of cow bones + lukewarm water in a kamsya patra, grind well and use for poorana (5) Shambooka mamsa rasa (get pakwa in on smoke less fire) + Karpoora Ashchyotan or Anjana (6) Shashakadi ghritha Panam.

4) AKSHI PAKATHYAYA OR PAKATHYAYA SHUKLA
(Serpiginous ulcer, complicated ulcerative keratitis, hypopyon ulcer - keratomalacia - panophthalmitis.)

Akshi pakathyaya - Sushrutha
Pakathyaya Shukla - Vagbhata.

It is tridoshaja asadhya krishna mandala vyadhi, it arises as a complication of abhishyanda (abhishyanadath uthpannam), in which the entire Krishna mandala becomes white by the vitiation of Tridoshas. The associated symptoms are severe pain, and drusti nasham. (Loss of vision)

" It should be rejected for the treatment. "

SUSHRUTHA AND VAGBHATA'S COMPARATIVE DESCRIPTION :

	Sushrutha	Vagbhata
1)	It is called as Akshi Pakathyaya	Pakathyaya shukla
2)	Vitiating doshas are Tridoshas	Vitiating doshas Tridoshas + Raktha.
3)	The infection (white discolouration) spreads only in Krishna Mandala.	Infection spreads not only in Krishna mandala but also in drusti mandala.
4)	Symptoms are 1) Pain 2) Drustinasha (Loss of vision)	Symptoms are 1. Pain 2. Drustinasha(Loss of vision) 3. Raga (Hyperaemia) 4. daha (Burning) 5. shotha (Oedema) 6. Pakam (Suppuration)

If the patient is strengthy, without complications, treatment can be tried like shukra vyadhi.

SHUKRA VYADHI CHIKITSA

(Savrana and Avrana shukra)

1) Lekhana or Gharshana with Anjanas is the main treatment procedure explained for shukra vyadhi.

The treatment prininciple is

a) Snehan b) Swedana c) Shodhana 1) Sthanika 2) Sarvadehika

(a, b, c. for body purification)

d) Lekhana or gharshan

Sthanika shodhana With seka, Aashchyotan, tarpana putapaka etc.

Sarvadehika shodhana With Rakthamokshana, shirovirechana, virechana.

1) **Oral administation of :-** Triphala choorna or kalka or kashaya with or without ghritha,or Triphala ghritha, or Tikthaka ghritha or ghritha got pakwam in Nishotha Kashaya should give for virechan, tarpan etc then rakta mokshana or jalauka mokshana is advised at temporal region.

2) Then sekam with the medicated milk or decoction prepared with -kamala pushapa, ksheera kakoli, Draksha, yastimadhu, vidari kanda, sugar + goat's milk or water.

3) If pain redness, watering of eye reduces then Lekhana anjana has to use

4) If the affected part is rough and unveven Gharshana is advised. (Rubbing of affected area with medicated powders)

Ex.- 1) Fine powder of Shirisha beeja, Maricha, pippali, saindhava lavana- should use for gharshana.

2) Saindhava lavana got bhavana in triphala kashaya - also used for gharshana.

5) **Lekhana Anjanas:-**1) Metalic powders (Swarna, rajatha, Tamra etc.), Rasa Aushada (Gyrika manashila etc.), Lavana, Ratna, Dantha, Shrunga and drugs of Avasadana varga - mix in equal quality, grind well and the fine powders has to use as anjana.

2) Kukkutanda twak bhasma, Lashuna, Trikatu, Karanja and Ela - mix equally, grind well and the fine powder has to use as anjana.

3) Tamraadi Choornaanjan.:-Tamra bhasma 16 parts, shanka bhasma 8 parts, manashila 4 parts, maricha 2 parts, saindhava lavana 1 part - powdered together and has to use for anjana.

4) Shankhaadyan :- Jan Shankha, kola asti, Nirmali beeja, Draksha, Yastimadhu, madhu (equal parts), grinded together and the fine powder has to use as Anjana.

5) Kshaudraadhyanjan -Madhu, samudraphena shirisha pushpa, godantha (equal parts) grinded together and the fine powder has to use as anjan.

6) Mudgaadyanjan :- Fried mudga (without seed coat), shanka, cheeni, madhu (equal parts) as anjan.

(7) Shankha, shukthi, Yastimadhu, draksha, Nirmali phala, madhu grinded together and the fine powder has to use as Anjan.

8) Yasti madhusara (the essense of Yastimadhu)+ madhu is used as Anjana.

9) The essense of vibheethaki majja + madhu is used as Anjana.

10) Maha neela gutika :- Bruhathi moola, yastimadhu, Tamra bhasma, saindhava lavan, shunti.Grind with Aamalaki kashaya, pasted to the Tamra patra (copper vessel), fumigate with yava. ghritha and Aamalaki patra, has to prepare vati with water or honey and has to use for Anjana.

11) Vamshankura, purified Bhallathaki beeja, Taala, Narikela The drugs are burnt with Tila nala - Prepare kshodaka, add Hasti asthi choorna to the kshar odakam, grind well and has to use as anjana. (This anjana brings the normal pigmentation to cornea)

12) Buds of jathi, laksha, gyrika, chandana grind with water and has to use as varthi anjana.

13 Dantha varthi:- The teeth of - Gaja - Varaha, Ostra, Go, Ashwa, Aja, khara + Shankha, muktha, samudra phena - equally- add (1/4 weight) marichi, grind well and has to use as anjana.

14) Tamaala Patraadi varthi:-
Tamaala patra, Go dantha, shankha, samudra phena Kharaasti, Tamra bhasma, grind with go mootra and has to use as varthi **anjana**

15) Rathna, dantha, shrunga, dhathu, Trikatu, Ela, Karanja, beeja Lashuna, swarna ksheeri, grind well and use as Anjan.

16) Vydoorya spatika Shankha, Muktha, pravala, Roupya, Loha, Traphu, Tamra, Naga, Aala, Manahshila, Kukutanda twak bhasma, Samudra phena, Rasanjan, Saindhava lavana - grind with Aja ksheera and has to use as Anjan.

17) Sura, Go dantha, Samudra phena, shirisha pushpa - grind well and has to use for Gharshana - Lekhana anjana.

18) Laangali kshara has to do bhavana either in Aamalaki Kashaya or vana Tulasi Kashaya and has to use as choorna anjan.

19) Go, khara Aswa, Osthra Dantha ; + Shankha, samudra Phena, get bhavana and mardana in Arjuna Kashaya - and has to use as varthi anjan.

20) Chandrodaya varthi:- Hareethaki, Vibheetaki, Pippali, maricha vacha kusta Shankha nabhi, manahshila, grind with Aja ksheera and has to use as varthi Anjan.

21) Chandraprabha varthi:- Rasanjana, swetha maricha, pippali, yastimadhu, Vibheethakaashthi, Shankha nabi, manahshila - grind with Aja ksheera and has to use as varthi anjan.

22) Samudra phena choorna - grind with Lemon juice and has to use as Anjan.

23) LamajjaKaadyanjan:- Lamajjaka (Truna Vishesha), Neela Kamala, sugar, sariba, Chandana, **each 1 karsha** sariba kashaya 1 prastam, get it pakwam and has to use as Anjan.

24) Chanda naadi varthi:- Chandana, gyrica, Laaksha, Maalathi pushpa - grind well and has to use as varthi anjan.

25) Danthaadyanjan - Teeth of Go- khara, oshthra + Shankha, samudra-phena + powdered well and has to use as choorna anjan.

26) Swarna Makshika bhasma + madhu as Anjan.

27) Karanja beeja + phalaaka pushpa swarasa - grind well and use as varthi anjan.

28) Karpoora choorna + vala ksheera as varthi anjan.

29) Vydeha varthi :- Rasanjan, Shilajya, kumkuma, manahshila, Shankha, swetha maricha, sugar as varthi anjan.

30) Nishotha moola kwatham + madhu as Anjan.

Nasya :- 1) Krishnadya taila nasya:- pippali vidanaga yastimadhu, saindhava lavana shunthi - prepare kalka, add aja ksheera, tila taila - has to prepare taila according to taila paka vidhi- and this taila is advised for Nasya.

Ashchyotanam:-1)Yastimadhu, Rasanjan, Kamala, Laaksha prapaundareeka, usheera, sariba - kashaya has to prepare + stanyam Aashchyotanam
2) Jathi patra, yastimadhu - get fry in ghritham - add cool water and has to use for eye wash.
3) Haridra yastimadhu, Krishna sariba, swetha lodhra - kashaya has to prepare for sekam.

Internal yogas
1) Shadanaga guggulu 2) Lohadi guggulu 3) Patoladi ghritam 4) Krishnasariba Kwath + madhu - Orally.

CORNEAL ULCER OR ULCERATIVE KERATITIS)
(Savrana Shukla)

Classification - I

A) Purulent ulcer or Suppurative keratitis
1) Ordinary pyogenic corneal ulcer.
2) 'Hypopyon ulcer or serpiginous ulcer.
3) Mycotic ulcer. 4) Marginal ulcer.

B) Non purulent corneal ulcer
1) Ulcer in association with trachoma. 2) Dendritic ulcer.
3) Lagophthalmic ulcer 4) Ulcer due to vitamin A deficiency
5) Neurotrophic ulcer.

C) Allergic corneal ulcer :
1) Phlyctenular ulcer.

d) Degenerative ulcer:
1) Atheromatous ulcer 2) Moorens ulcer.

Classification - II
A) Superficial keratitis, (a) Purulent b) Non Purulent
B) Deep Keratitis



Arcus Senilis

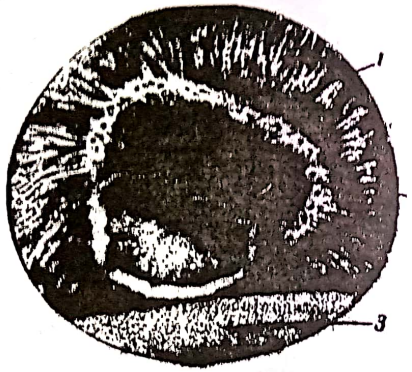

Creeping Ulcer of the cornea:
1. Posteriror synechia; 2.Growing edge of the Ulcer 3.Hypopyon.

Keratoconus

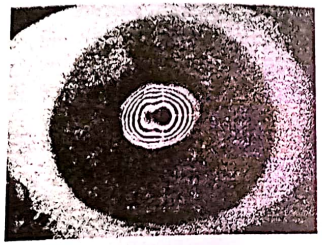

Keratoscopic appearance of the corneal reflex in an advanced case of keratoconus

Superficial Punctate Keratitis

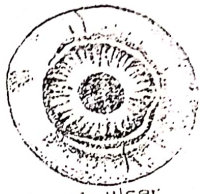

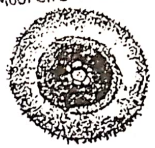

Mycotic Ulcer of cornea

Panophthalmitis

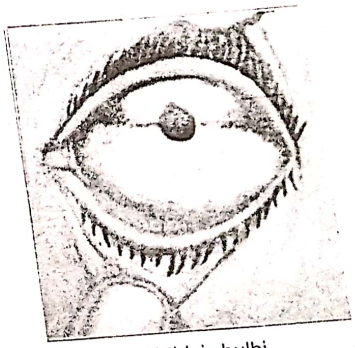

Phthisis bulbi

MODE OF INFECTION

1) In general ulcers occuring in central cornea are usually due to Exogenous infection whether bacterial, viral or micotic.

2) Ulcers occuring in periphery of cornea are often toxic or **allergic** or due to endogenous infection.

3) From ocular tissue :- owing to the anatomical continuity, the inflammation of conjunctiva sclera or Uveal tract, may spread to the cornea and cause the disease

Definition of corneal ulcer

Loss of corneal substance as a result of infection or trauma and formation of a raw excavated area, is known as corneal ulcer.

Causes of corneal ulceration

1) Corneal epithelium can't be penetrated by most of the organisms, except Diphtheria bacillus and gonococcus.

2) Trauma to cornea by penetrating injuries, misdirected eye lashes, foreignbodies and conjunctival concreations.

3) Unhealthy condition of the corneal epithelium like in glaucoma, corneal oedema and keratomalacia etc.

Pathology of corneal ulcer :-

It canbe divided into 3 stages.

1) progressive stage 2) stage of regression 3) Stage of cicatrization.

1) Progressive stage :- (disease increases in this stage) surrounding the ulcer there is marked infiltration of cornea with puscells, necrosis sloughing off the epithelium occurs. ulcer crater is formed (Saucer shaped defect) the margins of the ulcer projects above the surface of cornea due to imbibition of fluids, other complications are - ciliary congestion, Iritis Hypopyon formation, vascularisation of peripheral cornea, opacities in the vitreous etc.

2) Stage of regression :- Infiltrations start to disappear. polymorphs are replaced by large mononuclear cells, leucocytes in the surrounding zone and digests the necrotic tissue.

3) Stage of cicatrization :- Healing of the defect occurs by the formation of granulation tissue from the margins of the ulcer, the newly formed layer is non transparent.

Pathology of perforating types of corneal ulcer :-

Ulcerative process spreads into deeper corneal tissue and perforation follows, the commonest causes are sudden exertion on the part due to cough sneezing and spasm of the orbicularis muscle.The complications are

1) Drainage of aqueous and abolition of anterior chamber.
2) Anterior synechia - anterior staphyloma and Iris prolapse.
3) Adherent leucoma.
4) Sub luxation of lens - Anterior polar cataract.
5) Intra ocular haemorrhages due to sudden lowering of intra ocular pressure.
6) Panophthalmitis.

Pathology of sloughing corneal ulcer :-

If the infecting agent is highly virulent or the body resistent power is very low, the whole or a part of cornea may slough out leaving a very big gap in the cornea, pseudo cornea is formed, the associated complications are, Iris prolapse, occluded pupil, dislocated lens, intra ocular haemorrhages, secondary glaucoma, panophthalmitis.

Signs - symptoms of corneal ulcer :-

Symptoms :- Pain or discomfort or burning sensation in the eye, Lacrimation photophobia, head ache, blurring of vision, Blepharo spasm.

Signs :- 1) Congestion of conjunctiva & cornea. 2) hazy Cornea.
3) Ulcer crater with over hanged margins and the floor filled with necrotic tissue material.
4) The ulcer area gives green staining with 2% fluorescein drops.
5) No window reflex in cornea.
6) ciliary congestion and conjunctival hyperaemia.
7) Iritis with Hypopyon formation (if virulently infected).
8) Peripheral or total corneal vascularisation.

General treatment principle

1) Local & systemic Broad spectrum antibiotics.
2) 1% Atropin ointment application
3) Ointments should apply at nights to prevent adhesion.
4) Dark glasses has to use (no bandeging)
5) In progressive nature of ulcer, the margin should be cauterised to prevent the spreading nature of the ulcer.
6) Treating the peipheral infective focus.

1) Dendritic corneal ulcer:-
It is a type of corneal ulcer with a branched apearence caused by Herpes simplex virus.

Predisposing causes :-
Febrile conditions like influenza malaria or pneumonia etc.

Signs :- 1) Vesicles appear at the termination of the corneal nerves, which soon rupture and produce ulcers in star shape or as branched figure. 2) Loss of corneal sensation. (3) Ciliary Congestion. 4) Lacrimation.

2) Lagophthalmic Ulcer:-
Causes : 1) Coma vigil (2) Orbicularis oculi muscle function failure (paralysis of facial nerve.) 3) Proptosis (4) ectropion.
Because of above causes a person cannot able to close his eyes properly leads to exposure Keratitis, the ulcer is usually located at the lower part of the cornea, near the Limbus.

3) Neurotrophic ulcer :- It occurs as a result of defect in the sensory nerve supply of the cornea, due to
1) Injection of alcohol in to gasserian ganglian to treat trigeminal neuralgia.
2) Neoplasms pressing on the Gasserian ganglion.

Signs :- 1) Oedema of corneal epithelium which exfoliates and become ulcer. (2) ciliary congestion (3) Loss of corneal sensation (4) Pain (5) No Lacrimation(6) Defective vision.

4) Phlyctenular Keratitis and ulcer:-
It is an allergic reaction of cornea to some endogenous toxins, bacterial in origin, (usually tuberculous.) Localised lymphocytic infiltrations of cornea occurs and break down to form ulcers.

Signs :- Whitish nodules formation at limbus (2) ciliary congestion 3) lacrimation (4) Blepharo spasm. 5) Ulceration of cornea.

Stages

1) Phlyctenular keratitis (nodules formation)
2) Phlyctenular ulcer (Nodules break down and ulcer forms)
3) Fascicular ulcer (ulcers from periphery, spreads to centre)
4) Phlyctenular pannus (corneal ulcers, blood supply spreads from all angles)

5) Hypopyon ulcer or Ulcus serpens:-
It commonly occur in the old, the debilitated, and in the alcoholics, the infecting organism is pneumo cocus and the source is the chronic dacryocystitis.

Signs : (1) Greyish white disc shaped ulceration seen near the centre of cornea (2) The ulcer spreads at one sector with a crescentic edge, stops and again spreads in the another sector (serpiginous character) 3) Iritis with Hypopyon (4) ciliary congestion (5) Oedema of eye lids (6) early perforation of cornea (7) secondary glaucoma.

Symptoms :- same as ordinary corneal ulcer but more marked.

6) Mycotic ulcer :- (Due to fungus infection)
Causative agents : - Fungus aspergillus fumigatus, candida albicans, strep tothrix actinomycosis.

Signs :- 1) Dry circular yellowish white ulcers on cornea surrounded by yellowish gutter of demarcation 2) hypopyon formation (3) ciliary congestion.4) Material scraped from the ulcer shows the presence of fungus.

7) Marginal corneal ulcer ;- It is usually seen in the old,debilitated people,gout patients, and as a complication of acute mucopurulent conjunctivitis.

Causative organisms are :-
Koch - weeks bacillus, - morax - Axenfeld diplobacillus

Signs :- 1) Peripheral corneal ulceration (near timbus) with surrounding corneal infiltration.
2) Vascularisation of cornea.
3) Ulcer may heal rapidly but reccurance is common.

Primary marginal ulcer
1) a) catarrhal ulcers (gout),
2) b) Septic focus from ear nose throat c) moorens ulcers.

Secondary marginal ulcers
1) Phlyctenular Keratitis
2) Trachomatous keratitis
3) Purulent conjunctivitis
4) Rosacea Keratitis.

8) Atheromatous ulcer :- It is an ulcer devlops in an old leucoma due to degenerative changes (poor nourishment, low resistence power) the epithelium of leucoma easily get infected and an ulcer develops. The ulcer is very resistent to treatment

9) **Mooren's ulcer :-** It is a superficial ulcer starts at the margin of cornea and spreads gradually in the entire cornea. Base of the ulcer soon becomes vascularised, the deeper structures of cornea are normal, and the cornea never perforates.

The Patient have severe neuralgic pain, lacrimation and photophobia. The ulceration is probably due to metabolic disorders and malnutrition.

10) **Superficial keratitis:-** Inflammation of corneal tissue is known as keratitis in which **Ulcer may or may not** form
It is of two types.
(1) Superficial Keratitis and 2) Deep keratitis,
Punctate erosions inthe superficial layers of cornea is known as **superficial** punctate keratitis.

Etiology :- (1) Virus infection by
a) Herpes simplex - virus (b) herpes zoster virus (c) Herpes Febrils (d) TRIC virus (e) Adeono virus (f) Virus of measles, vaccinia and mumps. (g) acne roscea (h) variola.
2) Inflammatory conditions of eye lids.
3) Kerato conjunctivitis sicca
4) Expossure to ultra voilet rays.

Viral keratitis

a) Herpes simplex keratitis :- (Superficial Keratitis)
Multiple superficial epithelial erosions spread like dendritic ulcer - corneal sensation reduces, and the inflammation extends even into the stroma (diffuse deep keratitis)

b) Herpes zoster ophthalmicus :- The gasserian ganglian is affected, virus spread along the Ist branch of V Cranial nerve - and causes superficial punctate keratitis, By the secondary infection it may also cause keratitis profunda. (corneal sensation completely lost).

c) Herpes Febrills :- Minute opacities, fissures, vesicles form on the cornea and associated with malaria, influenza etc.

d) TRIC virus keratitis : - Punctate keratitis seen in as the complication of Trachoma

e) Adeno virus - type 8 virus - keratitis :- (Superficial punctate keratitis) Follicular hypertrophy of conjunctiva, multiple sub epithelial infiltrations in cornea, with a preauricular lymphadenopathy, it is very contageous and recover spontaneously within 3 to 6 weeks.

f) Measles viral Keratitis :- Catarrhal conjunctivitis with superficial keratitis develops.

g) Vaccinia viral keratitis :- Superficial punctate keratitis and also disciform type of keratitis develops.

h) Mumps :- May cause superficial punctate keratitis.

i) Acne Rosacea Keratitis :- Marginal sub epithelial infiltrations spreads to the centre of cornea, and cornea soon vascularises.

j) Variola :- Nodules formation in conjunctiva and cornea, later nodules ulcerates and causes grave danger to cornea.

11) Deep keratitis :-
Inflammation of the deep layers of cornea - stroma etc.

1) Interstitial keratitis
cellular infiltrations of deeper layers of cornea followed by vascularisation.

Causes Syphilis - Tuberculosis and leprosy etc.

a) Syphilitic interstitial keratitis
Hazy-dull- lustreless cornea (Ground glass cornea with), vascularisation radial brush like vessels appear on cornea (Salmon patches) and the general symptoms of syphilis also exist.

b) Tubercular Interstitial Keratitis :-Lesions are similar as syphilitic but the lesions limited to one sector of cornea only.

c) Interstitial keratitis due to leprosy
Infiltration of deeper layers of cornea, with the dense opacites which spread from periphery to centre of cornea, and does not clear up easily.

2) Disciform keratitis. Causativa agent is herpes simplex virus, greish white disc shaped opacities appears in the deeper layers of central cornea, oedema of corneal stroma causes Thickened cornea, fall of vision, diminished corneal sensation, and the opacities may not disappear completely.

3) Keratitis profunda
It is a type of deep keratitis associated with uveitis and the exact cause is not known.

4) Intra corneal Abscess.
It is due to purulent inflammation of corneal tissue usually as a result of penetrating injury.

5) Sclerosing keratitis
It occurs as a complication of scleritis, There is deep infiltration of cornea adjacent to the area of scleritis.

12) other affections of the cornea;-

1) Arcus senilis :- greyish white circular line in the cornea concentric with limbus - seen in the aged due to lipoid degeration.

2) Arcus juvenilis :- same as above but comes in children congenitally.

3) Kerato conus :- cone shaped cornea due to congenital weakness of cornea.

4) kerato globus (megalo cornea) Diameter of cornea (Normal 12 to 13 mm), it becomes bigger than normal (about 16 mm)

5) Keratectasia - protrusion of cornea without involvement of Iris, following inflammation, without perforation.

6) Argyrosis Dark brown colour of the cornea due to prolonged use of silver preparations.

7) Siderosis :- Iron foreign bodies embedded in the cornea.

8) Chalcosis :- copper foreign bodies embedded in the cornea.

9) Blood staining of cornea, it is seen in severe hyphaema due the absorption of blood by cornea.

10) Staphyloma of cornea - protrusion of cornea along with inflamed Iris , it may follow ulceration and perforation.

11) deposition of melanin pigment in posterior surface of cornea due to high myopia and diabetes.

12) Mustard gas keratitis:- It is a degenerative condition of cornea which results from the effect of mustard gas vapour onthe cornea.

13) Kerato Conjunctivitis:- Deficient secretion of Lacrimal glands and conjunctival glands causes conjunctival congestion, superficial punctate keratitis etc.

14) Keratomalacia:- It is due to vitamin A deficiency associated with dry ness of conjunctiva hazy cornea and bitots spots at near limbal conjunctiva infurthur stages cornea may ulcerate and perforate.

15) Micro Cornea :- It is congenital abnormality in which cornea is smaller is size.

16) Megalo cornea :- It is also congenital abnormality with bigger size of cornea.

CORNEAL OPACITIES

(Avrana shukla)

Opacities of cornea according to the density are as following .

1) Nebula (Slight discolouration) only superficial layer of cornea is affected

2) Macula (Brown opacity) Corneal lesion is some what deeper

3) Leucoma - (White opacity) - Deepest and the thickest lesion.

Note :-

In long standing leucoma degenerative corneal ulcer known as Atheromatous ulcer may develop. and Adhesion of Iris to the leucoma is known as adherent Leucoma.

CAUSES OF CORNEAL OPACITIES

1) Healed corneal ulcer.
2) Healed Keratitis
3) Healed Penetrating injury to cornea.
4) Healed Operative injury to cornea.
5) Foreign body Abrasions
6) Degenerative changes of cornea.

Symptoms :

If the opacity is inthe pupillary area it causes visual disturbances.

(Central opacity of cornea obstructs vision and very Peripheral opacities doesn't obstruct the vision.)

Diseaes of Krishna Mandala

S.No.	name Modern name	Clinicial features	Treatment Principle
1)	Savrana shukla (ulcerative Keratitis)	Small round painful ulcers, develop in krishna mandala with Hot lacrimation by the vitiation of rakta dosha	Asadya But can try like Avrana Shukla
2)	Avrana shukla (Non ulcerative Keratitis)	Krishna mandala is spread with white opacities like shankha chandra and fresh clouds by the vitiation of Rakta (sushrutha), kapha (Vagbhata)	1) Shodhan therapy 2) Anjana Applications
3)	Ajaka jatha (Iris prolapse)	A red painful growth comes out by penetrating the krishna mandala and appears like the driedpellet of excreta of goat, by the vitiation of Raktha dosha shukra	1) Asadya 2) Shastra karma 3) Agni karma 4) Like Avrana
4)	Akshi Pakatyaya (Panophthalmitis)	Krishna mandala completely become white by the vitiation of tridosha	Asadya

Diseases of Krishna mandal (Sushrutha)

Total diseases = 4

1) Avrana shukla = Ashastra kruth = 1
2) Savrana Shukla
3) Ajakajatha
4) Akshipakatyay

Asadya = 3

Diseases of Krishna mandal by vagbhata

1) Shuddha Shukla = Ashastra kruth = 1
2) Kshatha shukla
3) Ajaka
4) Pakathyaya shukla
5) Sira shukla

Asadya = 4

Note : -

Though most of the diseases (except avrana or shuddha shukla) are explained as asadya, treatment principles and yogas are explained for the all.

सर्वगत रोग

स्यन्दास्तु चत्वार इहोपदिष्टास्तावन्त एवेह तथाधिमन्था
शोफान्वितो शोफयुतश्च पाकावित्येवमेते दश सम्प्रदिष्टा
हताधि मन्थोनिलपर्ययश्च शुष्काक्षि पाकोन्यत एव वातेः
दृष्टि स्तथाम्लाध्युषिता सिराणामुत्पात हर्षवपि सर्वभागाः

संक्रामक व्याधियों

प्रसङ्गाद् गात्रसंस्पर्शान्निःश्वासात् सह भोजनात्।
एकशय्यासनाच्चैव वस्त्रमाल्यानुलेपनात्॥
कृष्ठं ज्वरश्च शोषश्च नेत्राभिष्यन्द एव च।
औपसर्गिकरोगाश्च संक्रामन्ति नरान्नरम् ॥

(सु॰ नि॰ २ अ॰)

अभिष्यन्द् का सर्वरोगकारणत्व

प्रायेण सर्वे नयनामयास्तु भवन्त्यभिष्यन्दनि मित्त मूलाः।
तस्माद भिष्यन्दमुदीर्य माणमुपाचरेदाशुहिताय धीमान् ॥

(सु॰ उ॰ 6/5)

1. वातज अभिष्यन्द

निस्तोदनं स्तम्भनरोमहर्षसंघर्षपारुष्य शिरोभितापाः
विशुष्कभाव : शिशिराश्रुता च वाताभिपन्ने नयने भवन्ति॥

(सु॰ उ॰ 6/6)

वातेन नेत्रेभिष्यण्णे नासानाहोल्पशोफता।
राङ्खाक्षिभ्रूललाटस्य तोदस्फूरणभेदनम्॥
शुष्काल्पा दूषिका शीतमच्छँचाश्रु चला रुजः
निमेषोन्मेषणं कृच्छ्राज्जन्तुनामिब सर्पणम्॥
अक्ष्याध्मातमिवाभाति सूक्ष्मैः शल्यैरिवाचितम्।
स्निग्धोष्णैश्चोपशमनं सोभिष्यन्दः .... ॥

(अ:हृ:उ:15)

2. पैतिक अभिष्यन्द

दाहप्रपाकी शिशिराभिनन्दा धूमायनं बाष्पसमुच्छ्रयश्च।
उष्णाश्रुता पीतकनेत्रता च पित्ताभिपन्ने नयने भवन्ति॥

(सु॰ उ॰ 6/7)

दाहो धूमायनं शोफः श्यावता वर्त्मनो वहिः।
अन्तःक्लेदोश्रु पीतोष्णं रागः पीताभदर्शनम्॥
क्षारोक्षितक्षताक्षित्वं पित्ताभिष्यन्दलक्षणम्।

(अ:हृ:उ:15 अ॰)

3. कफज अभिष्यन्द

उष्णाभिनन्दा गुरुताक्षिशोफः कण्डूपदेहौ सिततातिशैत्यम्।
स्रावो मुहुः पिच्छिल एव चापि कफाभिपन्ने नयने भवन्ति॥

(सु॰ उ॰ 6/8 अ॰)

स्यन्दे तु कफ सम्भवे
जाड्यं शोफो महान् कण्डूर्निद्रान्नानभिनन्दनम॥
सान्द्रस्निग्धबहुश्वेतपिच्छावत् दूषिकाश्रुता।

(अ:हृ:उ:15 अ॰)

4. रक्तज अभिष्यन्द

ताम्राश्रुता लोहितनेत्रता च राज्यः समन्तादतिलोहिताश्च।
पित्तस्य लिङ्गानि च यानि तानि रक्ताभिपन्ने नयने भवन्ति॥

(सु॰ उ॰ 6/9 अ॰)

रक्ताश्रुराजीदूषीकारक्तमण्डलदर्शनम् ॥
रक्तस्यन्देन नयनं सपित्तस्यन्दलक्षणम्।

(अ:हृ:उ:१२अ:)

अधिमन्थ

वृद्दैरैतैरभिष्यन्दैर्नराणामक्रियावताम्।
तावन्तस्त्वधिमन्थाः स्युर्नयने तीव्रवेदनाः॥

(सु॰ उ॰ 6/10 अ॰)

अधिमन्थ के सामान्य लक्षण

उत्पाट्यत इवात्यर्थं नेत्रं निर्मथ्यते तथा।
शिरसोर्धं च तं विद्यादधिमन्थं स्वलक्षणैः॥

(सु॰ उ॰ 6/11 अ॰)

5. वातिक अधिमन्थ

नेत्रमुत्पाट्यत इव मथ्यतेरणिवच्च यत॥
संघर्षतोदनिर्भेदमांससंरब्धमाविलम्॥
कुंचनास्फोटनाध्मानवेपथुव्यथनैर्युतम्॥
शिरसोर्धं च येन स्यादधिमन्थः स सारुतात्॥

(सु॰ उ॰ 6/12,13 अ॰)

..... उपेक्षितः
अधिमन्थो भवेत्तत्र कर्णयोर्नदनं भ्रमः।
अरण्येव च मथ्यन्ते ललाटक्षिभ्रुवादयः॥

(अ.हृ.अ15)

6. पित्तज अधिमन्थ

रक्तसाजीचितं स्रावि वह्निनेवावदह्यते।
यकृत्पिण्डोपमं दाहि क्षारेणाक्तमिव क्षतम्॥
प्रपक्वोच्छूनवर्त्मान्तं सस्वेदं पीतदर्शनम्।
मूर्च्छाशिरोदाहयुतं पित्तेनाक्ष्यधिमन्थितम्॥

(सु॰ उ॰ 6/14,15)

ज्वलदङ्गारकीर्णाभं यकृत्पिंडसमप्रभम्॥
अधिम न्थेभवेन्नेत्रम्।

(अं॰ हृ॰ उ॰15अ॰)

7. कफज अधिमन्थ

शोफवन्नातिसंरब्धं स्रावकण्डूसमन्वितम्॥
शैत्यगौरवपैच्छिल्य दूषिकाहर्षणान्वितम्॥
रूपं पश्यति दुःखेन पांशुवर्णमिवाविलम्॥
नासाध्मान शिरोदुःखयुतं श्लेष्माधिमन्थितम्॥

(सु॰ उ॰ 6/16,17 अ॰)

अधिमन्थे नतं कृष्णमुन्नतं शुक्लमण्डलम्॥
प्रसेकी नासिकाध्मानं पांशुवर्णमिवेक्षणम्।

(अं॰ हृ॰ 15 अ॰)

8. रक्तज अधिमन्थ

बन्धुजीवप्रतीकाशं ताम्यति स्पर्शनाक्षमम्।
रक्तास्रावं सनिस्तोदं पश्यत्यग्निनिभा दिशः॥
रक्तमण्डारिष्टवच्च कृष्णभागश्च लक्ष्यते।
यद्दीप्तं रक्तपर्यन्तं तद्रक्तेनाधिमन्थितम्॥

(सु॰ उ॰ 6/18,19 अ॰)

मन्थेक्षि ताम्रपर्यन्तमुत्पाटनसमानकम्॥
पर्वेण बन्धूकनिभं ताम्यति स्पर्शनाक्षमम्।
असृङ् निमग्नारिष्टाभं कृष्णमग्न्याभदर्शनम्॥
अधिमन्था यथाख्यं च सर्वे स्यंदाभिकव्यथाः।
शङ्खदन्तकपालेषु कपाले चातिकक्कसः॥

(अं॰ हृ॰ उ॰ 15 अ॰)

हन्याद् दृष्टिं सप्तरात्रात् कफोत्थोधिमन्थोसृक्समुद्भवः पंचमरात्रात्।
षड्रात्राद् वै मारुतोत्थो निहन्यान्मिथ्याचारात् पैत्तिकः सद्य एव॥

(सु॰ उ॰ 6/20 अ॰)

9. सशोफ अक्षिपाक

कण्डूपदेहाश्रुयुतः पक्वोदुम्बरसन्निभः॥
दाहसंहर्ष ताम्रत्वशोफनिस्तोदगौरवैः॥
जुष्टो मुहुः स्रवेच्चास्रमुष्णशीताम्बु पिच्छिलम्॥
संरम्भी पच्यते यश्च नेत्रपाकः सशोफजः॥

(सु॰ उ॰ 6/21,22)

सशोफः स्यात्त्रिभिर्मलैः
सरक्कैस्तत्र शोफोतिरुग्दाहष्ठीवनादिमान्।
पक्वोदुम्बरसङ्काशं जायते शुक्लमण्डलम्॥
अश्रूष्णशीतविशद पिच्छिलाच्छघनं मुहुः॥

(अं॰ हृ॰ उ॰ 15 अ॰)

10. अशोफ अक्षिपाक

शोफहीनानि लिङ्गानि नेत्रपाकेत्वशोफजे॥ (सु॰ उ॰ 6/23 अ॰)

अल्पशोफेल्पशोफस्तु पाकोन्यलक्षणैस्तथा।
वाग्भट ने अशोफ अक्षिपाक को अल्पशोफ अक्षिपाक कहा। (अं॰ हृ॰ 15 अ॰)

11. हताधिमन्थ

उपेक्षणादक्षि यदाधिमन्थो वातात्मकः सादयति प्रसह्य।
रुजाभिरुग्राभिरसाध्य एष हताधिमन्थः खलु नाम रोगः॥ (सु॰ उ॰ 6/23 अ॰)

हताधिमन्थः सोपि स्यात् प्रमादात्तेन वेदनाः।
अनेकरूपा जायन्ते व्रणो दृष्टै च दृष्टिहा॥ (अं॰ हृ॰ 15 अ॰)

दूसरा हताधिमन्थः

अन्तःसिराणां श्वसनः स्थितो दृष्टि प्रतिक्षिपन्॥
हताधिमन्थं जनयेत्तमसाध्यं विदुर्बुधाः (सु॰ उ॰ 6/24 अ॰)

अन्तर्गतः सिराणां तु यदा तिष्टति मारुतः।
स तदा नयनं शीघ्रं दृष्टि निरस्यति॥
तस्यां निरस्यमानायां निर्मथ्नन्निव मारुतः!
नयनं निर्वमत्याशु शूलतोदादिमन्थनैः॥
अथवा शोषयेदक्षि क्षीणतेजोबलानलम्।
उत्पद्ममिव संशुष्कमवसीदति लोचनम्।
हताधिमन्थं तं विद्यादसाध्यं वातकोपतः

-डल्हण (सु. उ. 6 अ.)

12. वातपर्याय

पक्ष्मद्वयाक्षिभ्रुवमाश्रितस्तु यत्रानिलः संचरति प्रदुष्टः।
पर्यायशश्चापि रुजः करोति तं वातपर्यायमुदाहरंति॥ (सु॰ उ॰ 6/25 अ॰)

तद्वज्जिंह्यं भवेन्नेत्रमूनं वा वातपर्ययी॥ (अ. हृ. उ. 15 अ.)

13. अन्यतोवात

यस्यावटुकर्ण शिरोहनुस्थो मन्यागतो वाप्यानिलोन्यतो वा॥
कुर्याद्रुजोति भ्रुवि लोचने वा तमन्यतोवातमुदाहरन्ति॥ (सु॰ उ॰ 6/26 अ॰)

मन्याक्षिशंखतो वायुरन्यतो वा प्रवर्त्तयन्।
व्यथां तीव्रामपैच्छिल्यरागशोफं विलोचनम्॥
सङ्कोचयति पर्यश्रु सोन्यतोवातसंज्ञितः॥ (अ. हृ. उ. 15 अ.)

14. शुष्काक्षिपाक

यत् कूणितं दारुणरुक्षवर्त्म विलोकने चाविलदर्शनं च यत्।
सुदारुणं यत् प्रतिबोधने च शुष्काक्षिपाकोपहतं तदक्षि॥ (सु॰ उ॰ 6/27 अ॰)

वातपित्तातुरं घर्षतोदभेदोपदेहवत्।
रुक्ष दारुणवर्त्माक्षि कृच्छ्रोन्मीलनिमीलनम्॥
विकूणनविशुष्कत्वशीतेच्छा शुलपाकवत्।
उत्कः शुष्काक्षिपाकोयम् (अ. हृ. उ. 15 अ.)

15. अम्लाध्युषित

अम्लेन भुक्तेन विदाहिना च संछाद्यते सर्वत एव नेत्रम्।
शोफान्वितं लौहितकैः सनीलैरेतादृगम्लाध्युषितं वदन्ति॥ (सु॰ उ॰ 6/28 अ॰)

अन्नसारोम्लतां नीतः पित्तरक्तोल्वणैर्मलैः
शिराभिर्नेत्रमारूढः करोति श्यावलोहितम्।
सशोफदाहपाकाश्रु भृशं चाविलदर्शनम्॥
अम्लोषितोयम् (अ. हृ. उ. 15 अ.)

16. सिरोत्पात

अवेदना वापि सवेदना वा यस्याक्षिराज्यो हि भवन्ति ताम्राः ।
मुहुर्विरज्यन्ति च ताः समन्ताद् व्याधिः सिरोत्पात इति प्रदिष्टः ॥

(सु. उ. 6/29 अ.)

रक्त राजीततं शुक्लमुष्यते यत्सवेदनम
अशोफाश्रूपदेहंच सिरोत्पातः सशोणितम

(अ. ह. उ. 15 अ.)

17. सिराप्रहर्ष वा सिराहर्ष

मोहात् सिरोत्पात उपेक्षितस्तु जायेत रोगस्तु सिराप्रहर्षः ॥
ताम्राच्छमस्रं स्रवति प्रगाढं तथा न शक्नोत्यभिवीक्षितुं य ॥

(सु॰ उ॰ 6/30 अ॰)

उपेक्षितः सिरोत्पातो राजीस्ताः एव वर्धयन
कुर्यात्सास्र सिराहर्ष तेनाक्ष्यु व्दीक्षणाक्षामम्

(अ. ह. उ. 15 अ.)

SARVA GATHA ROGAS

The diseases which are explained under this group arises by spreading in all parts (Pakshma varthma - Swetha and Krishna Mandala). so only named as sarva gath roga.

According to Sushrutha - 17 diseases, they are :

4 types of abhishyanda

1)Vataja Abhishyanda
2) Pittaja Abhishyanda
2) Kaphaja Abhishyanda
4) Rakthaja Abhishyanda

4 types of adhimantha

5) Vataja adhimantha
6) Pittaja adhimantha
7) Kaphaja adhimantha
8) Raktaja adhimantha.

3 types of Akshi pakas)

9) Sa shopha Akshipaka
10) Ashopha Akshipaka
11) Sushkaakshi paka

12) Hathaadhi manda
13) Anila Paryaaya
14) Anyatho vatha
15) Sirothpaatha
16) Siraaharsha
17) Amladyushitha

According to vagbhata Sarvaakshi rogas 16 they are :
17 disease of Sushrutha - 2 diseases = 15 (Sirothpatha, siraharsha not explained why because these two he explained in shukla gatha rogas) and added Akshi pakatyaya, so totally 16 diseases According to vagbhata

ABHISHYANDA

(Abhi = from four sides (all angles) - (syanda = Discharge.)
It is a contagious disease (Sankramika vyadhi) and becomes the cause for the most of the eye diseases In this disease watery or sticky eye discharge comes from the all angles of the eye.
It is of 4 types. 1) Vataja 2) Pittaja 3) Kaphaj 4) Rakthaja Abhshyand

1) VATAJ ABHISHYANDA
(Sub acute Catarrhal conjunctivitis)

It is vataja sadhya vyadhi
Signs & symptoms :- As per sushruth
Nistodana = Suchi viddhavath shoola (Pricking pain in the eye.)
2) Stambana = Stiffness ; 3) Romaharasha = horripilation
4) Sangharsha = Foreign body sensation 5) Parushya = kaathinya (roughness)
6) Shirobhitapa = head ache 7) Vishushkabhava = dryness
8) Shishirashrutha = cool lacrimation (SU)

Description of sushrutha :- In vataja Abhishyanda patient feels headache, stiff, hard, dried eyes with, foreign body sensation, cool Lacrimation and with Pricking pain inthe eyes.

Vagbhata :- 1) Shankha, Akshi, Bhru, lalata - Toda, spurana, and bhedana (pricking, cutting type of pain inthe Shankha, Akshi, bhru, and lalata);
2) Chala ruja - Radiating type of pain in above places
3) Shuska alpa dushika = dried and little eye discharge
4) Sheetha ashru = Cool Lacrimation
5) Nimeshonmeshana Kruchram = difficulty in opening and closing the eye lids.
6) Janthunaamva sarpana = Patient feels that Krimi is spreading in the eyes (foregin body sensation)
7) Nasanaaha = Nasal obstruction
8) Alpa shopha = Oedema of eye
9) Snigda ushnaashcha upashamana feels happy with oily and hot treatments.

Discription Vagbhata :- In vataj abhishyanda the Patient feels radiating, pricking cutting pain in the Shankha, Akshi, bhru ,and lalata; cool Lacrimation, dried less eye discharge, difficulty in opening and closing the eyes, Nasal obstruction, oedema, foreign body sensation in the eyes and the patient feels happy with oily and hot treatments.

2) PITTAJA ABHISHYANDA
(Acute Catarrhal conjunctivitis)

It is pittaja vyadhan Sadhya vyadhi, The disease inwhich the patient feels daha (burning sensation inthe eye), paka (suppuration), dhooma - bhashpa samucchaya (smoky sensation), ushna ashru (hot Lacrimation), Peetha netra (yelloish eyes), Shishirabhinanda (Feels happy with cool touch or cool medications, is described as pittaja abhishyanda.

Vagbhata extra points :-
1) Varthma shopha and shyava varthma = oedema and black discolouration of eye lids.
2) Antah kleda = exudation in the eyes.
3) Feels severe burning sensation like in Agnidagdha vrana.

3) KAPHAJA ABHISHYANDA
(Acute muco purulent conjunctivitis)

It is kaphaja vyadan vyadhi.
The disease, in which the patient feels gurutwa (heavyness), shopha (oedema), Kandu (itching sensation), upadeha (Sticking of lids together) Pischila srava (Sticky Discharge), ushnabhihanda (patient feels happy with hot treatments), is explained as kaphaja Abhishyanda.

Extra points of vagbhata :-Nidra =(Sleeping mood), and Aruchi (Anorexia).

4) RAKTHAJA ABHISHYANDA
(Acute muco Purulent conjunctivitis)

It is rakthaja vyadhan sadhya vyadhi
The Signs & symptoms are merely equiavlent to pittaja Abhisyanda The special symptoms are (1) Lohitha netra (red eyes),
2) Tamrashru (Red Lacrimation)(3)Raktha raaji (red capillary net appearence)

VATAJA ABHISHYANDA CHIKITSA

1) a) Nidana Parivarjanam (Treating of the cause), b) Rest c) Sheetho pachar (1 to 4 days) d) ushnopachar (in niram stage)
2) In saama dosha 4 days langhana etc., pathyas has todo (sweda pralepa, Tiktanna, dhooma, Pachan drugs and Langhana are advisable)
3) Ghritha, Kashayarasa, Guru ahaar, anjana and snana are not to do in saama stage.

4) Treatment Principle :- (after Ama Pachana) (a) Sneha panam (ghritha pana) (b) mrudu sweda (c) Raktha mokshana (at upanasika, lalata and apanga) (d) sneha virechana (e) sneha - Niruha vasti (f) sneha tarpana (g) sneha Putapaka (h) Sneha dhooma (i) sneha nasya (j) Aschyotan (k) sneha Pariseka (l) Shiro Vasti (m) Pradeha (n) Abhyanga (o) Sneha anjana.

5) Snehana:-
(a) In take of ghee after meals
(b) In take of medicated milk and ghee prepared with triphala
(c) In take of medicated milk and ghee prepared with Vidarigandhadi drugs.
(d) In take of medicated milk and ghee prepared with the dashamoola

After the above medication mrudu sweda is adviced.

6) Mrudu sweda : (Seka) with any of the folowing :-
1) Vata hara bhadradarvadi kashaya (2) Anupa mamsa
3) Amla dravas like kanji (4) Sukoshna chatursneha
5) Sukoshna dugda + saindhava lavana (6) Vasavara (7) payasa (8) Upanaha
9) Snigda dravyas + mamsa + Dadima phala rasa + Amalaki phala rasa.
10) Salvana sweda. 11) Haridra Rasanjan + milk + sindhava lavan
12) Erenda moola - patra + twacha siddha dugda - useful in seka **nasya, putapaka** etc.

13) Kantakari moola sukoshna dugda for - seka.

14) The decoction of Saindhava lavana, musta, yastimadhu, pippali, + milk Sechana

7) Aashchyotan yogas (eye drops)

a) With the decoction of Bilwadi panchamool, Bruhati, Erenda and shigru,
b) with the decoction of Nimba patra and Lodra

c) Netra Bindu:- Used for eye drops
(Gulab jala 1,2 botlles, Karpoora 6 masha, Ahiphena 2 tola, Rasanjan 8 tola)

d) Phullika drava :- Used for eye drops
(Gulabjala 2 kg, Mishri 4 tola, saindhava lavana 4 tola ,spatica 4 tola)

e) Rasanjan drava :- Used for eye drops
(Rasanjan 12 grams, spatica 24 grams, Honey or mishri 24 grams, Gulabjal 8 ounce)

f) Tankan or spatika eye drops
g) The medicated milk prepared from
(Erenda moola, patra, twacha)
h) The medicated milk prepared from Kantakri moola

8) Pindika:-
Hot pindika (Poultice) is prepared with erenda patra moola and twacha

9) Anjana :- with the following remedies.
a) Yastimadu, Haridra, Hareetaki, and Devadaru should mix equally and grind with Aja Ksheera
b) Swarna gyrika 1, pippali 4 parts, shunti 8 parts should grind with Aja Ksheera to Prepare vati
c) The rasakriyanjan prepared with, Shunti + Saindhava lavana+ ghrithamanda is used as **anjan**
d) Madhu, saindhava lavana, swarna gyrica, grinded well and has to use as anjan.

10) **Bidalaka :-** a) Lodhra, fry in ghritha and has to paste to the eye lids
b) Hareetaki, fry in ghritha and has to apply to the eye lids
c) Rasanjan 50g, spatica 24g, Ahiphena 10g, Nimapatra 3, Ksheera 500g, gyrica 24g and has to paste to eye lids.
d) Bhmyamalak + saindhava lavana and Kanji, should mix in a copper vessel to paste to the eye lids.
e) Saindhavalavan, Daru haridra, Gyrica, hareetaki, and rasanjan has to paste to the eye lids.

2) Pittaja Abhisyanda Chikitsa

A) 1) Langhana (for aama Pachanam)
2) sneha pana (3) Raktha Mokshana
4) Virechana (1to 4 for systemic treatment.)
5) Local treatment seka Aashchyotan Anjan Nasya Alepa Tarpana Putapak etc. has to do.
6) Pittaja visarpa or Pitta hara chikitsa should give.

B) 1) Common yoga for seka, Aashchyotan and for nasya:- Medicated ghee prepared from Gundra (truna visesha), shali, Doorva, Paashana bhedha, Daru haridra, Haridra, Ela, Uthphala, Lodhra, swetha kamala, Neela kamala, sharkara Kusha, Ikshu, vetha, Padmaka, Draksha, madhu, Raktha chandana, Yastimadhu, stanya, sariba.

c) **Seka yogas** :- Chandan, Nimba patra. yastimadhu, Rasanjan, Saindhava lavan, grind with water and should use as seka with honey .

D) **Aashchyotana yogas :**
1) Nimba patra kalka has to paste to the Lodhra and heated :- The powder + stanya, after filtration should use for Aashchyotan.

2) Medicated milk prepared from Draksha, yastimadhu, manjista, jeevaneeya dravya .

3) The fine powder of yastimadhu, Lodhra, Draksha, sharkara, and kamal should prepare a potali and dipped in the stanya - this stanya is filtered used for Aashchyotana.

4) Yastimadhu, patha Lodhra - powdered and kept in a potali and is dipped in ghrita, this ghrita is filtered and used for Aashchyotana 5) Gambari twak, or Aamalaki phala, or Hareetaki phala or Katphala can be used by dipping the potali in water like above.

e) **Pindi** (1) Amalaki 0r (2) mahanimba patra pindi can be used.

f) Bidalaka :- Chandana, sariba, Manjista, padmaka, yastimadu jatamamsi, Tagara, lodhra, jathipushpa - gyrica - can be applied to the eye lids.

G) Anjana - 1) Phalsha pushpa or moola swarasa or shallaki swarasa + madhu + sharkara - as Anjana.

2) Trivruth or Yastimadhu + Madhu+ Sharkara as- Rasakriya anjan.

3) Musta, Samudra phena, Kamala Vidanga, ela, Aamalaki, beejasar as Rasa kriyanjan

4) Talisa patra, Ela , gyrika, musta, shankha + stanya or cow milk as choorna anjan.

5) Gyrika + stanya (6) Phalasha pushpa + madhu (7) Samudra Phena + madhu or stanya (8) yastimadu, draksha, Lodra vacha Sharkara, Kamala + stanya. 9) Yastimadu lodra, Draksha, sharkara kamal + stanya. 10) Swarna bhasma stanya or cow milk 11) Amalaki Rasakriyanjan with stanya or cow milk 12) Netrabala chandan, udumber twak + stanya

KAPHAJ ABHISHYANDA CHIKITSA

1) Treatment principle :- General Principles and sira vyadana then sweda, Avapeedan, nasya, Anjan, Dhoomapan seka, pralepa, Kavalagrah, Ruksha Ashchyotan, Ruksha putapaka, Apatarpan - Tiktha ghritha, (kaphahara) Aahara and vihara (Sushrutha)

2) Langhana, swedana nasya, Tikthabhojan Teekshna Pradamana nasya, Teekshna upanaha, Ruksha and Teekshna virechan. (yogaratnakar)

3) Pindi 1) Shighru patra Kalka (lukewarm pindi is used)

2) Nimba patra + shunti + saindhava Lavana, luke warm pindi is used

4) Aashchyotan :- Saindhava lavana and Lodhra has to fry in ghritha + sauveeranjan, grind with water and, the extracted swarasa is used for Ashchyotana.

5) Bidalaka : 1) Rasanjan or 2) Shunti, hareetaki or 3) Vacha, Haridra Shunti or 4) Gyrika, shunti is used as varthma lepam (Bidalaka)

6) Anjan 1) Saindhava lavana, Hingu, Triphala, Yastimadhu, Anjan, Tutha,Tamra and prapaundareeka, grinded with water, varthi is prepared for Anjan.

2) Hareetaki , Haridra, yastimadu as varthi anjan.

3) Trikatu, Triphala, Haridra, Vidanga sara in equal parts + Tagara, kusta,Devadaru, shankha, patha, vyosha, manashila. As varthi anjan .

4) jathi pushpa, karanja Pushpa, shigru beeja + or pushpa water, as varthi anjan.

5) Puthi Karanja,Phalasha pushpa, shigru Pushpa, Bruhathi dwayam (phala and pushpa) Rasanjan, Saindhava lavana, Draksha, chandan, manashila harital, lashuna + water as varthi anjan.

6) Ksharanjan also used.

RAKTHAJA ABHISHYANDA CHIKITSA

A) Antah Shodhana

1) Snehana with Kaumba ghritha (100 yrs old ghritha)

2) Mamsa rasa bhojana 3) Sira Mokshana 4) virechan 5) shiro virechan

B) Sthanika upachara :- (Local Treatments)

1) Pradeha (2) Parisheka (3) nasya (4) Dhooma (5) Aashchyotan (6) Abhyanga (7) Tarpana (8) Snigda puta Paka (9) anjana (Prasadana) (Mrudu sweda, jalaukavacharana, Ghritha pana has to do when severe pain is associated)

I) **Seka :-** Triphala Lodhra, yastimadu, sugar, musta should grind with cool-water, and used for .

II) Pralepa :- Neelothphala, usheera, Daruharidra, Kaleeyaka (Agaru) yastimadu, musta, Lodra should grind with shathadautha ghritha to paste around the eyes.

III) **Aashcyotan** (putting of eye drops with the following medicines)

1) Sthanya (Breast milk)

2) Dugda or ghritha (milk & ghee)

3) The ghee got bhavana with Lodhra

4) The medicated water has to use prepared with Triphala + Sharkara + water

5) shigru patra swarasa + madhu =

6) Bhumyamalaki swarasa 7) Amalaki phala swarasa

IV) Anjan :- With the following medicines

1) Shriparni, padhala (patha), Arjuna, Dhathaki, Aamalaki, Bilva, Bruhathi, Bimbi Lodhra, manjista, grinded with madhu or ikshu rasa for anjan.

2) Chandan, kumuda, Teja pathra, shilajithu, kesara, Loha, Tamra, Tuttha, Nimba Niryasa, Rasanjan, Trapu, Kamsyamala grinded with madu prepare varthi for Anjan.

3) kulutthaadyanjan (Kulutha got bhavana in aja ksheera, saindhavalavan, Haridra, Rasanjan , as Anjan.

V) Bidalaka :

1) Neelkamal, musta, Daruharidra, kaleeyaka yastimadu, muktha Lodhra padmaka, grinded with shatadautha grhitha and is used as varthma lepam.

Note : (Rakthaja abhishyanda, rakthaja adimanda, Siraharsha, sirothpatha are having similar treatment principles.)

CONJUNCTIVITIS

Inflammation of conjunctiva characterised by redness of the eye and conjunctival discharge is known as conjunctivitis.

Causes:-

1) Exogenous :- Causative agents entered in to conjuctival sac from outside (May be micro organisms - foreign bodies, chemicals)

2) Endogenous :- Blood borne infection, allergic response or due to metabolic defects.

3) Infection spreading from surrounding structures. i.e.- skin. lacrimal apparatus,cornea, sclera, orbit, and uveal tract.

CLASSIFICATION OF CONJUNCTIVITIS

(a) Infective Conjunctivitis
- 1) Bacterial
- 2) Viral
- 3) Bedsonia group
- 4) Special infection

1) Due to Bacterial infection:-

a) Acute Catarrhal or muco purulent conjunctivitis
- I. Acute
- II. Subacute
- III. Chronic

(b) Purulent conjunctivitis

(c) Membranous Conjunctivitis

(d) Pseudo membranous conjunctivitis

(e) Angular conjunctivitis

2) Due to Viral infection:-

a) Acute haemorrhagic conjunctivitis

b) Follicular conjunctivitis
- I. Acute
- II. Chronic

c)c. in measles

d) c. in varicella or chicken pox

e)c. in herpes zoster ophthalmicus

f) c. in vaccinia

g)c. in mumps

h).c. in infuenza

i)c. in yellow fever and dengue fever.

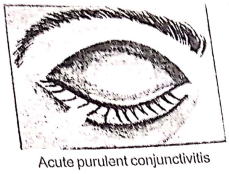

Acute purulent conjunctivitis



Membranous conjunctivitis

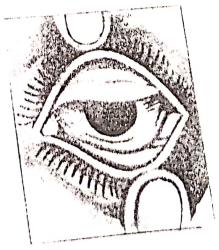

Pseudo Membranous Conjunctivitis

3) Conjuctivitis due to bedsonia group of organisms
   a) Swimming - bath conjunctivitis
   b) Trachoma
   c) Inclusion blennorrhoea of the new born.

4) Conjunctivitis due to specific infection.
   a) tuberculous conjunctivitis
   b) Syphilitic "
   c) Tularensis "
   d) C. in Leprosy "
   e) Parinaud's

B) Allergic conjunctivitis
   a) simple allergic Conjunctivitis
   b) phlyctenular C.
   c) Vernal conjunctivitis or spring catarrh

(C) Conjunctivitis following injury
(D) Conjunctivitis associated withskin diseases
(E) Due to B. complex defficiency (pyridoxine defficiency)

CONJUNCTIVITIS DUE TO BACTERIAL INFECTION

A/I/a). Acute catarrhal or acute muco purulent conjunctivitis
It is the commonest cause for " red eye".

Causative organisms :-
Koch - week bacillus, staphylococcus, pneumococcus, strepto coccus, influenza bacilli and also adeno virus.The **Incubation period** is 3 to 4 days. It occurs to the people dosha with unhygienic and dirty habbits.

Conjunctival discharge :- It contains tears, mucous, epithelial cells, bacteria, Leucocytes, fibrin and may be R.B.C. (blood stained discharge)

Symptoms :- Discomfort (foreign body sensation), photophobia, watering of eye, blurring of vision (due to conjunctival discharge covering on cornea), sticking together of eye lids at nights, rainbow haloes around thelight etc.

Signs :- It starts in one eye later affects the other eye. conjunctival congestion, oedema of lids. petechial haemorrhages. **Mucopurulent discharge** Accumulates at inner canthus - outer canthus - lower fornix, roots of cilia, and causing matting of eye lashes .

Complications :- 1) passes into chronic stage 2) marginal corneal ulcer 3) Blepharitis 4) chronic dacryocystitis.

Treatment :- (a) Prophylactic b) curative
a) Taking care from spreading of infection to the other eye, sleeping on infected side, personal belongings should kept separate.
b) Curative :-
1) Conjunctival sac should be washed with hot normal saline
2) Sulfacetamide drops 3 to 4 times a day.
3) Broad spectrum antibiotic drops or ointment.(Ointment should use at night to prevent sticking of eye lids).
4) No Bandaging but shoud use dark glassess.
5) Steroids are contra indicated
6) culture of the discharge for the isolation of infecting organism and to find its sensitivity to antibiotic for proper treatment.
7) If cornea is involved 1% atropin sulphate ointment should use.

A)1/a/ II) **Sub acute muco purulent Conjunctivitis**
Etiology - Clinical picture and pathology same as above but signs and symptoms are less severe than Acute catarhal conjunctivitis

A/1/a/ III) Chronic catarrhal conjunctivitis
It is a chronic catarrhal inflammation of conjunctiva.

Causes 1) for not treating the Acute catarrhal conjunctivitis in time. 2) Continuous irritation of conjunctiva due to smoke, dust, abuse of alcohol and refractive error. 3) Misplaced eye lashes, 4) chronic dacryocystitis and 5) chronic rhinitis

Symptoms :- Burning sensation in the eyes, sense of grittyness and photophobia.

Signs :- Congestion of palpebral conjunctiva and fornix, thin sticky discharge.

Complications :- Blepharitis, corneal ulcers and opacities.

Treatment 1) General- Avoiding the irritant causes, ex. correction of refractive error etc.
2) Local :- Culture of conjunctival swab and if infection present proper antibiotic should use.3) Drops of zinc sulphate + Acid boric.
4) In more severe cases conjunctival sac has to be painted with 1% silver nitrate soultion..

A/1/b) Acute purulent conjunctivitis

It is acute conjunctivitis with purulent discharge (frank pus from conjunctival sac of eye ball)

Occurs in two forms

a) Gonococcal conjunctivitis - in adults

b) Ophthalmia neonatarum - in new born.

a) Gonococcal Conjunctivitis :-

The causative agent is Neisseria gonorrhoeae, it is due to direct contact of gonorrhoea from genitalia, incubation period - few hours to 3 days. gonococci forms clusters on the surface of conjunctiva due to inflammatory reactions, epithelium degenerates and infection spreads into deeper layers, lead to oedema of sub conjunctival tissue due to accumulation of inflammatory cells and exudates. if the infection is not controlled it spreads into the cornea and causes corneal ulcers, finally healing occurs without scaring

Signs :- Divided into 3 stages

Ist stage :- stage of Infiltration (1 to 5 days)

pain and tender eye ball, bright red coloured conjunctiva, chemosis of conjunctiva, watery discharge, pseudomembrane formation, swelling of eye lids,and with enlarged preauricular lymphglands.

2nd state - stage of blenorrhoea (5 day to several weeks)

Frank pus discharges down to the cheeks, oedema of lids and conjunctiva reduced.

3rd stage - Stage of slow healing

Pain and odema reduces, papillary formation on tarsal conjunctiva, hyperaemic bulbar conjunctiva, reduced discharge- resolution is complete and chronic stage is never attained.

Complications 1) Oedema - ulceration of cornea

2) perforation of cornea 3) Uveitis with hypopyon

Treatment:- a) prophylactic b) curative

Phyphylactic :- Patients belongings should be kept separate, used dressings should be destroyed, sleeping on the side of infection, and the healthy eye should be protected from spreading of infection.

Curative :-

1) eye wash with normal saline - as far as possible.

2) Pencilline eye drops, frequently (10000 units/l - CC of distilled water,) systemic pencilline injections and Broad spectrum antibiotic ointment at nights. to prevent adhesions.

3) If corneal ulcer present 1% atropin sulphate ointment should apply.

B) OPHTHALMIA NEONATARUM

It is a bilateral purulent conjunctivitis occuring in the new born within first three weeks of life.

Causative organisms :- Gonococcus - some times by B. coli, pneumococcus, staphylococcus aureus, streptococcus haemolyticus, virus (inclusion blenorrheoa of new born)

Mode of infection :- During the birth, in the face presentation, the infection spreads from infected vagina by gonococcus.

Clinical picture :- Absence of tears for a month, conjunctival and corneal epithelium become very thin and the remaining Symptoms are like in the adult.

Complications - 1) corneal ulcer -corneal, opacity - maldevelopment of macula and nystagmus.2) Adherent leucoma 3) Anterior staphyloma.

Treatment 1) Prophylactic :- Immediately after bith1% silver nitrate drops or pencilline drops has to put 2) perfect antinatal check up.

II) Curative - like in the adults.

A/1/c) Membranous conjunctivitis:- It is rare, and is characterised by conjunctivitis with membrane formation on the conjunctiva.

Etiology a) ill health following eruptive fevers and unhygienic living condition. (b) Causative agent in majority of cases is coryne bacterium Diphtheriae (klebs - Loeffler Bacilli) which are usually associated with staphylo cocci, and pneumococci - (some times streptococus haemolyticus).

Pathology - 1) Inflammation of conjunctiva 2) Fibrinous exudate is deposited not only on the surface but also within the conjunctiva 3) Exudate forms a membrane on conjunctiva of palpebral and bleeds when removed, necrosis of conjunctiva, ultimately the membrane sloughs off and heals by granulation tissue, during the healing it causes symblepharan (Adhesion between palpebral and bulbar conjunctiva), Ankylo blepharon (Adhesion between lidmargins), Entropion, trichiasis, and corneal ulcer.

Clinical course of MILD CASE :-
1) Oedema of lids 2) Conjunctival congestion 3) muco purulent discharge, 4) Yellowish white membrane on palpebral conjunctiva.

Severe case :- Divided into 3 stages.
1) Stage of infiltration :- It lasts for 5 to 10 days, red, hot, hard, swollen painful eye lids with scanty discharge. Due to stiffness of lid it is impossible to evert, on separating the lids with retracter greyish yellow membrane can be seen with marked hyperaemia, and the Pre auricular lymph glands also enlarges.

2nd stage - stage of suppuration
Pain is less, soft lids, copious discharge and membrane the sloughed off leaving red raw granulating surface.

3rd stage - stage of cicatrization
Healing takes place by granulating tissue and causes complications like symblepharon. Ankyloblepharon, Trichiasis and corneal ulcer.

Treatment 1) Isolation of the patient
2) Culture and sensitivity of conjunctival swab.
3) Crystalline pencilline drops frequently
4) Instillation of Anti diphtheric serum every one hour into eye.
5) 1% atropine sulphate ointment if cornea is involved.
6) Broad spectrum antibiotic ointment at nights.
7) After the membrane has sloughed off eye should be covered with soft contact glasses to prevent adhesion.
8) Anti diphtheric serum 50000 units I.M. twice a day.
9) Crystalline pencilline 5 lack units, I.M. - twice a day.

A/I/d) Pseudo membranous conjunctivitis
1) Formation of false membrane on Tarsal conjunctiva and fornix.
2) Develops only on surface of conjunctiva not within its substance
3) Easily can be removed without bleeding points
4) Signs of Acute catarrhal conjunctivitis present
5) Etiology, clinical picture is same as above but not severe (mild, low virulent).

Treatment :- Like acute muco purulent conjunctivitis

A/I/e) Angular Conjunctivitis
It is commonly associated with nasal discharge, The infecting agent is morax Axenfeld diplobacillus, highly contageous disease, incubation period is 4 days.

Symptoms :- Irritation, itching sensation inthe eyes.

Signs :-1) hyperaemia and Excoriation of epithelium of inter marginal strip of conjunctiva of lid margin, inner canthus and outer canthus.
2) Congestion of bulbar conjunctiva at inner and outer angle.
3) Scanty muco purulent discharge.
4) Excoriation of the skin of surroundings.

Complication :- Marginal corneal infiltration or ulcers

Treatment :- 1) 1% zinc sulphate + 2 % Boric acid drops 3 times a day
2) Tetra cycline eye ointment at bed time.

A/2 Viral conjunctivitis
Several number of viruses can cause conjunctivitis, the conjunctival reactions to viral infection may be variable, chiefly they are as follows:
1) Inflammation of conjunctiva with follicles formation.
2) Oedema of conjunctiva with sub conjunctiva haemorrhages.
3) Simple hyperaemia
4) Ulcers or membrane formation.
5) Some virus cause punctate opacities in the superficial layers or in the deep layers, some disappears and some remains permanently in the cornea.

(A/2) Follicular Conjunctivitis
"Conjunctivitis with follicles formation"
(Follicle = Localised aggregation of lymphocytes in the sub epithelial adenoid layer of the conjunctiva, apearing as tiny round translucent swelling).

Follicles are formed in the following conditions.
a) Folliculosis b) Follicular conjunctivitis
c) Trachoma d) Drug allergy to atropin eserine and pilocarpin

Acute Follicular conjunctivitis :-
Follicle formation with signs of acute catarrhal conjunctivitis, causative agent is virus.
a) Acute herpetic follicular conjunctivitis :-
Causative agent is herpes simplex virus, conjunctival follicles are large, vesicles appear in the cornea (vesicles merge and causes dendritic corneal ulcer)

b) Epidemic kerato conjunctivitis :-

Causative agent is, type 8 adeno virus, Acute follicular Conjunctivitis with marked inflammation of conjunctiva (in the cornea superficial punctate keratitis develops).

c) Pharyngo conjunctival fever

Causative agent is type 8 adeno virus, here acute follicular conjunctivitis is associated with viral pharyngitis and fever .

d) chronic follicular conjunctivitis :- Slight congestion of conjunctiva, scanty discharge, follicles formation at upper tarsal and lower fornix conjunctiva.

A/2/B) Folliculosis

Discrete follicles in the lower fornix, No sign of inflammation or discharge follicles are arranged in parallel rows, conjunctiva in between follicle is clear, it may be due to unhygienic condition and due to refractive error (hyper metropia) it is associated with enlarged tonsils and adenoids.

c) Trachoma (Explained in varthma rogas)

A/2/C) Conjunctivitis in measles :- Inflammed conjunctiva with muco purulent discharge, Kopliks spots may appear on conjunctiva, in virulent cases superficial punctate keratitis develops.

Conjunctivitis in varicella (Chicken pox):-

Phlycten like lesion appears in lidmargin conjunctiva, and at the limbus it may undergo resolution or may ulcerate, marginal corneal infiltration and kerato malacia proceeds.

Conjunctivitis in herpes zoster Ophthalmicus :-

Causative agent is herpes zoster virus, conjunctival congestion with petechial haemorrhages seen, rarely follicle develops, if Ist branch of 5th nerve is involved pustules may form.

Conjunctivitis due to vaccination :-

Causative agent is pox virus, it is due to contamination after contact with vaccination vesicle of another perosn. The clinical features are Oedema, rednes of eye lids purulent Conjunctival discharge, and cornneal complications.

Conjunctivitis inmumps :-

Causative agent is myxo virus, a mild conjunctivitis without marked discharge is seen , interstitial keratitis may also develop

Conjunctivitis in infuenza :-

Causative agent is the ARBOR virus, sub conjunctival haemorrhages with marked congestion of Bulbar conunctiva is seen.

A/3) Conjunctivitis due to bedsonia group of organisms

These group of organisms are not true virus, occupy the middle place between small bacteria and virus.

1) Inclusion blennorrhoea of new born (Inclusion conjunctivitis)
The Causative agent is called TRIC agent
TR = Trachoma ; IC=inclusion conjunctivitis, the causative organism is similar to the trachoma agent which is derived from mother's genital tract.
The Clinical Features are :- Papillary hyertrophy of conjunctiva of the lower fornix, later on follicles formation, signs of acute conjunctivitis with purulent discharge present

2) Swimming bath conjunctivitis :-

It is also known as inclusion blennorheoa of adult, infection spreads in the swimming pool from the genital tract, features of acute conjunctivitis with follicle formation present.

3) Trachoma - explained.

A/4) Conjunctivitis due to specific - infections

1) Tuberculous conjunctivitis

The Infecting agent is tubercular bacillus, types
a) one or more ulcers in conjunctiva (Palpebral and bulbar)
b) Small nodules appear in the conjunctiva.
(c) Hyper trophic type - Hypertrohied granulation tissue at fornix or tarsal conjunctiva.
Definite diagnonis is possible only by histological examination of conjunctival lesion

2) Syphilitic conjunctivitis:- The Conjunctiva may be affected in all stages of syphilis.

Ist stage :- Extra genital chancre in conjunctiva, with swelling of the eye lid.
2nd stage - A simple conjunctivitis is associated
3rd Stage - Gummata may develop in the conjunctiva, it breaks down and produce indolent ulcers.

3) Conjunctivitis in leprosy

In nerve type of leprosy, due to affect of sensory nerves, conjunctiva may be exposed and cause hyperaemia of conjunctiva with catarrhal conjunctivitis and In lepromatous leprosy lepromata may develop in the conjunctiva.

4) Tularensis conjunctivitis :- The Causative agent is brucella tularens, small necrotic ulcers develop in conjunctiva with oedema of eye lids and with regional Lymphnodes enlargement

(5) Parinaud's conjunctivitis:- Granuloma formation in the conjunctiva with enlargement of regional lymph glands.

B) Allergic conjunctivitis.

Inflammation of conjunctiva due to allergic reactions, It may occur in three forms.

1) Simple allergic conjunctivitis
2) Phlyctenular conjunctivitis
3) Vernal conjunctivitis or spring catarrh

1) Simple allergic conjunctivitis:-

It occurs due to exogenic and endogenic allergens.

Exogenous allergens :- Pollens, vegetable and animal dust and drugs like atropin, eserin, pilocarpin

Endogenous Allergens :- Bacterial products from a septic focus particularly due to staphylococcus.

Symptoms :- (1) irritation and itching of the eyes 2) photo phobia and 3) watering.

Signs : 1) Marked Hyperaemia of conjunctiva 2) Chemosis of conjunctiva 3) scanty watery discharge 4) Eosinophils in conjunctival smear 5) Oedema of lids.

Treatment :- 1) Allergen has to be removed
2) Hydrocortisone acetate 1% ointment at bed time.

2) Phlyctenular conjunctivitis

It is an allergic inflammatory reaction of the conjunctiva to some endogenous toxin which is bacterial in origin.

Exciting factor :- Unhygienic condition, tuberculo toxin, and staphylo coccus.

Symtoms Discomfort in the eye, irritation, reflex lacrimation (Photophobia if cornea involves)

Signs :- 1) One or multiple phlyctens formation on conjunctiva at limbal area 2) Pinkish white nodule, 1 to 4 mm in size originates a little distance from limbus, the bulbar conjunctiva surrounded by phlycten is congested and rest of the conjunctiva is clear.3) lacrimation present but no discharge.4) In the presence of secondary infection total conjunctiva becomes congested. 5) It associated with enlarged tonsils and cervical glands.

Pathology :- The phlycten is the compact mass of lymphocytes and poly morphs, underneath the epithelium, phlycten ulcerates and heals by granulation (Very little scar formation), ulcerates in to cornea causing phlyctenular Keratitis.

Treatment : - If no secondary infection.
1) Hydro cortisone acetate 1% drops frequently,
2) If secondary infection present - trea'ment should be given like acute muco purulent conjunctivitis.
3) if cornea is involved 1% atropine sulphate ointment has to apply.
4) Treatment of Tuberculosis or any other septic focus
5) Vitamins and proper nourishment.

3) Spring cattarh or vernal conjunctivitis

It is hypersensitive reaction of conjunctiva to exogenous allergens. (Prevale in summer and subsides in winter).

Symptoms :- Itching, burning, photophobia, Lacrimation

Signs :- Palpebral type & bulbar type (2 types)

Palpebral type :- Hard, flat, bluish white papillae separated by furrows, giving a coble stone appearence, white ropy conjuntival discharge with eosinophils.

Bulbar type :- it is less common there is gelatinous thickned to accumulation of tissue around the limbus

Treatment : Cold water eye wash, disodium cromo glycate drops reduce itching, and Dexamethosone drops for best relief.

5) ADHIMANTHA (GLAUCOMA)

Severe pain inthe eye is the prime symptom of Adhimantha, it is described as the complication of abhishyanda vyadhi.

1) Vataja Abhishyanda causes vataj adhimantha main symptoms is pricking pain in the eyes.
2) Pittaj Abhishyanda cuases pittaja Adhimantha, main symptom is burning pain in the eye
3) Kaphaja Abhishyanda causes kaphaj adhimantha, main symptom is heavy ness and itching sensation in the eye
4) Rakthaja Abhishyanda causes Raktaja Adhimantha, main symptom is Raktha prakopa vedana.

Samanya Lakshanas :-

1) Severe pain in the eyes like scooping it from the orbit, 2) Crushing type of pain or churning type of pain (Manthana vatha shoola)

3) Half headache (Arthava bhedak) 4) Vataj complications

Types of adhimantha

1) Vatika Adhimantha
2) Piithika Adhimantha
3) Kaphaja Adhimantha
4) Rakthaja Adhimantha.

1) VATIKA ADHIMANTHA

(Acute congestive glaucoma)

It is a disease in which the patient have scooping type or breaking type or spastic type or pricking type or cutting type of pain in the eyes, exudations, foreign body sensation, extra growths, dirty appearance with Aadmana (increased tension in the eye ball), Kampana (Shivering) and half headache.

Vagbhata added the points like karna nada (Tinnitus), churning type of pain in head eye and root of the nose, and with giddiness

Chikitsa:- Like vataja abhishyanda, (sneha sweda siramokshana, (Lalata sira vyadana) virechana and vasti; seka Ashchyotan Anjana Tarpana, putapaka dhooma, Nasya, shiovasti etc. has to do.)If the disease is not controlled with above treatment principles, vagbhata suggested " Daha karma" at and above the " Bhru".

Varthi Anjana

1) vataja :- Rajatha patra should be painted with go dadhi, it should become bluish and get it dried and grind with masthu, prepare varthi for Anjana.

2) PITTAJA ADHIMANTHA

Acute congestive glaucoma

It is sarvagatha sadhya vyadhi, The signs & symptoms are

1) eye spread with red capillary net (Raktha raajeechitham) 2) watering of eyes. (Netra srava) 3) severe Burning sensation (Burning pain like burning with fire or chemical or kshara) 4) Hyperaemia of eyes like yakruth (chachlate colour)5) Oedema of eye lids (Varthma shopha) 6) Perspiration (Swedana) 7) Burning sensation of the head (Shirodaha) 8) Murcha (unconscious state) 9) Visualises the things in yellow colour.

Chikitsa ;- Like pittaja Abishyanda

Anjana for pitta and Raktha adhimantha :- Buds of jathi pushpa, Shankhanaabhi, Triphala, Yastimadu, Bala moola twak, should grind with Aakashodaka (Rain water) varthi is prepared for Anjan.

3) KAPHAJA ADHIMANTHA

(Simple chronic glaucoma or chronic congestive glaucoma)

It is sarvagatha sadhya vyadhi, signs & symptoms are.
1) Netra shotha (oedema) 2) srava (Lacrimation) 3) Kandu (itching) 4) cool, heavy sticky discharge comes 5) Harshana (hypersensitvity) 6) shiro ruja (headacha) 7) Visualise the things as smoky, dirty and imperfect (Nose apears as oedematous) 8) difficulty in visualisation and opening of eye lids 9) Oedema of nose. **Vagbhata** added a peculiar sign, that is " **Natham Krishnam - unnatham shukla mandhalam** "Sunken cornea and bulged sclera.

Chikitsa - Like kaphaja Abhishyanda

Anjana - Saindhava lavana, Triphala, Trikatu, shankha nabhi samudra phena, shyleyaka sarjarasa, should grind with water, and varthi is prepared for Anjana.

RAKTHAJ ADHIMANTHA

(Congestive glaucoma or secondary glaucoma)

It is Sarva gatha sadya vyadhi, the signs & symptoms are.

1) Sparshanaakshama (Tenderness - unbearable pain)
2) Eyes becomes red and discharges red secretion
3) Visualises the objects in Red colour (Agnivath)
4) Krishna mandala appears as dipped in the blood like reeta phala (Arista phala).
5) Severe pricking pain & burning sensation in the eyes and head.

Vagbhata :- The pain is experienced at Shankha, dantha, kapola, lalata,
Chikitsa :- Like rakthaja Abhishyanda

Adhimantha Sadhya Asadhyatha

If it is not treated in time causes blindness within the following duration

as per Sushrutha	Vataja, 6 days	Pittaj-1 day	Kaphaj,7 days	Rakthaj, -5 days
as per Vagbhata	5 days	1 day	7 days	3 days

GLAUCOMA

Increased intra ocular pressure which is created by solid, liquid contents of eye and the elasticity of its coats, is known as Glaucoma.

Normal intra ocular pressure is 16 to 23 mm Hg. by schiotz tonometer, the solid and semi solid contens which are responsible for the maintenance of intra ocular pressure are, Lens, vitreous, Uveal tract and retina and the Liquid contents which are responsible for the maintenance of intra ocular pressure are blood and aqueous humour.

Changes in the volume of above may lead to raised intra ocular pressure (Glaucoma) "Normal pressure is required for the maintenance of the optical properties of refracting surfaces".

Physiological variations of I.O.P pesent in 24 hours :-
The difference should not be more than 5 mm Hg.

1) Early morning pressure is maximum.2) sharp fall soon after sun rise.
3) Gradually decreases upto evening4) First 6 hours of night gradually raises
5) Increases in the mid night and becomes maximum upto early morning.

Factors resposible for rise of Intra ocular presure

1) Increased aqueous production
2) Decreased aqueous out flow due to obstruction of its drianage
3) Increased blood volume or decreased venous out flow.
5) External pressures on the eye. ball.

Classification of Glaucoma

- Glaucoma
  - Congenital (infantile glaucoma) or (Buphthalmos) or Hydrophtalmos
  - Acquired
    - Primary (without obvious cause)
      - Wide angle or Chronic simple glaucoma (CSG)
      - Closed angle glaucoma or Congestive glaucoma (CAG)
    - Secondary (with obvious cause)

Note :- When sense of perception and projection of light is lost, commonly in the final stage of Glaucoma is termed as absolute glaucoma.

I. INFANTILE GLAUCOMA (CONGENITAL)
(Buphthalmos - Hydrophthalmos)

Causative mechanism :-
Congenital abnormality at the angle of anterior chamber, absence of canal of schlemm, causes Aqueous obctruction in the eye ball, and leads to increased intra ocular pressure.

Symptos : 1) Photo phobia 2) Defective vision.

Signs : 1) epiphora 2) Blepharospasm 3) intolerance to light 4) hazy cornea 5) oedemaof cornea 6) elongated (oval) eye ball (resembles the eye of an ox, so only termed as buphthlmos) progressive enlargement of cornea (becomes 12 to 14 mm diameter instead of 10.5 mm) and sclera (becomes thin)
7) Anterior chamber is deep
8) Lens become flat and may be subluxated
9) Iris becomes tremulous
10) Cupping of optic disc
11) Error of myopia due to elongated eye ball
12) Raised intra ocular pressure.

Treatment :- Surgical correction of Aqueous passage.

2) PRIMARY WIDE ANGLE GLAUCOMA OR CHRONIC SIMPLE GLAUCOMA (CSG)

No obvious cause can be explained for the rise of pressure 2) The angle of anterior chamber remains wide .

Causative mechanism :-
Actual cause is not known but the rise of pressure may be due to some changes in the trabeculae, schlemm's canal or in the Exist channels from schlemm's

Symptoms :
1) Mild headacha 2) eye ache 3) Changes in the lens accommodation (require frequent change of presbyopic glasses) 4) defect in field of vision 5) gradual dimness of central vision 7) Night blindness in the later stages.

Signs :- (No early signs)1) Hazy cornea 2) Sluggished pupil reaction 3) Rise of Intra ocular pressure 4) cupping of optic disc 5) Defect in the field of vision 6) In the later stages central vision also affected and eye becomes complete blind 7) Angle is wide

Treatment :- 1) Pilocarpine nitrate (miotic) 2% drops.
2) Diamox 250 mg caps Bid. or Tid.

Operations :- 1) Trabeculectomy b) Iridencleisis
c) Elliots sclero corneal trephine.

PRIMARY CLOSED ANGLE GLAUCOMA
(Acute congestive Glaucoma)

Intra ocular pressure is raised as a result of obstruction in the out flow of the aqueous humour due to narrowing of the angle of Anterior chamber.

Probabilities for the occurence :-

1) Small eye (hyper metropic eye)
2) Shallow anterior chamber
3) Bigger ciliary body & lens
4) Forward displacement of Iris
5) Cloudy day (rainy season) pupillary dilatation causes obstruction of angle due to dim light.

Clinical course:-

a) Prodromal stage.
b) Phase of constant instability
c) Acute congestive attack
d) Chronic congestive attack
e) Stage of absolute glaucoma

a) Prodromal stage :-

Symptoms :- Blurring of vision with haloes around the light and mild headache.

Signs :- 1)Sudden rise of I.O.P. for a short period, no congestion, slight corneal oedema, pressure increases due to stress, strain and in the dark illumination.

(b) phase of constant instability:-

signs and symptoms:- The features described above become more and regular, seviority appears more at evenings, and quickly comes to normal by rest or sleep.

c) Acute Congestive attack :-

Symptoms :- Severe eye ache, headache, marked vision loss, (presence of only perception and projection of light) photophobia, and Lacrimation.

Signs :- 1) Oedema of eye lids 2) Ciliary & conjunctival congestion 3) hazy and insensitive cornea 4) shallow anterior chamber 5) moderately dilated pupil 6) Iris is discoloured 7) Marked rise of intra ocular pressure 8) eye ball is tender 9) Ophthalmoscipic examination is not possible due to corneal oedema.(Optic disc is congested, no cupping) 10) Vision is markedly reduced, only perception and projection of light present.11) The associated systemic disturbances are 1) Vomiting 2) Fever 3) irregular pulse etc.

d) Chronic congestive stage : -

Signs :- 1) eye remains congested and irritable.
2) Tension remains permanently elevated
3) Field defects like previous.
4) Cupping of the optic disc
5) Vision remains deppressed.

Note :- If the treatment not given evena at this stage, it passes into absolute glaucoma.

E) Stage of absolute glaucoma

Signs :-

1) The eye completely become blind, (no perception of light)
2) Irregular venous anastomosis around the limbus (Medusa head)
3) Cornea is hazy and insensitive
4) Anterior chamber is very Shallow
5) Iris atrophy
6) Pupil is dilated, no reaction to light
7) Optic disc is deeply cupped
8) Tension is very high and eye becomes stony hard.
9) The Other changes are :- Ulceration of cornea, glaucomatous pannus, equatorial staphyloma, panophthalmitis, phithisis bulbi.

Treatment :- In Ist and 2nd stages (1) Miotics (pilocarpine drops 2%, (2) Peripheral iridectomy operation.

in 3rd stage : 1) Miotics 2) Diamox 250 mg Tid, 3) Treatment for pain & congestion 4) peripheral irridectomy

4rth Stage :- Trabeculectomy or iridencleisis
5th Stage : Enucleation of eyeball.

SECONDARY GLAUCOMA

Secondary glaucoma arises because of pre existing disease

Causes 1) Due to inflammation :-
Corneal ulcer, uveitis, acute scleritis, endophthalmitis, oribital cellutlitis etc.

The angle of anterior chamber is blocked because of inflammatory exudates and causes glaucoma.

2) **Post inflammatory :-**
a) Intumescent cataract - causes shallow anterior chamber and causes glaucoma
b) Burst morgagnian cataract causes closer of angle, so causes glaucoma
c) Sublauation of Lens of flocculent Lens matter, causes glaucoma. (Iris being pushed forwards)
4) Due to intra ocular haemorrhage
5) glaucoma due to intra ocular tumours
6) Post operative glaucoma ex :in Aphakia.

Treatment :- 1) Treat the cause
2) Paracentesis
3) If intra ocular tumours present, enucleation has to do.

9) SASHOPHA AKSHI PAKA
(Cellulitis of eye ball or uveitis or Panophthalmitis)

It is sarva gatha, sannipathaja, vyadana sadhya vyadhi .

Signs & Symptoms :-
Eye becomes coppery red colour (Pakwa Udumbara sannibham) and assoicate with kandu (itching), Ashru srava (Lacrimation), daha (Buring sensation), upadeha (Stickyness), Harshana (Sensitivity), Toda (Pricking pain) gurutwa (Heavyness), Red oedema with frequent Sticky hot or sticky cool discharge.

As per Vagbhata - It is due to " Tridoshas + Raktha vitiation"
Note :- Sa shopha Akshi paka is sadhya vyadhi but panophthalmitis is asadhya vyadhi so it can be compared to Uveitis (Inflammation of second layer of eye ball) Cellulitis of eye ball.

10) ASHOPHA AKSHI PAKA

It is Tridoshaja, sarvagatha, Vyadana sadhya vyadhi
Except shotha all the symptoms of sashopha Akshi paka are present in this disease. (Vagbhata called it as " Alpa shopha akshi paka")

Treatment of Sashopha and Ashopha akshi paka :-
" Treatment is like Rakthaj abhishyand (Sira vyadnasadhya vyadhi) "

Treatment principle :- 1) Snehan 2) Swedan 3) Sira vyada (at Apangasta or upanasika sira)

Sthanika upacharas Local treatments :-
Parisheka Aashchyotan, Nasya, putapaka, anjana, etc.

Anjana yoga :- 1) Ghritha + Saindhava lavan which is kept in a copper vessel, has to use as Anjan.
2) Sura or Aasava + Saindhava lavan which iskept in a copper vessel for a month, has to use as Anjan.
3) Dadhi which is kept in a copper vessel for a month has to use as Anjan.
4) Raktha mokshana, then apply kamsya malam + ghritam
6) Madhuka sar + gyrika + madhu, as Anjan.
7) Jathi Pushpanjan :- (Jathi pushpa, saindhavalavan, Aardrak, pippali, vidanga + Honey.)

Aashchyotan yoga :- 1) Shunti + stanya, add saindhava lavana or Ghritha,kept for a month, then use as Aashchyotan
2) Daruharidra + prapundareeka kwatha as Aashchyotan.

Treatment principle as per vagbhata (Astanga Hrudya):- 1) Sneha - Sweda - Raktha mokshana then again snehan and rechana with Nishotha Kwatha + Draksha + Hareetaki + Ghritha.
2) Swetha lodhra fry in Ghritha, pack in a cloth dip in the lukewarm water, use the lekewarm water parisheka, for the reduction of pain.

Sandhava yogas especially explained to get relief from redness,pain , and foreign body sensation.

1) Take the essence of Tamra in Gomutra, Should keep in a Iron vessel, fumigate with ghritha and use as anjana.
2) Go dadhi (masthu), collect in the copper vessel, add pippali, saindhava lavana, mix well and use as anjana.
3) Take shankha and stanya in a copper vessel, fumigate with shami patra or yava which is dipped in the ghritha, and use as anjana, it reduces foreign body sensation and pain in the eye.
4) Udumbhara phalam + stanyam, collect in Iron vesel, fumigate with shami patra which is dipped in the ghritha, and use as anjan, it reduces pain burning and lacrimation.

5) Shigru pallava swarasa, collect in copper vessel, fumigate with ghritha and use as Anjana.
6) Mruth kapala collect in the Kamsya vessel, do bhavana in Tilakwatha, fumigate with Nimba patra which are dipped in ghritha and used as anjan
7) Talisadi Gutikanjan with stanyam.
8) Vyaghradi Kalka Anjana.

Note :- After the above anjana applications, aschyotana should do with stanya

11) HATHADHIMANTHA
(Atrophic bulbi or Phthisis bulbi due to acute congestive glaucoma)

It is a sarva gatha, vataja, asadya vyadhi, arises by neglecting the vataja adhimantha.

Netra sosha (atrophy of eye ball) & Teevra vedana (severe pain) are the main features of the disease

As per Vagbhata : - An ulcer forms in the eye that causes loss of vision and severe pain in the eye ball, it occurs by neglecting vataj adhimantha

It is of two types

1) Vitiated vata by filling the blood vessels, pushes the eye ball forward andproduces severe pain (Pricking, crushing) in the eye (inter calary staphy loma due to increased intra occular pressure)

2) Vitiated vata suppress the Teja bala and agni of the eye ball by that the eye ball shrinks like the lotus.(Atrophic bulbi or phthisis bulbi)

It is Asadhya vyadhi but can be treated like vataj adhishyanda vyadhi.

12) ANILA PARYAYA (VATA PARYAYA)
(occular pain due to chronic glaucoma or Trigeminal neuralgia)

It is sarvagatha vataj, vyadana sadhya vyadhi,

The Vitiated vata causes severe pain, some times in the Pakshma. some times in Bhru and some times in the eye ball, is known as vataparyaya or anila paryaya (Shifting pain).

Vagbhata's Additional points :- Eye ball becomes smaller (microphthalmas) Treatment is like vataj Abhishyanda and anyathovata.

13 ANYATHO VATA
(Reffered pain in the eye or Spenoidal sinusitis)

It is sarvagatha, vataja ,vyadana sadhya vyadhi,

The Vitiated vata causes severe pain in the eyes or in the bhru (Root of by the nose) by spreading from peripheral parts like karna (ears), Shira (head), manya (Sides of neck) greeva (neck), hanu (jaws) etc. (Referred pain in the eye from other parts)

Chikitsa :- 1) Anila paryaya and Anyathovatha should be treated like vataja Abhishyanda.
2) Sneha, sweda, Raktha mokshana,vasti, sneha Rechan, Tarpan, putapaka Bhojan poorva ghrithapana), and milk with meals .
3) Oral intake of ghee, prepared from veeratarvadi Ksheera
4) Oral intake of ghee, prepared from Mesha shrungi.

14) SHUSHKAAKSHI PAKA
(Xerophthalmia)

It is sarvagatha, vataja, Aushada (Ashastra Krutha) sadhya vyadhi.

Eye lids are closed (dropped) and are opened with difficulty, lids become hard rough, and eye looks dirty lustreless

Vagbhata :- Vata + Pitta vitiates, eye lids become hard rough and causes difficulty in opening and closing the lids, it associate with foreign body sensation, pricking pain, cutting pain, exudation, suppuration and the patient likes cool applications.

Treatment :-1) Ghrithapanam (oral administration of Ghee), 2) Jeevaneeya ghritha Tarpan, 3) Brumhana taila or Anutaila nasyam, 4) Saindhava lavana +Lukewarm milk for eye wash (pariseka), 5) Bidala with fried lodha+ghritha ,

6) Anjana : - 1) Anjana with Shunti + Stanya + Ghritha
2) Anjana with Anupa vasa(Animal fat) + Shunti or saindhava, Lavan
3) Saindhava Lavan + Deva daru + Shunti + mathu lunga swarasa + ghritha Raskriya anjana - with stanya.
4) Anjana with haridra Devadaru, saindhava, lavana ghritha and madhu
5) Anjana with Kesha masi (Hairs) + Ghritha (Masi is prepared in mallaka samputa).
6) Shunti + Saindhava lavana, Rasa kriyanjan with ghritha
7) Anjana with Madhu, saindava lavan and gyrica.

15) AMLADYUSHITHA (Allergic chemosis)

It is sarvagatha pittaja aushada sadhya vyadhi,(Ashastra Krutha)

Eye becomes inflammed, oedema of eye ball occur with bluish red lines due to in take of Amla Katu, lavana tredominent diet is known as Amla dyushitha.

In Astanga hrudaya it is termed as " Amloshitha ",Vagbhata added the points like shotha (oedema) Raga (hyperaemia), srava (Exudation), paka (suppuration, jwalana (Burning), Ashrusrava (Lacrimation) and lustre less eye.

Treatment :- like pittaj Abhishyanda but Raktha mokshana is contra indicated. (Triphala ghritha Tilwaka ghitha purana ghritha roral administration for virechan, then application of sheetha anjanas are advised).

16) SIROTHPATHA
(Allergic Conjunctivitis, angio neurotic Oedema or episcleritis.)

It is sarvagatha rakthaja vyadan Sadhya vyadhi, eye suddenly becomes red and spread with capillary net, may or may not contain the pain and the disease subsides naturally .

" The occurence the resolution of the the disease is natural ",

Chikitsa 1) Raktaja Abhishyanda Chikitsa. 2) Raktha mokshana. 3) Anjana with Madhu + Ghritha. 4) Anjana with Saindhava lavan + Kaseesa + Stanya. 5) Anjanan with Swarna gyrica + madhu. 6) Anjana with Shankha nabhi, manashila, Tuttha Daruharidra, saindhava lavana + madhu. 7) Anjana with Sura swetha maricha makshika and sireesha pushpa.

17)SIRA HARSHA
(Allergic hyperaemia Acute orbital cellulitis)

It is sarvagatha, Rakthaja, vyadan, sadya vyadhi, it occurs due to neglecting the sirothpatha in which red sticky discharge comes from the eyes and patient cannot able to see the objects.

Treatment :-
1) Rakthaja Abhishyanda Chikitsa. 2) Anjana with Phanitha + Madhu. 3) Anjana with Rasanjan + madhu. 4) Anjana with Kaseesa, Saindhava lavan. + Madhu. 5)Anjana with Vetramla + Stanya + Phanitha+ Saindhava lavan

Note :- Sirothpatha and sira harsha are the symptoms observed in somany lesions of conjunctiva, either inflammatory or allergic or traumatic (episcleritis- scleritis).

Sarvagatha rogas (Susrutha)

Total 17 diseases

I) 1 Disease Asadya (Hathadhimanda)

II) 2 Diseases - Ashastra kruth, they are,

a) Shuskakshi paka

b) Amldyushitha

III) 14 Diseases - Vyadana sadya vyadhies, They are
4 Abhishyanda

4 Adhi manda

2 Akshi paka (Sashopha - Ashopha)

Anyatho vatha

Anila paryaya

Siroth patha

Sira harsha

Sarva gatha roga according to vagbhata :-

Total -1 6

1) 2 Diseases are Asadya

a) Hathadhimanda

b) Akshi Pakatyaya

II) 14 diseases sadyam (rest of the diseases)

S.No.	Name of the disease Modern Name	Vitated Dosha Prognosis	Clinical features	Treatment Principle
1.	Vataj abhishyanda (sub acute catarrhal Conjunctivitis)	Vataj	Patient feels head ache, Pricking pain in the eyes, foreign body sensation, cool lacrimation and desires hot therapy.	1) Vyadan Sadya 2) Aashchyotan Anjan etc.
2.	Pittaja Abhishyanda (Acute catarrhal Conjunctivitis)	Pittaja Sadya	Patient feels burning pain Suppuration in the eyes, eyes appear in yellow colour with hot lacrimation and desires cool therapy.	1) Vyadan Sadya 2) Pittahara Aashchotan anjana etc.
3.	Kaphaj Abhishyanda (Acute mucopurulent conjunctivits	Kaphaj Sadya	Patient feels heavyness oedema itching, stickyness, coolness, the eyes appears in white colour and desires hot therapy.	Vyadan sadya 2) Kaphara Ashchyotan anjana etc.
4.	Raktaj Abhishyanda (Acute mucopurlent Conjunctivits)	Raktaj Sadya	Features like pittaja Abhishyanda in addition to those, red eyes red lacrimation with capillary net appearance	1) Vyadan Sadya. 2) Rakta hara Aashchyotan Anjan etc.
5.	Vataj Adhimantha (Acute congestive glaucoma)	Vataj Sadya	Head ache, Pricking crushing Scooping and breaking type of pain in the eye ball, foregn body sensation, Lacrimation, admana Kampanan. It occur by neglecting vataj abhishyanda.	1) Vyadan Sadya 2) Vataja abhishyanda treatment 3) Daha at above bhru.
6)	Pittaj Adhimantha (Acute congestive glaucoma)	Pittaj Sadya	It occurs by neglecting Pittaj Abhishyanda, capillary net, buring, hyperamia, oedema of eye lids, purspiration and unconscious ness the patient visualises the things in yellow colour.	1) Vyadan sadya
7)	Kaphaj Adhimantha (chronic simple glaucoma)	Kaphaj Sadya	It occurs by neglecting the kaphja abhishyanda, oedema, Lacrimation, Itching sensation coolness, heavness, stickyness, sensitivity in the eye ball, Headache and visualises the things in white colour.	1) Vyadan Sadya

8)	Raktaj Adhimantha	Raktaj	It occurs by neglecting rakthaja abhishyanda, tenderness, unberable pain, redness, redexudation, and visualises the objects in red colour.	1) Vyadan Sadya
9)	Sashopha Akshipaka (Uveitis, cellulits of eye ball, pain ophthalmitis)	Tridosh (Rakthaj), (Sadya)	Red oedema like pakwajambu Phala, associated with pain, itching, exudation, stickyness in the eye ball.	1) Vyadan Sadya
10)	Ashopha Akshipaka	Tridosh	Except shopha all the symptoms are similar to above.	Vyadan Sadya
11)	Halthadhimantha (Atrophic bubi , Phthisis bulbi, acute congestive glaucoma)	Vataj Asdaya	Pain, atrophy of eye ball, forward protrusion of eye ball, shrinkage of eye ball.	Asadya
12)	Anila paryaya (Ocular shifitng pain, trigemenal neuralgia)	Vataj Sadya	Severe shifting pain in the pakshma, bhru, eye ball.	Vyadan Sadya
13)	Anyatho vata (referred pain in the eye ball)	Vataj Sadya	Pain referred to bhru eye from ear, head neck & jaw.	Vyadan sadya
14)	Shushkakshi paka	Vataj Sadya	The closed eyes are opened by diffucult, hard rogh, lustreless, dirty eye ball.	Aushada sadya
15)	Amladyushutha (Allergic chemosis)	Pittaja Sadya	Inflammation of eye ball due to in take of amla, lavan, katu, ahara	Aushada Sadya
16)	Sirothpath (Allergic conjunctivitis)	Rakthaj Sadya	Eye suddenly becomes red with capillary net, subside naturally	Vyadan Sadya
17)	Siraharsha (Allergic hyperaemia)	Rakthaj Sadya	Photophobia, red sticky exudation occurs by neglecting sirothpath.	Vyadan Sadya

दृष्टि का प्रमाण

कृष्णात् सप्तममिच्छन्ति दृष्टिदृष्टिविशारदाः ॥ (सु॰ उ॰ 1/13)

नवमस्तारकांशो दृष्टिः ॥ (सु॰ उ॰ 35/12)

मसूरदलमात्रां तु पंचभूतप्रसादजाम् ॥
खद्योतविस्फुलिङ्गाभामिद्दां तेजोभिरव्ययैः ॥
आवृतां पटलेनाक्ष्णोर्बाह्येन विवराकृतिम् ॥
शीतसात्म्यां नृणां दृष्टिमाहुर्नयनचिन्तकाः ॥ (सु॰ उ॰ 7/3)

नेत्र पटल

द्वे वर्त्मपटले विद्याच्चत्वार्यन्यानि चाक्षिणि ॥
जायते तिमिरं येषु व्याधिः परमदारुणः ॥ (सु. उ. 1/17)

तेजोजलाश्रितं वाह्यं तेष्वन्यत् पिशिताश्रितम् ॥
मेदस्तृतीयं पटलमाश्रितं त्वस्थि चापरम् ॥
पंचमांशसमं दृष्टेस्तेषां बाहुल्यमिष्यते ॥ (सु॰ उ॰ 1/18)

प्रथम पटलगत तिमिर

सिराभिरभिसंप्राप्य विगुणोभ्यन्तरे भृशम् ॥
प्रथमे पटले दोषो यस्य दृष्टौ व्यवस्थितः ॥
अव्यक्तानि स रूपाणि सर्वाण्येव प्रपश्यति ॥ (सु॰ उ॰ 7/6)

सिरानुसारिणि मले प्रथमं पटलं श्रिते ।
अव्यक्तमीक्षते रूपं व्यक्तमप्यनिमित्ततः ॥ (अ. हृ. उ. १२ अ.)

द्वितीय पटलगत तिमिर

दृष्टिर्भृशं विह्वलति द्वितीयं पटलं गते ॥
मक्षिकामशकान् केशांजालकानि च पश्यति ॥
मण्डलानि पताकांश्च मरीचिः कुण्डलानिच
परिप्लवांश्च विविधान् वर्षमभ्रं तमांसि च ॥
दूरस्थानिच रूपाणि मन्यतै च समीपतः
समीपस्थानि दूरे च दृष्टेर्गोचरविभ्रमात् ॥
यत्नवानपि चात्यर्थं सूचीपाशं न पश्यति ॥ (सु॰ उ॰ 7/7,8,9,10 अ॰)

प्राप्ते द्वितीयं पटलमभूतमपि पश्यति ॥
भूतं तु यत्नादासन्नं दूरे सूक्ष्मं च नेक्षते ॥
दूरान्तिकस्थं रूपं च विपर्यासेन मन्यते ॥
दोषे मण्डलसंस्थाने मण्डलानीव पश्यति ॥
द्विधैकं दृष्टिमध्यस्थे बहुधा बहुधास्थिते ॥
दृष्टेरभ्यन्तरगते ह्रस्ववृद्दविपर्ययम् ॥
नान्तिकस्थमधःसंस्थे दूरगं नोपरिस्थिते ॥
पार्श्वे पश्येन्न पार्श्वस्थे तिमिराख्योयमामयः ॥ (अ. हृ. उ. १२ अ.)

तृतीय पटलगत तिमिर

ऊर्ध्वं पश्यति नाधस्तात्तृतीयं पटलं गते ॥
महान्त्यपि च रूपाणिच्छादितानीव वाससा ॥
कर्णनासाक्षि युक्तानि विपरीतानि वीक्षते ॥
यथादोषं च रज्येत दृष्टर्दोषे वलीयसी ॥
अधः स्थिते समीपस्थं दूरस्थं चोपरिस्थिते ॥
पार्श्वस्थिते तथा दोषे पार्श्वस्थानि न पश्यति ॥
समन्ततः स्थिते दोषे संकुलानीव पश्यति ॥
दृष्टिमध्यगते दोषे स एकं मन्यते द्विधा ॥
द्विधास्थिते त्रिधा पश्येद् बहुधा चानवस्थिते ॥
तिमिराख्यः स वै दोषः (सु. उ. अ. 7/11,12,13,14)

प्राप्नोति काचतां दोषे तृतीयपटलाश्रिते ॥
तेनोर्ध्वमीक्षते नाधस्तनुचैलावृतोपमम् ॥
यथावर्ण च रज्येत दृष्टिर्हीयेत च क्रमात् ॥

(अ. हृ. उ. १२ अ.)

चतुर्थ पटलगत तिमिर

सर्वै दोषः चतुर्थ पटलं गतः ॥
रुणद्दि सर्वतो दृष्टिं लिङ्गनाशः स उच्यते ॥
तस्मिन्नपि तमोभूते नातिरूढे महागदे ॥
चन्द्रादित्यै सनक्षत्रावन्तरीक्षे च विद्युतः ॥
निर्मलानि च तेजांसि भ्राजिष्णुनि च पश्यति ॥

(सु. उ. 7/15,16,17)

तथाप्युपेक्षणमाणस्य चतुर्थ पटलं गतः ॥
लिङ्गनाशं मलः कुर्वन् छादयेद् दृष्टिमण्डलम् ॥

(अ. हृ. उ. १२ अ.)

विभिन्न तिमिर लक्षण

तत्र **वातेन** रूपाणि भ्रमन्तीव स पश्यति ॥
आविलान्यरुणाभानि व्याविद्धानि च मानवः ॥
पित्तेनादित्यखद्योतशक्रचापतडिद्गुणान् ॥
शिखिबर्हविचित्राणि नीलकृष्णानि पश्यति ॥
कफेन पश्येद्रूपाणि स्निग्धानि च सितानि च ॥
गोरचामरगौराणि श्वेताभ्रप्रतिमाणि च ॥
पश्येदसूक्ष्माण्यत्यर्थ व्यभ्रे चैवाभ्रसंप्लवम् ॥
सलिलप्लावितानीव परिजाड्यानि मानवः ॥
तथा **रक्तेन** रक्तानि तमांसि विविधानि च ॥
हरितश्यावकृष्णानि धूमधूम्राणि चेक्षते ॥

(सु. उ. 7/18 से 22)

1. वातज तिमिर

तत्र वातेन तिमिरे व्याविद्धामिव पश्यति ॥
चलाविलारुणाभासं प्रसन्नं चेक्षते मुहुः ।

जालानि केशान् मशकान् रश्मींश्चोंपेक्षितेत्र च ॥
काचीभूते दृगरुणा पश्यत्यास्यमनासिकम् ॥
चन्द्रदीपात्यनेकत्वं वक्रमृज्वपि मन्यते ॥
वृद्धः काचःदृशं कुर्याद्रजोधूमावृतामिव ॥
स्पष्टारुणाभां विस्तीर्णां सूक्ष्मां वा हतदर्शनाम् ॥
स लिङ्गनाशः

(अ. हृ. उ. १२ अ.)

2. पित्तज तिमिर

पित्तजे तिमिरे विद्युत्खद्योतदीपितम् ।
शिखितित्तिरिपत्राभं प्रायो नीलं च पश्यति ॥
काचे दृक् काचनीलाभा तादृगेव च पश्यति ।
अर्केन्दुपरिवेषाग्निमरीचीन्द्रधनूंषि च ॥
भृङ्गनीला निरालोका दृक् स्निग्धा लिङ्गनाशतः ।
दृष्टिः पित्तेन ह्रस्वाख्या सा ह्रस्वदर्शिनी ॥
भवेत् पित्तविदग्धाख्या पीता पीताभदर्शना ।

अ. हृ. उ. 12 अ

3. कफज तिमिर

कफेन तिमिरेप्रायः स्निग्धं श्वेतं च पश्यति ॥
शङ्खेन्दुकुन्दकुसुमैः कुमुदैरिव चाचितम् ।
काचे तु निष्प्रभेन्द्वर्कप्रदीपाद्यैरिवाचितम् ॥
सिताभा च सा दृष्टिः स्याल्लिङ्गनाशे तु लक्ष्यते ।
मूर्त कफो दृष्टिगतः स्निग्धो दर्शननाशनः ॥
बिन्दुर्जलस्येव चलः पद्मिनीपुटसंस्थित ।
उष्ण संकोचमायाति छायायां परिसर्पति ॥
शंखकुन्देन्दुकुमुदस्फटिकोपमशुक्लिमा ।

(अ. हृ. उ. १२ अ.)

4. रक्तज तिमिर

रक्तेन तिमिरं रक्तं तमोभुतं च पश्यति ॥
काचेन रक्ता कृष्णा वा दृष्टिस्तादृक् च पश्यति ।

लिङ्गनाशोपि तादृक् दृङ् निष्प्रभा हतदर्शना॥

(अ. हृ. उ. १२ अ.)

5. सान्निपातिक तिमिर

सन्निपातेन चित्राणि विप्लुतानि च पश्यति॥
बहुधा वा द्विधा वापि सर्वाण्येव समन्ततः॥
हीनाधिकाङ्गान्यथवा ज्योतींष्यपि च पश्यति॥

(सु. उ. 7/23,24 अ.)

संसर्गज व त्रिदोषज लिङ्गनाश

संसर्गसन्निपातेषु विद्यत् संकीर्णलक्षणान्।
तिमिरादीनकास्माच्च तैः स्याद् व्यक्ताकुलेक्षणः॥
तिमिरे, शेषयोर्दृष्टौ चित्रो रागः प्रजायते॥

(अ. हृ. उ. १२ अ.)

तिमिरं काचतां याति काचोप्यान्ध्यमुपेक्षया।
नेत्ररोगेष्वतो घोरं तिमिरं साधयेद् ध्रुवम्॥

(अ. हृ. उ. १३ अ.)

6. परिम्लायि रोग

पित्तं कुयात् परिम्लायि मूर्च्छितं रक्ततेजसा।
पीता दिशस्तथोद्यन्तमादित्यमिव पश्यति॥
विकीर्यमाणान् खद्योतै र्वृक्षांस्तेजोभिरेव च॥

(सु. उ. 7/25)

रक्तजं मण्डलं दृष्टौ स्थूलकाचानलप्रभम्।
परिम्लायिनि रोगे स्यान्म्लाथ्यानीलं च मण्डलम्॥
दोषक्षयात् कदाचित् स्यात् स्वयं तत्र च दर्शनम्॥

(सु. उ. 7/26,27 अ.)

रागोरुणो मारुतजः प्रदिष्टः पित्तात् परिम्लाथ्यथवापि नीलः॥
कफात् सितः शोणितजस्तु रक्तः समस्तदोषोथ विचित्ररूपः॥

(सु. उ. 7/28)

अरुणं मण्डलं वाताच्चंचलं परुषं तथा॥
पित्तान् मण्डलमानीलं कांस्याभं पीतमेव वा॥

श्लेष्मणा वहलं स्निग्धं शङ्खकुन्देन्दुपाण्डुरम्॥
चलत्पद्मपलाशस्थः शुक्लो बिन्दुरिवाम्भसः॥
संकुचव्यातपेत्यर्थ छायायां विस्तृतो भवेत्॥
मृद्यमाने च नयने मण्डलं तद् विसर्पति॥
प्रवालपद्मपत्राभं मण्डलं शोणितात्मकम्॥
दृष्टिरागो भवेच्चित्रो लिङ्गनाशे त्रिदोषजे॥
यथास्वं दोषलिङ्गानि सर्वेष्येव भवन्ति हि॥

(सु. उ. 7/29 से 33)

7. पित्तविद्ग्धदृष्टि

पित्तेन दुष्टेन गतेन दृष्टि पीता भवेद् यस्य नरस्य दृष्टिः॥
पीतानि रूपाणि च मन्यते यः स मानवः पित्तविदग्ध दृष्टिः।
प्राप्ते तृतीयं पटलं तु दोषे दिवा न पश्येन्निशि वीक्षते च॥
(रात्रौ स शीतानुगृहीतदृष्टिः पित्ताल्पभावादपि तानि पश्येत्॥)

(सु. उ. 7/35,36)

8. श्लेष्मविदग्धदृष्टि

तथा नरः श्लेष्मविदग्धदृष्टिस्तान्येव शुक्लानि हि मन्यते तु॥
त्रिषु स्थितः पटलेषु दोषो नक्तान्ध्यमापादयति प्रसह्य॥
दिवा स सूर्यानुगृहीतचक्षुरीक्षेत रूपाणि कफाल्पभावात्॥

(सु. उ. 7/37,38)

उष्णविदग्धदृष्टि

उष्णतप्तस्य सहसा शीतवारिनिमज्जनात्॥
त्रिदोषरक्तसंपृक्ते यात्यूष्मोर्ध्वं ततोक्षिणि।
दाहोषे मलिनं शुक्लमहन्याविलदर्शनम्॥
रात्रावान्ध्यं च जायेत विदग्धोष्णेन सा स्मृता॥

(अ. हृ. १२ अ.)

9. धूमदर्शी

शोकज्वरायासशिरोभितापैरभ्याहता यस्य नरस्य दृष्टिः॥
स धूमकान् पश्यति सर्वभावांस्तं धूमदर्शीति वदन्ति रोगम्

(सु. उ. 7/39)

10. ह्रस्वजाड्य

स ह्रस्वजड्यो दिवसेषु कृच्छ्राद्ध्रस्वानि रूपाणि च येन पश्येत्॥

(सु. उ. 7/40 अ.)

यो बासरे पश्यति कष्टतोथ रूपं महाच्चापि निरीक्षतेल्पम्॥
रात्रौ पुनर्यः प्रकृतानि पश्येत् स ह्रस्वजाड्यो मुनिभिः प्रदिष्टः।

योग रत्नाकर

दृष्टिमध्यस्थिते दोषे महद्ध्रस्वं ना पश्यति।
रात्री पित्ताल्पभावाच्च तानि रूपाणि पश्यति॥

11. नकुलान्ध्य

विद्योतते येन नरस्य दृष्टिर्दोषाभिपन्ना नकुलस्य यद्वत्॥
चित्राणि रूपाणि दिवा स पश्येत् स वै विकारो नकुलान्ध्यसंज्ञः॥

(सु. उ. 7/40)

द्योतते तकुलम्येव यस्य दृङ् निचिता मलैः॥
नकुलान्धः स तत्राह्नि चित्रं पश्यति नो निशि।

(अ. ह. उ. १२ अ.)

दोषान्ध

अर्केस्तमस्तकन्यस्तगभस्तौ स्तम्भमागताः॥
स्थगयन्ति भृशं दोषा दोषान्धः स गदोपरः।
दिवाकरकरस्पृष्टा भ्रष्टा दृष्टिपथान्मलाः॥
विलीनलीना यच्छन्ति व्यक्तमत्राह्नि दर्शनम्॥

(अ. ह. उ. १२ अ.)

12. गम्भीरिका

दृष्टिर्विरूपा श्वसनोपसृष्टा संकुच्यतेऽभ्यन्तरतश्च याति॥
रुजावगाढ़ा च तमक्षिरोगं गम्भीरिकेति प्रवदन्ति तज्ज्ञाः॥

(सु. उ. 7/41)

आगान्तुक लिंगनाश

बाह्यौ पुनर्द्वाविह सम्प्रदिष्टौ निमित्ततश्चाप्यनि मित्तत्तश्च॥
निमित्ततस्तत्र शिरोभितापाज्ज्ञेयस्त्वभिष्यन्दनिदर्शनैश्च॥

(सु. उ. 7/42)

अनिमित्त लिंगनाश

सुरर्षिगन्धर्वमहोरगाणां सन्दर्शनेनापि च भास्वराणाम्॥
हन्येत दृष्टिर्मनुजस्य यस्य स लिङ्गनाशस्त्वनिमित्तसंज्ञः॥
तत्राक्षि विस्पष्टमिवाभाति वैदूर्यवर्णा विमला च दृष्टिः॥

(सु. उ. 7/43,44)

अभिघातहता दृष्टिः

विदीर्यते सीदति हीयते वा नृणामभीघातहता तु दृष्टिः॥

(सु. उ. 7 अ.)

अम्लविदग्धदृष्टि

भुशमम्लाशनाद् दोषः सास्रैर्वा दृष्टिराचिता॥
सक्लेदकण्डुकलुषा विदग्धाम्लेन सा स्मृता॥

(अ. ह. १२ अ.)

धूमर

शोकज्वराशिरोरोगसतप्तस्यानिलादयः।
धूमाविलां धूमदृशं कुर्युः स धूमरः॥

(अ. ह.उ. १२ अ.)

औपसर्गिक लिङ्गनाश

सहसैवाल्पसत्वस्य पश्यतो रूपमद्भुतम्॥
भास्वरं भास्करादि वा वाताद्या नयनाश्रिताः॥
कुर्वन्ति तेजः संशोष्य दृष्टि मुषितदर्शनाम्॥
वैदूर्यवर्णा स्तिमितां प्रकृतिस्थामिवाव्यथाम्।
औपसर्गिक इत्येष लिङ्गनाशः

(अ. ह. उ. १२ अ.)

वाग्भट का मत से दृष्टिरोग

विना कफाल्लिङ्गनाशान् गम्भीरां ह्रस्वजामपि।
षट् काचा नकुलान्धश्च याप्याः, शेषांस्तु साधयेत्॥
द्वादशेति गदा दृष्टौ निर्दिष्टाः सप्तविंशतिः॥

(अ. ह. १२ अ.)

DISEASES OF DRUSTI MANDAL

1) Diseases of Drusti mandal are 12 according to sushrutha
II) " 27 according to vagbhata
I) Sushruta's classification of " Drustimandal diseases ".
12 Diseases , they are as follows

Note:- 1) Vataj linganash (Timira - kacha - Lingaanash are the progressive stages of the disease)
2) Pittaja Linganash "
3) Kaphaja Linganash "
4) Raktaj Linganash "
5) Sannipathaja Linganash "
6) Parimlayi
7) Pitta vidagdha drusti 8) Kapha vidagdha drusti 9) Dhooma darshi
10) Hraswa jadya 11)Nakulandya 12) Gambheerika

II) Vagbhata's Classification of Drustimandal diseases
27 Diseases , they are as follows

He counted Timira Kacha Linganasha as separate diseases, so

1 to 6 - 6 types of Timira
7 to 12 6 types of Kacha
13 to 18 6 types of Linganash

19) Pitta vidagdha drusti 20) Amla vidagdha drusti
21) Ushna Vidagdha drusti 22) Doshandha or Nakthandhya
23) Dhooma darshi 24) Hraswajadya
25) Nakulandya 26) Gambheerika
27) Aupa sargika Linganash.

Sadya - Asadyatha
I) According to Sushrutha - A) Sadya (curative diseases)
6 types of Timira, Kaphaj Linganash (shastra sadya), Dhooma darshi, pitta vidagdha drusti and kapha vidagdha drusti are **Sadya**

B) Yapyam :- 6 types of Kacha:- **c) Asadya** (incurable), 5 types of Linganash (6 types - Kaphaj Linganash), Gambheerica, Hraswajadya and Nakulandya.

II) According to Vagbhata:
A) Sadya (Curable diseases) 12 they are:- 6 types of Timira, Kaphaj Linganash, pitta vidagdha drusti, ushna vidagdha drusti, Naktandya
B) Yapya - 7 diseases :- 6 types of kacha and Nakulandya
c) Asadya 8 diseases:- 5 types of linganash, Gambheerica Hrawajadya, Aupasargic Linganash.

* TIMIRA, KACHA, LINGANASH *

Timira Kacha and Linganash are the progressive stages of a disease, occur by the vitiation of Netra patalas and explained as a terrific disease that obstructs the vision

Timira = Partial obstruction of the vision

Kacha = Pigmentation of the drusti in which Vision moderately obstructed

Linganash = Vision completely obstructed

Timira - occurs by the vitiation of I, II, III, patalas (sushrutha), I, II patala (Vagbhata)

Kacha - occurs By the vitiation of III patala in which drusti is pigmented (Vagbhata).

If drusti is pigmented in III patala it is called kacha if not Timira (Sushrutha)

Linganash - By the vitiation of IV patala Drusti is completely obstructed and called Linganash (sushrutha - Vagbhata)

Timiraakhyah Timira Sangya

" Raga praapthasya cha Timirasya Kacha ithi sangya

Runaddhi sarvatho drusti Linganasha Ucchyathe."

Symptoms of Timira Based on Patalas
(By Vagbhata)

1) I Patala	1) Avyakta rupa darshan (indistinct vision) But some times get normal vision without obvious cause
2) II Patala	1) Non existing things are visualised 2) Nearer objects are seen with difficult 3) Smaller objects of distance are not seen 4) Distant objects are seen as nearer 5) Near objects are seen as distant
Timira	**Site of the dosha in drusti If the lesion are** - **Symptoms Objects oppear** a) Circularly Present - Circular b) in middle of drusti Diplopia (Double vision) c) in many places Polyopia (Multi vision) d) In the interior of drusti - Big objects seen as small and small objects are seen big e) at Lower part of drusti - Nearer objects are not seen. f) The upper part of dusti - Distant objects are not seen. g) Sides of drusti - on the same side objects are not seen
3) III patala (Kacha)	When doshas reach this patala it is termed as kacha 1) patient have upper vision but not lower vision 2) Objects are visualised as covered by cloth 3) Gradually pigmentation agravates and vision reduces.
4) IV patala (Linganasha)	1) Dusti completly obstructed but can identify only the bright light .

Note :-

In the lesions of the diseases of Drusti mandal

If treatment is not given intime, the doshas spread from Ist patala to 4th patala and cause total blindness

Ist patala symptoms can be corelated to refractive errors, immature cataract

2nd patala symptoms - Can be corelated to immature cataract, vitreous opacities, Aqueous precipitants (Blood - pus, Foreign bodies) Refractive errors etc.

3rd patala symptoms can be corelated to Lental opacities and Retinal abnormalities

4th Patala symptoms can be coreleted to mature cataract.

Symptoms of Timira based on patalas
(By sushrutha)

S.No.	Patala Sankhya	Symptoms
1)	I Patala (KalaKaasti Aashritam)	1) Avyakta rupa darshan (Indistinct vision) but some time get normal vision without obvious cause
2	II Patal (Medo aashritam)	1) Dusti Vibhrama (Improper vision) a) Midya padartha darshan (Nonexisting things are visualised) ex flies, mosquitoes hair cobweb, rings, flags, rays, stars, rain, Darkness etc seen in their absence. b) Indriartha vibhrama (Existing things are improperly Visualised) **ex** Distant objects are seen as nearer. Near objects are seen as distant and cannot able to recognise the hole of a needle
3)	III patal (mamsa aashritam) (Timira) (kacha)	1) Patient have upper vision (urdwa drusti) but not the lower vision (Na adho drusti) 2) Bigger objects are visualised as covered by cloth 3)ear Nose eye etc Indrias are visualised in opposite. 4) If doshic vitiation is severe, the drusti is pigmented and called Kacha 5) According to the Site of the dosha, symptoms are explained, those are as follows.

Dosha Sthanam (Site of the dosham)		Symptoms
If the lesion is at		
a) Upper part of drusti	=	Distant objects are not seen
b) Lower Part of Drusti	=	Nearer objects are not seen
Sides of drusti	=	on the same side objects are not seen
d) on four sides	=	objects are seen as mixed
e) middle of Dusti	=	Diplopia (Double vision)
f) in two places of Drusti	=	Triplopia (Triple vision)
g) in many places of drusti	=	Polyopia (Multivision)

4) IV Patala:- Drusti completely obstructed but can identify the
(Linganash):- bright light (Perception and projection of light)
Tejo jala
Aashritam

Symptoms of Timira Kacha Linganash Based on doshas

By Sushrutha

Vitiated Dosha	Timira	Kacha	Linganasha
1) Vataj	objects appear as moving dirty, irregular and in Red colour (Aruna Varna)	Drusti appears in Aruna (red) or Shyava aruna (Blackish Red)	Drusti appears in Aruna varna (Red colour) rough and Floating
2) Pittaja	Objects appear as khadyotha (sparkling creature), Aditya (sun) Vidyut latha (sparks) and in blue, black or in yellow colour	Drusti apears in blue or yellow or dirty colour	Drusti apeears in blue, whitish yellow (Kasmsyabham)
3) Kaphaj	Objects appear as oily, whitish, Like floating in the water, smaller objects appear as stout, rigid and moveing clouds also seen in its absence	Drusti appears in white colour	Drusti appears oily stout and whitish like shankha chandra etc, it appears as a water drop on lotus petal, get constricted in bright light dilated in shade and spreads by pressure.
4) Raktaj	objects appear in Red colour, dark (tamas), somky (dhoomavath) (Haritha, syava peetha and in Krishna varna)	Drusti appears in red colour	Drusti appears in Red colour like lotus and Pravala.
5) Sanni pathaj	Objects appear in multi or mixed colours (chitra varna), wide spreaded, Diplopia, polypia mixedvision improper vision (Non existing things are visualised and existing things are improperly visualised.	Drusti appears in many colours (Chitra varna)	Drusti appears in many colours colour (Chitra varm)
6) Parimlay	All the sides appear in yellow colour like risingsun, the trees appear as covered by bright things and sparkling small creatures (khadyotha)	Drusti appers in in peetha Neelam (Bluish yellow)	Drusti appears in peetha neela (Bluish yellow)

Symptoms of Timira Kacha Linganasha based on Doshas

(By Vagbhata)

1) Vataj The objects appear as moving, dirty, irregular and in red colour, Non existing things are visualised and some times objects appear normal. If treatment is not given in this stage (Timira) it turns in to **Aruna Kacha** in which the drusti appears in red colour, non exist ing things are visualised, and existing things are improp erly visualised, one thing appears as many, straight things appear as curved, regular as irregular and vice versa. If the disease agravates it turns into **Linganash** in which drusti appears in dirty red colour and cannot able to see the objects

2) Pittaja In Timira the objects appear in Blue colour, as bright as vidruth, Khadyotha and shikhi pincha, if treatment is not given it turns into **Neela Kacha** in which the drusti appears blue and can visualise only the bright things like sun moon light rays etc. If treatment is not given it turns into **pittaja Linganash** in which drusti appears oily bright less, bluish and constricted (Hraswa drusti) and the objects are seen smaller

3) Kaphaj In Timira objects appear oily, in white colour, like shanka chandra etc. in Kacha Drusti appears white and objects are seen as dim or dark and in **Linganasha** drusti appears white as shankha and chandra drusti becomes hard, get constricted in brightness and dilated in the shade, fluctuant like a water drop on the petal of lotus flower and the vision is completely obliterated.

12 Gambheerika (Phthisis bulbi - Endophthalmitis) It is vataja Asadya vyadhi in which drusti mandal is vitiated and causes shrinkage of the eye ball with irregular size and shape. It associates with severe pain.

DOSHANDHA OR NAKTHANDHYA
(By Vagbhata)

The vitiated doshas cause the drusti inactive and covered at night so cannot visualise the things- But at day time doshas are activated or dissolved from drusti so only can visualise at day time (It is a type of Night blindness)

AUPASARGIKA LINGANASHA
(By Vagbhat)

The Vatadi doshas vitiate the drusti and causes painless blindness due to the eye exposing to bright things (Sun etc) or observing the wonders or super natural things etc. (Structural abnormality is not present but only functional derangement present)

Note :
Dhoomadarshi - Amla vidagdha drusti, ushna vidagdha drusti and pitta vidagdha drusti are having similar treatment procedures (Pittahara chikitsa)

1) Pitta dosha chikitsa
2) sheeta veerya applications and anjana
3) Virechana
4) Go shakruthrasa - Goksheera go ghritha (Pakwa ghritha) Anjana
5) Rasa kriyanjan prepared with Gyrica, Talisa patra
6) Ksheeri sarpi Nasyam - Tarpana Aashchyotan .
7) Nasya with medicated ghee prepared with meda Lodra guduchi manjista daruharidra yastimadu - Goghritha tila taila go ksheera etc.
8) Sira vyadana

BAHYA NETRA ROGA OR BAHYA LINGANASHA

2 diseases, they are

1) Sanimittaja Linganasha
2) Animittaja Linganasha - Asadyam (Incurable)

1) Sanimittaja Linganasha :-

The Aetiopathology for the disease can be explained, ex: Shirobhighata shiro abhitapa, poisonous touches to eyes etc. The signs Symptoms are exhibited like in abhishyanda (Structural abnormality causes loss of vision. But the causative factors are other than doshas).

2) Animittaja Linganasha :-

Aetiopathology of the disease is obscure, the blindness occurs without structural deformity (eye appears bright like vydoorya but visual perception is absent)
It occurs due to observing the super natural things, exposing to bright things, curse of the deva, gandarva, Rushi and maha sarpa etc.
Sanimittaja and Animittaja Linganash are Asadya

Abhighataja Linganash :-

Due to injuries if dursti is injured and destructed, is known as Abhighataj Linganasha

NAYANAABHIGHATHA (INJURIES OF EYE BALL)

Injuries to the eye ball may occur two types 1) Moortha (visible or direct injuries) 2) Amoortha (invisible or indirect injuries) .

The injuries to the eye ball occur due to following causes.
1) Penetrating injuries, contusion injuries, crushing injuries etc. 2) insect bite, 3) Sunstroke 4) Sun rays 5) Burns 6) Tikshna anjanas 7) effect of sun, moon, stars, grahas, super natural things etc. 8) Exposure to dust, smoke, foreign bodies chemicals, vapour Bright light and polluted water 9) Regular habit of tobacco alcohol 10) eye straining factors 11) Crying fear anxiety etc emotional factors 12) Langhana 13) Sleepless ness, night arousal day sleeping etc. 14) Ati sweda 15) Vascular and nervous dis orders etc.

Clinical features :-

1) Severe pain 2) Oedema 3) Hyperaemia 4) Congestion of vessels 5) Sub conjunctival haemorrhages 6) Photophobia 7) Lacrimation or exudation or Haemorrhage 8) head ache 9) Inflammation 10) Foreign body sensation 11) Reflex blepharo spasm 120 Dim vision or hazy vision or loss of vision occurs depending upon the seviority of the injury. 13) Distruction of eye ball 14) Sunken eye ball 15) proptosed eye ball

Sadya - Asadyaatwa:
If Ist patala only injured - Sukha sadya .
If 2nd patala also injured kasta sadya
If 3rd patala also injured Asadya and rejected for the treatment
Pishchita netra, shithila netra, Hata druk and anthahpravista netra- are **Yapyam**

4) Raktaj — In Timira objects appear in red **(Aruna Varna)** colour and dark (Andhaakara) in Kacha and Linganasha drusti appears Bright, less red, black and the vision is completely obliterated.

5) Samsargaj

6) Sannipataja — Mixed symptoms of the above are observed.

Note :

1) In Timira due to partial impairment of vision sushrutha or vagbhata given the desciption of the objects which are properly or improperly visualised.

2) In Kacha drusti mandal is mostly vitiated by vatadi doshas and attain the colour accordingly vision is mostly impaired so only sushrutha and vagbhata described the vision as dark or smoky and explained only the colour of the drusti mandal but not the description of the objects.

3) In Linganasha sushrutha and vagbhata described only the colour of drusti mandala according to the vitation of doshas and explained that vision is com pletely obstructed but can identify the brightness.

TREATMENT PRINCIPLE OF TIMIRA- KACHA - LINGNASH

A) Sadya vyadhies (Curable diseases) :-
6 types of Timira (Aushada sadya), Kaphaj Linganasha, (Shastra Sadya).

B) 6 types of Kacha are Yapya (Should be maintained)

C) 5 types of Linganash are Asadya (in curable)
(6 types - Kaphaj Linga nash)

Note :- Timira is complex disease, can be corelated to the syndrome of the diseases of refractive media .

The refractive errors, cataract, Opacities of vitreous aqueous and Retinal diseases, The Signs and symptoms are grouped under the description of Netra patalas (I to IV) and doshas.

THE COMMON TREATMENT PRINCIPLES OF TIMIRA

Pathya : - (Beneficial for the eye)

Triphala (Hareetaki vibheetaki Amalaki), Trikatu (pippali maricha - shunthi), Yasti madhu, Anjan (Rasanjan Sauveeranjan Etc.) Haridra, Daru haridra, shigru Shatavari, Ashwagandha, Bala, sariba, manjista, Nimba, Vidanga, Sumudrphene, Tankan Guduchi Bhumyamalaki Nirmaleephala (Kataka beeja) Karpoora, chandana Kasthuri Lavanga Pundareeka usheera musta Tulasi Padmaka Neelothphala Devadaru Nirgundi Rasna Goghritha Aja gritha goksheera Aja Ksheera Go mutra Ajamutra, saindhava lavan, sita, madhu, stanya, jaangala mamsa, multon of carnivorous birds (chala janthu, mamsa) Punarnava, Brungaraj, Kumari, Karanja, taila, Sarshapa taila, godhuma tail, swarna bhasma, Rajatha bhasma, Tamra bhasma, Nagabhasma, vanga bhasma, Loha bhasma, makshika bhasma, gyrika bhasma, kaseesa bhasma, Abraka bhasma, spatika bhasma, muktha bhasma, praval bhasma, Heeraka bhasma, shalidharya, shastika dhanya, kodrava, Godhuma yava, vana kulutha, mudga, kushmanda, patola, karkotaka, karavellaka, varthaka, Tarkari, kareera shighru, jeevanthi, Sunishannaka, Tanduleeyaka, vastuka, moolaka, Draksha, Dadima Aakashodaka, **Shodhan karmas** (Vaman virehan Nasya Vasti Raktha mokshan). **Local Treatments:-** (Seka Aashchyotan, Pindi Bidalaka Tarpan, putapaka, Anjan etc. Prasanna manas wearing chappals (pada pooja) and umbrella and shirovestana to save the uttamangam (Head).Shathavari Ksheera or payasa, Aamalaki Ksheera or Payasa, Triphala Ksheera or payasa, eating of yava odana (Food) shirasnana with cool water Reguler pratice of shiro Abhyanga and avoiding of excessive Katu Amla lavana Vidaha Kshara guru Abhishyandi food

Apathya (Not to do for health of eyes)

1) All the points those explained in Netra roga Nidana
2) Suppressing natural urges (vegavarodha)
3) Paada Peedan or Paada gharshan (giving pain to foot)
4) Shiro Abhyanga dwesha (Rejecting head massage)
5) Not wearing umbrella or shiro vestana
6) Observing the bright, dim, very distant, very nearer, smallest, biggest and moving objects
7) Using polluted outdated anjanas.

Treatment principles :-

1) Nasya, Lepa, pariseka, Tarpan, snehan, Sheeta upachar (Cool therapy), Vranaharaupachar (wound healing therapy), pittaja and Rakthaja Abhishyanda chikista etc should give - If the injury is within 7 days duration, If not vataja Abhishyanda chikitsa (Sneha - Sweda (Bhaspa sweda) Should give .

2) In sunken or antah Pravista netra eyes should be tried to push out by prana yama sneezing vomiting and restricting. deglutition etc. .

3) In Proptosed eye - Deep inspiration cool water shiro seka etc. should do

4) Sadya vrana chikitsa should do, if vision is not Disturbed.

5) Gritha for Tarpan, Nasya and for oral the Ghee is prepared with Aja Ghritha 1. Prasta, Aja Ksheera 1 Aadak, madhu 2 phala, Neelothphal 2 phala, jeevak 2 phala, Rushabhak 2 phala etc.

DRUSTIGATHA ROGA

12 diseases According to Sushrutha
1 to 6 Timira - Explained in table form

S.No.	Name modern name	Dosha prognosis	Clinical Features	Treatment principle
7.	Pitta Vidagdha drusti (Day blindness)	Pittaj Sadya	Drusti is vitiated and visualise the things in yellow colour, if pitta dosha enters 3rd patala causes day blindness.	Ashastra kruth
8.	Kapha Vidagdha drusti (Night blindness)	Kaphaj Sadya	Drusti is vitiated and visualise the things in white colour, if doshas enters into 3rd patala causes night blindness.	Ashastra kruth
9.	Dhooma Darshi (Smoky vision)	Pittaj Sadya	Drusti is vitiated due to head-ache, fever exertion etc and visualise the things as smoky	Pittaja Abhishanda chikitsa
10.	Hrawajadya (Retinitis - pigmentosa)	Pittaj Asadya	Drusti is vitiated and causes difficulty in vision at day time (bigger objects are seen smaller)	Asadya
11.	Nakulandya (A type of night blindness)	Tridoshaj Asadya	Drusti is vitiatied and shines like the drusti of mangoose, objects are seen in multi colours and can't see at Nights.	Asadya
12.	Gambheerika (Phthisis bubli endophthalmity)	Vataj Asadya	Drusti is vitiated and eye ball is shrinkan and become irregular with severe pain.	Asadya.

BAHYA NETRA ROGA.

1)	Sanimittaja Linganasha	Aetiopathology is obvious, Shirobhi tapa, shirobhi, ghatha inhalation of poisonous flowers strucutural abnormality causes lose of vision.	Asadya.
2)	Animittaj Linganasha	Aetiopathology is obscure blind ness occurs without structural deformity .	Asadya.

8) Chronic exposure to dust smoke heat and cold
9) Improper cleaning or washing of eyes and face.
10) Tobacco and alcohol habit
11) Not treating the chronic specific systemic infections in time.
12) Immediate opposite exposures like hot cold, bright -dim, distant vision - near vision, etc.
13) Krodha klesha shoka Bhaya Ativyayama eye strain shirobhighatha Tensions emotions anxiety etc Mano dosha
14) Resting the head upwards or down wards while sleeping.
15) Ati sweda
16) Not protecting the eye from foreignbodies (Labour working in stone crushing or cement or other chemical factories etc.)

1) Systemic Purification by virechan, Rakthamokshan etc shodan Karma
2) Local therap by Anjan Tarpan Nasya etc netra kriyakalpas.

1) a) Jeevanthyadi ghrita -oral administration :- Jeevanthi 100 phala, water 1 drone. decoction should prepare with 1/4 residue (Padaava sesha) then added I prastha ghee, 2 prasta cow milk, each 1 karsha of kalka dravyas like prapoundareeka ,kakoli ,pippali Lodra, saindhavalavana ,sadapa ,yastimadu, Draksha, sugar ,Devadaru ,Triphala etc ghee has to prepare according to ghrithapaka vidhi and orally given in Timira.

b) Jeevanthi decoction 1 Prastha
1 prasta cowmilk ,kalka dravyas each 1 Karsha - they are ksheer kakoli, jeevaka, sharkara, shatavari, meda, pundrahya, yastimadu ,neelothphala - Ghee has to prepare according to ghritha paka vidhi and given orally in Timira

2) Patoladya ghritha - Oral administration:- Patola, Nimba, katuki, Daruharidra ,usheera ,Triphala, vasa, Dhanvayasa ,Trayanthi ,parpataka - Each 1pala, Amalaki 1 prasta, water 1 drona, decoction should prepare and should reduce to 1/4 (Aadaka), Kalka drvyas are musta Kiratha tiktha yastimadhu, Kutaja, chandana, kuru veru (udeeccha) pippali - each 1/2 phala, 1prasta cow ghee- ghee prepared according to ghritha paka vidhi and should use in Timira nasa karna and charma rogas.

3) a) Triphala ghritha :- (Vagbhat) Triphala 8 phala, water 1 Aadaka decoction should reduce to 1/4,
cow milk is taken equal to decoction, triphala kalka 1Phala, ghee 1/2 prasta ghee shoould prepare according to ghritha paka vidhi - sugar or Honey added and given Orally in Timira.

b) Triphala kalka, Triphala kwatha, cowmilk, cow ghee (quantity and preparation according to gritha paka vidhi) it is used in Timira (Vagbhat)

c) Maha Triphala ghrita - (Vagbhat) Aja Ksheera 1Prastha, Triphala Kashaya 1 prastha, Vasa swarasa 1 prastha, go ghritha 1 prastha,
Kalka drugs each 1 phala they are yastimadu, kakoli, ksheerkakoli, vyaghree, pipali, guduchi, Neelothphala, sugar, draksha, ghee should prepare according to ghritha paka vidhi and is used orally in Timira.

d) Triphala ghritadi yoga in Timira (Vagbhat) Triphala ghritha, Triphala yastimadu and Honey, mixed well and kept for a month, later on daily at night it is used for vision improvement

e) Maha Triphaladya ghritha (Chakradatta) Triphala quatham 1prastha, vasa swarasa 1 prasta Aamalaki swarasa 1 prastha, Brungaraj swarasa 1 prastha Aja Ksheera 1 prastha amrutha swarasa 1 prastha, Kalka drugs are pippali sugar draksha Triphala Neelothphala yastimadu ksheerkakoli mudgaparni Nidagdhika (1/4th weight of ghee)
ghee should prepare acording to ghrithapaka vidhi and is given " Before middle and after meals" for vision improvement.

f) Anya Triphala ghritha (Chakradatta) or Triphala ghritha :-
Triphala, Trikatu, Draksha, yastimadhu, Katuki, prapoundareeka, sukshma, Ela vidanga, Naga kesar, Neelothphala, Sariba Bala chandana dwayam, Haridradwayam, each 1 karsha, ghee 1 Prastha, cow milk 1 prastha, Triphala quath 3 prastha. Ghee should prepare according to ghrithapaka vidhi and given in Timira.

g) Dwitheeya Triphala ghrita (Bhava mishra):- Hareetaki 100, vibheetaki 200. Aamalaki 400, 4 times water is added and 1/4th decoction should prepare,
Kalka drugs are yastimadu, sugar, draksha, nidigdhika, madhooka, kakoli, ksheerakakoli, Aamalaki, Haridra, vibheetaki, Nagkesar, pippali, chandana, methi, Uthphala, 1 tula vasa swarasa, 1 tula brungaraj swarasa, 1 Prastha Goghritha - Gritha has to prepare according to gritha paka vidhi and given orally for the improvement of vision.

h) Triphala choorna + ghee - in Timira

i) Triphala kashaya + ghee - in Timira

CATARACT

(Timira Kacha Linganasha)

Defination:- Opacification of (formation of opacities) lens or its capsule is known as cataract .

Description:- Lens is the Biconvex transparent structure placed behind the Iris by the support of zonule or suspensory Ligament , it converges the light rays to form Image on retina. It contains capsule, subcapsular epithelium cortex and nucleus. The fibres from foetal life are concentrically arranged in the lens like the scales of an onion. The most interior fibres are the oldest fibres (fibres of foetal life).So many factors cause the lental opacities (Denaturation of lens) and affect the vision, it is known as cataract.

Aetiology and pathology of cataract:

1. Lens is a Avascular structure so inflammatory changes cannot occur mostly Degenerative changes occur.

2. Lens fibres from foetal life are concentrically placed in the lens like the scales of an onion, so by age the central fibres of lens (Nucleus)are crushed and leads to Lental sclerosis (Degeniration) with increased refractive index of lens.So physiologically threre are chances for senile cataract.

3.Senile biochemical changes in Lens

a) Gradual increase of Lental degeneration.

b) Diminished Lens metabolism (Impaired auto oxidative system of Lens).

c) Decreased essential amino acids, Glutathione nucleotides, Ascorbic acid enzymes vitamines and minerals

d) Altered calcium and phosphates ratio in Lens and extra Lenticular fluids.

e) Altered Sodium and potassium ratio in Lens and extra lenticular fluids.

f) Increased osmotic pressure in Lens and decreased osmotic pressure in extra Lenticular fluids - So causes imbibition of fluids into Lens and causes opacification.

g) Increased cholesterol and disappearance of inter cellular fat membrane

h) Reduction of soluble proteins and aggravation of insoluble proteins .

i) Increased acidity and proteolysis causes digestion of soluble proteins (into white milky fluid) and coagulation of insolubleproteins in which the nucleas appears as floating.

1.

2.

1. Iris shadow in immature cataract

2. No Iris shadow in mature catarct



The structure of the lens in an adult of 40 years, as shown in the optical beam of the slit-lamp; 1, anterior capsule; 2, cortex; 3, adult nucleus; 4, infantile nucleus; 5, foetal nucleus; 6, embryonic nucleus

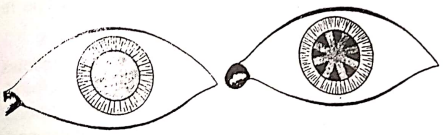

Lental sclerosis

Incipient cataract (Peripheral type)

Incipient cataract (Central type)

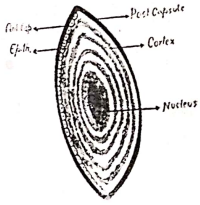

4) Congenital or developmental causes for cataract.
ex:- maternal malnutrition, infections, defficient oxygenation due to placental haemorrhage etc.

5)Traumatic causes for cataract
ex:- penetrating, injury, contusion Injury and radiational trauma etc.

6)Increased osmotic pressure in the Lens- causes cataract.

7) Systemic infections like diphtheria, small pox, malaria, typhoid etc causes cataract.

8) As a complication of peripheral inflammatory disorders like uveitis, keratitis
glaucoma etc causes cataract

9) Metabolic disorders
ex Diabetes - Hypo thyroidism etc causes cataract

10) Defficiency of Amino acids vitamines and minerals - causes cataract

11) Usage of toxic drugs
ex Naphthalene, Thalium, cobalt, selinium, steroids etc, causes catarct

12) Physical influences on capsule and sub capsular epithelium - causes cataract.

13 Cataract in association with multiple syndromes, skin lesions Bone lesions etc.

14) Ultimate state of the Lens depends upon the capsule, they are as follows

a) If Lens capsule is impermeable due to thickness - The digeste Lends fibres (Milky fluid) stagnated in the Lens with coagulated Lens proteins and with the floating nucleus (morgagnian cataract)

b) If Lens capsule is permeable lens matter diftused out - and lens become flat, shrinked with undigested lens fibres and nucleus (hyper mature cataract)

c) If the lens capsule get ruptured the toxins and Extra lenticular fluids enter the lens disintigrate it and produces severe complications like Glaucoma and endophthalmitis.

Classification of cataract :-

I) a) Congenital or developmental cataract b) Acquired cataract
II) A) Immature b) mature c) Hyper mature cataract
III) a) capsular cataract b) cortical cataract c) Nuclear cataract.
IV) Clinical types of cataract
1) Congenital or developmental cataract 2) Senile cataract
3) Metabolic cataract 4) Osmotic cataract
5) Cataract in Osseous diseases
6) Cataract in skin diseases (syndermatotic
7) Cataract with multiple syndromes
8) Traumatic cataract 9) Toxic cataract 10) Complicated cataract
11) Cataract due to systemic infections
12) Defficiency or malnutrition of cataract
13) Occupational cataract.

SENILE CATARACT

Senile cataract - generally starts after the age of 50 yrs. and occur equally in men and women. It is usually bilateral but starts in one eye then in the other

Clinical features:-

It can be divided into 2 large groups, they are.
1) 20 to 25 % - nuclear cataract
2) 75 to 80 % cortical cataract

1) Nuclear cataract or Hard cataract:- The nucleus of the lens becomes diffusely cloudy due to physiological Lental sclerosis, while the cortical fibres remain transparent. The nucleus may become brown red and even black.

Clinical features - 1) Visual disturbance (Progressive myopia due to increased refractive index of Lens.) 2) Obstruction of vision (Hypermature stage does not occur) 3) 0/E = with Ophthalmoscope by pupil dilatation, fundus appears little hazy and nucleus appears black against the red reflex.
4) If maturity (Sclerosis) reaches up to capsule, vision completely obstructed and ophthalmoscopy is not possible.

2) CORTICAL CATARACT

The clinical features can be explained in 4 stages
(cortical cataract means denaturation or opacification of cortex of Lens.

4) Maha Vasadi Quatham:-
Vasa, musta, nimbatwak, Patola patra, Kakuki, guduchi, Raktha chandan, Kutaja, Indrayava, Daruharidra, Chithramoola, shunthi, kiratatiktha, Triphala yava - 16 times water is added and reduced to half - This decoction is orally used in Netra rogas.

5) a) Triphala choora or Kashaya with Tailam is given in vataja Timira
b) Triphala choora or Kashaya with ghee is given in Pittaja Timira
c) Triphala choorna or Kashaya with madhu is given is kaphaja Timira

6) Makshika bhasma, Loha bhasma, swarna bhasma, Yastimadu, Sita, (Sugar) Purana ghritha, madhu and Triphala - orally administered in Timira
7) Makshika, Lohabhasma, swarna bhasma, yastimadu Sita, Purana Ghritha, (Sugar) Madhu and Triphala - Orally administered in Timira
8) Triphala can be used daily with food items (Sweets Tiffins) for improvement of vision.
9) Draksha or Triphala with sugar and Honey oral administration for the improvement of vision.
10) Daily face wash or eye wash with Triphala Kashaya controls the eye diseases.
11) Triphala churna yastimadu, lohabhasma + ghritha or Honey - oral administration.

ANJANAS

1) Timira roga hara Choornanjan :- Sauveeranjan (Srotonjan) 64 parts, tamra loha rajatha and swarna bhasma each 1 part, these bhasma are melted and dipped in th decoctions of madhuradi gana drugs separately for 7 times, added vydoorya bhasma, muktha bhasma and shankha bhasm - perfectly grinded and preserved for Anjana in timira.

2) Jata mamsi Trijathaka Loha bhasma Kumkuma Neelothphala Hareetaki tutha swetha Kaca shankha samudra phena maricha sauveer raanjan pippali yastimadhu - The medicines are equally taken perfectly grinded and should use as anjana when chandra enters into Ashwini Nakshatra - it is useful in Timira

3) Drusti prasadan Anjan :- Sauveeranjan is melted and dipped in the following liquids 7 times each Draksha swarasa Kamala mrunata swarasa Go ksheera, madhyam vasa swarasa varshodaka etc. The Anjana is powdered and preserved in shankha and is used for the clarity of vision

4) Bhaskara choorna :- Tuttham is heated with Badara sticks and dipped in Ajaksheera go ghritha and honey separtely each item. The purified tultam 2 phala makshika maricha srotonjana Katuki Tagora saindhavalavana lodra manah shila Hareetaki pippali Ela Sauveeranjan samudra phena each 1 karsha, Yastimadu ' phala, all the items are fried in a moosha and powdered, it is useful in Timira arma shukra.

5) Timirantakanjan :-
Naga bhasma 30 parts, ganda pashana 5 parts Tamra bhasma 2 parts, Talaka 2 parts, vanga bhasma 1 part, sauveeranjan 3 parts all the drugs are melted powdered and used as anjana in Timira

6) Tuttanjan :-
Tuttham is heated and dipped in gomutra gomaya rasa Kanji stanya Ghritha madhu and Vatsanabhi 7 times in each item after wards tuttham is powdered and used for anjana in Timira.

7) Lead is melted and dipped in triphala Kashaya Brangaraj swarasa Vatsanabhi, Kashaya, Ghritha, Aja Ksheera, Yastimadu Kashaya 7 times in each liquid, then it moulded as anjana shalaka and is used with or without anjana

8) Drusti shakthikara anjan
Parad naga each 1 part, sauveeranjan 2 parts, 1/16 Karpoora - Grinded and used as anjana in Timira.

9) Drusti Shakthikara anjan
Ghridra mukha bhasma + ghritha + Sauveeranjan used as anjana

10) Sauveeranjan and ghritha, kept in the mouth of Krishna sarpa later drug is collected bhasma is prepared and added Jatamamsi Choorna, given as anjana in corneal tear.

11) Kukkuta vistanjan:-
Cow milk is taken in a pot, dead Krishna sarpa and scorpions are added and kept for 21 days, Later on the milk is chilled and cheese removed,that is given to the hen and after wards the Hen faecal material is collected for giving anjana

12) Drusti shakthikara rasakriya:
Krishna sarpa, vasa, shankha, Kataka Sauveeranjan - Rasakriyanjan

13 Aprathisaranjan :-
Maricha 10, Makshika 1/2 Karsha, Tuttha 1 phala, yastimadu 1 Karsha, mix with cow milk - make it bhasma and use as anjan in Timira

14) Aksha beejadi gutica
Tala beeja (Aksha beeja) maricha Amalaki tuttha Yastimadu - should grind with water and used as varthi anjan in Timira

15) Shanmakshik yoga anjan in timira :
Maricha 1 part, Aamalki 2 parts, swetha kamal 3 parts, tuttha 4 parts sauveeranjan 5 parts, makshika 6 parts - Grinded and given Anjana in Timira.

1) Incipient stage 2) Intumescent stage
3) mature stage 4) Hyper mature stage

1) Incipient stage :-
Few opacities develop either in the periphery or at the centre and are arranged like the spokes of a wheel. The subjective symptoms are polyopia rainbow halloes, and impairment of vision. If the opacity is in the centre part of Lens the patient complains of defective vision more in day time and if the opacity is in the peripheral part of Lens, defective vision is more at night.

Signs :- 1) On ophthalmoscopic examination the opacities appear as black spots against red reflex of funds 2) In oblique illumination the pupils appear greyish (lental sclerosis also) the pupil appears greyish But confirmation only by above ophthalmoscopic examination in which black opacities are not seen against red reflex in Lental sclerosis.

2) Intumescent stage :- Symptoms are same as above but in addition myopia develops due to alteration in Lental Curvature.

Signs :- opacities become more diffuse and irregular, Lens is swollen, pushes the iris forwards, Anterior chamber become shallow and leads to secondary glaucoma (Iris shadow present)

3) Mature stage :- whole Lens become opaque, its Anterior surface shows mother of pearl appearance, vision mostly reduced, can recognise only hand movements no fundal glow at pupillary area, Loss of 3rd purkinje's image and Iris shoadow is absent.

4) Hyper mature stage :- Mature cataract if delayed without proper treatment leads to hypermature catarct .
1) Soluble Lens proteins digested and become milky fluid insoluble proteins coagulates, due to the permeability of Lens capsule the fluid of Lens get lost, Lens become flat and shrunken, Iris become tremulous, Anterior chamber become deep, degeneration of suspensary ligament, sub luxation of Lens and secondary glaucoma follows.
2) Lens fibres of cortex digested and become milky, nucleus sinks to the bottom of thickend capsule, such cataract is known as morgagnian cataract.

Dangers of hyper maturity :-
1) Sub luxation of Lens 2) Secondary glaucoma
3) irido cyclitis 4) endophthalmitis

Treatment :-
1) No drug has significant effect in causing disappearance of opacities
2) Surgical interference in mature stage is un avoidable.



Schematic representation of the clinical types of Cataract
a. Spindle; b. Lamellar; c. Nuclear; d. cortical e. complete

Coronary Cataract

Punctate Cataract

Coralli form cataract

Morgagnian cataract showing the lenticular nucleus

A B C

ANTERIOR POLAR CATARACT

A, seen with oblique illumination; B, section of lens; C, seen with ophthalmoscope.

16 Ratnadi Choornajan -

Ratna, rajatha, spatica, swarna, sauveeranjan, Tamara, Loha, shankha, chandana, kumkuma, Gyrica, choornanjan is given in Timira

17) Vyaghra vasyanjan

Vyaghra vasa or varaha vasa or Grudhra vasa or kukkata vasa or sarpa vasa + Yastimadu choorna given as anjan in Timira.

18) Sauveeranjan is heated and dipped in mamsa rasa ksheera ghritha separately and choornanjan is given in Timira

19) Vimala varthi anjan

Shankha priyang manahshila, Trikatu triphala grinded and varthi anjan is given

20) Kokila varthi - Loha raja, trikatu, Saindhava lavan Triphala sauveeranjan - grinded and varthi anjan given .

21) Sukhavathi varthi :- kataka, shankha, bhasma, trikatu, saindhavalavan, sugar, samudra phen, rasanjan, vidang, manahshila, kukkutanda twak,- grind with water and varthi anjan is given with madhu

22) Chandrodaya varthi - Hareetaki, Vibheetaki, pippali, maricha, Vacha, Kusta, shankhanabhi, manahshila, the powder is grinded with Ajaksheera for varthi anjan.

23) Hareetakyadi anjan -

Hareetaki 1 part, haridra 1 part, pippali 1part, saindhava lavan 1/4 part grinded and varthi anjan prepared.

Usheera kashaya + pippali saindhava lavana goghritha madhu as anjan.

24) Muktaadi Mahanjan -

Mukttha, karpoora, kachalavana, agaru, maricha, pippali, lavana, sailavala, shunthi, Kankola, kamsya, Haridra,Trapu, manahshila, shankhanabhi, Abhraka, Tuttha, kukkatandatwak, Hareetaki, vibheetaki, Kumkuma, yastimadu, Rajavartha, Tulasi, navapushpa, karanja, Nimbatwak, Arjuna, musta, Tamra, aswagandha, methi - each 1 masha, the fine powder with madhu is given as anjan in Netra rogas.

NASYA YOGAS

1) Jeevanthi Tailam

jeevanthi 100 phala - water 1droni decoction should reduce to 1/8 - Tila taila, and go ksheera 1 prasta each one pala Balatraya shathavari and jeevanth, Yastimadu 4 phala - Tailam is prepared and preserved in Iron vessel Later on used as Nasya in most of shalakya diseases.

2) Erendadi Tailam

Erenda, simheephala, Devadaru, vacha, Tagara, ghoshaya Bilvamoola, tila Tailam - cow milk (equallly) Oil is prepared according to taila paka vidhi for nasya

3) Tila tailam Aksha tailam

Brungaraj swarasa Asana kashaya equally taken and oil prepared in an iron vessel for nasya

4) Brungarajadya taila
5) Nrupavallabha taila For nasya
6) Abhijith taila

Tarpan yogas :-

1) with ksheeri sarpi (Ghee prepared from milk
2) Cowmilk + kukkuta or varaaha or mayura or Tittiri etc birds vasa perfectly heated together and ghee is extracted, the ghee +Yastimadu usheera chandana and heated according to ghritha paka vidhis. This medicated ghee is used for Tarpana in Timira.
3) Medicated ghee prepared according to the vitiation of doshes is used for Tarpanam.

Vasti or Rakthamokshana also advised according to the condition of the patient.

VATAJA TIMIRA CHIKITSA

1) **Rakta mokshana** (Contra indicated in kacha)
2) **Virechan** :- by the oral administration of
a) Medicated ghee prepared from Dasha moola kashaya cow ghee cow milk and Triphala kalka.
b) Triphala Kashaya or pancha moola kashaya or Dasha moola kasha + cowmilk + erenda tail. etc.
c) Dashamoola ghritha + Trivruth churna etc.
3) **Shaman** Chikitsa by the oral administration of
a) mesha shrungi ghritha b) Triphala ghritha
c) Patolodya ghritha d) purana ghritha
e) Ksheerisarpi f) Kakolyadi or vidarigandadi ghrita

II) Congenital or developmental cataract:-

The child is born with Lental opacities or it develops soon after birth. The exact cause is not known and the opacities are mostly stationary in nature. The following are some of the causes

1) Hereditory tendency. 2) maternal malnutrition 3) maternal infection by German measles etc. 4) defficient oxygenation due to placental haemorrhage etc.

Types :-

1) Punctate cataract or blue dot cataract :- Small multiple opqaue dots are scattered all over the Lens, they appear as tiny blue dots on oblique illumination with slit lamp (These cannot obstruct the vision)

2) Fusiform or spindle shaped or coralli form or disciod Cataract

Spindle shaped or coral shaped small opacities develops in Lens, those does not cause visual obstruction.

3) Embryonal nuclear cataract :- Some of the the central nuclear fibres remains opaque due to early developmental anomaly, other fibres are normal (Rubella infection in first trimester of pregnancy causes nuclear cataract which is progressive in nature) in general it does'nt cause visual obstruction

4) Coronary cataract :- Non progressive club shaped opacities develop in deeper cortex and peripheral nucleus (peripheral cortex and depper nucleus is normal) vision cannot obstructs.

5) Lamellar or zonular cataract :-

Grey disc shaped opacities (Spokes of a wheel) develops in some layers due to nutritional defficiency, the other layers are normal, it is a bilateral heriditory tendency.

6) Anterior capsular cataract :- it is congenital due to delayed formation of anterior chamber, Acquired due to contact of ulcerated cornea to the anterior Lens capsule. Anterior Lens capsule and some times subcapsular cortical fibres also involves.

7) Posterior capsular cataract ;- It is due to persistance of posterior part of vascular sheath of Lens, incase of persistent hyaloid artery.

III) Traumatic Cataract :-

It is due to injury to Lens or its capsule

1) Penetrating injury such as needle or a thorn causes cloudiness or opacity at the site of injury with in few hours due to entry of aqueous humour and toxins, within few days the entire Lens may become opaque with complications like glaucoma, endophthalmitis, etc.

2) Contusion injury causes rupture of Lens and causes complete cataract.

3) Radiational trauma due to exposure of
   a) Infra red rays, ex - glass workers, furnace workers
   b) Ultra voilet rays, Prolonged exposure to sunlight
   c) irradiation - exposure to x rays frequently.
   d) Due to electric, shock etc, causes cataract formation.

IV Osmotic cataract :-

Changes in the Osmotic pressures in Aqueos (Body fluids) and Lens causes cataract formation.

a) precipitation of sodium calcium etc in Lens than aqueous b) reduction of phosphates potassium etc in Lens than aqueous, cause increased osmotic pressure in lens that aggrevates the imbibition of water, aqueous, extra lenticular fluids and toxins in to the Lens, causes proteolysis and cataract formation.

V) Cataract due to systemic disorders :-

1) Infective Fevers like diphtheria malaria, typhoid, typhus, cholera, small pox, scarlotine fever, etc may cause cataract.
2 Severe toxic states Extreme cachexia, nephritis, pernicious anaemia etc.
3) Massive blood loss
4) Less authentic types Tuberculosis, ornithosis, cooley's anaemia, profound anaemia, ankylostomiasis etc.

VI) Complicated Cataract :-

It is due to complications of peripheral Lesions like

Ulcerative keratitis, irido cyclitis, choroiditis, syphilis, Rubella, Toxo plasmosis, High myopia, Glaucoma, intra ocular neoplasm, vitreo-retinal dystrophies, Retinal detachment etc. causs cataract as a complication.

VII) Toxic cataract :-

It is due to usage and exposure of toxic drugs like

1) Hydro carbons ex naphthalene
   Dinitro phenol
2) Salts - Thalium cobalt selinium, etc,
3) Anti mitotic agents (1-4, Dimethane sulfanoxy butane)
4) Enzyme inhibitors (Iodo acetic acid)
5) Prolonged administration of miotics
6) Prolonged usage of cortico sterioids
7) Prolonged usage of synthetic antihistamines
8) Prolonged usage of concentrated sulfanamides
9) Prolonged usage of morphine group drugs.

All these drugs produce Lenticular opacities very quickly with other systemic lesions, like increased or altered metabolism, spleenic hepatic lesions, degenerative changes (Local -systemic), neurological lesions and vascular lesions etc.

4) **Nasya :-**

a) Jeevantyadi taila b) Gomaya tailam

c) Anu tailam d) Kakolyadi or vidari gandhadi taila or ghritha

e) sahadi taila or ghritha

(Taila or ghritha, saha (mudga parni), Ashwa gandha, Ati bala and shatavari)

f) Jalodbhavadi ghritha (matsya, Kacchapa mamsa, milk - ghee should prepare according to ghritha paka vidhi .

g) Erenda mooladi ghritha or taila h) Trivrutadi tail nasya

i) Ksheera sarpi (ghee prepared from milk)

5) **Vasti** with vatara taila or ghritha

6) a) **Tarpan** and snehan putapaka, with medicated ghee prepared from shatahwa kusta jatamamsi, Kakoli, Ksheer kakoli, Yastimadu, sarala, kusta, Devadaru, ghee and milk.

b) Tarpan With ghritha manda or Ksheeri sarpi .

c) Tarpan with the medicated ghee prepared form- cow milk and vasa of animals, ghee should preopared and yasti madu usheera, chandan are added, pakwa ghritha, is used for tarpan.

7) Puta Paka & Anjan

with Ghridra, Harina mamsa, Saindhava, Lavang, ghee and Honey .

8) Anjan :

a) Ghridra Krishna sarpa, Kukkuta vasa + Yastimadhu churna

b)Srotonjan or sauveranjan should in heat and dip in Triphala kashya, in mamsa rasa, ghritha and ksheera - after that the anjan head and dip should be powdered and preserved for usage

c) Anjan with vyaghra varaha vas.

9) a) Triphala churna with taila or ghee should take orally, daily for improvement of vision

b) Triphala Kashaya with Taila or ghee should take orally, daily for the improvement of vision

c) Triphala ghritha + Lukewarm milk

d) Aamalaki phala Kashaya

e) Triphala ghritha + yastimadu churna + Honey

f) Triphala churna + Yastimadu + Loha bhasma + Ghritha + Madhu

g) Regular oral usage of go ghritha after meals.

h) Oral usage of madicated ghee prepared from Rasna, Triphala quath Dasha moola quath, Jeevaneeya Kalka ghritha.

I) The medicated ghee prepared with Dashamoola quath + Triphal Kalka + milk + Ghee

J)Oral administration of Triphala makshika loha bhasma swarna bhasma Yastimadu sugar and Ghee,

Vataj Kacha Chikistsa

1) Raktha mokshan is contra indicated

2) Srotonjan should kept in the mouth of krishna sarpa for amonth then it is collected and add saindhava lavan and Jathi pushpa swarasa for the usage.

3) Above srotonjan should do bhavan in milk for 3 days then if can be used for anjana

PITTAJA TIMIRA CHIKITSA

1) **Sneha Karma -** Oral administration of

a) Triphala ghritha b) Mesha shrungi ghrita

c) Purana ghritha d) Ksheeri sarpi

e) Kakolyadi ghritha f) Vidari gandhadi ghritha

(oleation and shodhan with one of the above)

2) Raktha mokshan (sira vyadana)

3) Rechana -

a) Sharkara, Ela, Trivruth churna + Madhu

b) Triphala Churna + Ghee (cow ghee)

4) Cool applications to eye lid and eye drops (Shirolepa, mukha lepa and varthma lepa)

5) **Anjan :-**

a) Sariba, padmaka, usheera, mukta, lodra, chandana-as varthi anjana

b) Tejpatra, kamala, Anjan, Nagkesar, karpoor, yastimadu, swarna gyrika - as choornanajan.

c) Rasanjan, cheeni, manahshila, madhu, Yastimadu-as Rasa krianjan

d) Rasanjan or Sauveeranjan + Equally tutta as pratyanjan

e) Sauveeranjan 5 parts + Tuttam 5 parts + Karkatak Shrungi 3parts + Aamalaki 3 parts + Spatika 1 part + Karpoor 1 Part used as anjan

6) Nasya And for oral administation :-

a) Ksheeri sarpi or ghritha manda

b) Kakolyadi ghritha c) Vidharigandhadi ghritha

d) Jeevaneeya drugs + Sheeta veeya drugs + sharkara + Cow milk + cowghee The pakwa ghritha is used for nasya

VIII) Metabolic Cataract :-

It occurs due to impairment of Lens and body metabolism

1) Diabetic cataract :- Diabetic people get the cataract earlier than others among the lesions, 70% Anterior corbical cataract, 21% nuclear cataract, 7% posterior cortical cataract and 2% subcapsular cataract. punctate flasky white opacities appear with plenty of vacuoles - Gradually due to hydration complete lens becomes opaque.

2) Galactocaemic cataract:- develops in infants due to inability to metabolise galactose in to glycogen owing to absence of enzymes (Galactose I phosphate urivdyl transferase)

3) Hypo calcaemic cataract :- Hypo calcaemia (and more calcium in Lens) Produces osmotic pressure differences between aqueous (Less osmotic pressure) and Lens (more Osmotic pressure), causes imbibition of fluids in to Lens leads to opacification.

4) Hypothyroidism Cataract :- Small flasky opacities develop in superficial cortex of Lens and does not obstruct the vision.

5) Myotonic cataract :- Lenticular changes occur due to intence contraction and Less relaxation of muscles, the punctate opacities develops and after long time total Lens may become opaque.

6) Defficiency cataract :- Reduction of Amino acids, soluble proteins, Glutathione, Ascorbic, acid Riboflavine, Nicotinic acid, vitamin A and D etc. and changes in sodium potassium ratio and calcium phosphate ratio causes the formation of cataract.

7) Amino aciduria or organic aciduria :-

Essential amino acids are eliminated out due to metabolic deffects and other causes, leads to cataract formation.

IX) Syndermatotic Cataract:

Cataract formation is due to skin lesions like 1) Atopic dermatitis (Eczema): sub capsular plaque radiating to anterior and posterior cortex develops (It is a heriditory tendency - constistutional allergic basis)

2) Rothmund syndrome - Cataract and skin lesions are associated

3) Warner syndrome - Subcapsular and posterior cortical opacities (Striae) develops and soon become intumescent and mature.

X) Cataract with multiple syndromes

1) Vander hoever's syndrome :- syndrome of Brittle bones, Blue sclera and deafness with zonular or conical cataract.

2) Conradi's syndrome -

widespread skin lesions, mental retardation and Total cataract

3) Mandibulo oculo facial dyscephaly (Bird face) -

along with Microphthalmos micro cornea, congenital Bilateral partial or total cataract are associated

4) Marfan's syndrome :-

Spherophakia, dislocated Lens and with localised Lenticular opacities

5) Turners syndrome :-

Development of cataract due to long standing retinal detachment

6) Mayriac's syndrome:-

development of typical diabetic cataract

7) Torsten sjogren Syndrome :-

Zonular or total or Anterior polar or posterior cortical cataract develops.

8) Mongolism :-

Punctate arcuate sutural Lenticular opacities develop

9) In certain anomalies of Brain also Lenticular opacities develops

CATARACT SURGERY

1) Discission or Needling
2) Needling and aspiration
3) Extraction of Lens
   a) Intra capsular Lens extraction
   b) Extra capsular Lens extraction

These methods are in complete and complicated, so not practicing

4) Intra Ocular Lens implantation (I.O.L)

Investigations before operation :-

1) Patient should have pupillary reaction to light
2) Perception of light, 3) Projection of Light, 4) good macular function
5) Catract should be in mature stage, (should identify only hand movements no fundal glow at pupillary region lens should appears as white pearl through pupil, No Iris shdow and 3 rd purkinje's image)
6) Patient should not have infection of conjunctiva Lacrimal sac, eye lids, eye margins, uveal tract sclera and cornea etc.
7) Intra ocular pressure should be normal, if not should be controlled
8) urine for sugar and albumin should investigate, if positive should be controlled.
9) Bloodpressure, Bleeeding clotting time, should be estimated and controlled
10) Other routine invoestigatons should also do to control the complication for the success of operation.

7) Putapaka :- With Jangala mamsa + Ksheeri sarpi + Madhuradi gana drugs (Like Kakolyadi drugs) are used

8) Oral adminstration of

a) Triphala churna + Ghritha
b) Triphala Kashaya + Ghritha
c) Triphala Yastimadu, Loha bhasma, Ghritha and Madhu
d) The medicated ghee prepared from, Bala, shatavari, kakoli Mishri syreyaka, Triphala and ghee is used for oral administration

Pittaja Kacha Chikitsa

1) Raktha mokshana contraindicated
2) meshashrunga, Sauveranjan, Rasanjan, srotoaanjan are useful
3) Phalasha pushpa , Rohitha pushpa , Madhukapushpa + madira + madhu as Rasa Krianjan

KAPHAJ TIMIRA CHIKITSA

1) Ghritha prepared with Giloya kwatha, Triphala - pippali Kalka ghritha and given for oral administration
2) Rakthamokshan
3) a) Rechan with the decoction prepared with poogiphal, Haretaki, Shunthi, pippali, Trivruth, Danthee beeja - Given for oral administration.
b) Trivruth ghritam oral administration for virechan.

4) Nasyam with:-

a) Tailam prepared with usheera Lodra Triphala priyangu, taila,
b) Gomaya taila
c) Tailam prepared from Hreebera, Devadaru, Haridra, Daru haridra (Kalka), Milk dashamoola Kwatha and Tila taila.
d) Maricha yastimadu Vidanga Devadaru .

5) Anjana

a) Manahshila Trikatu shankha bhasma madhu saindhava lavan Kaseesa Rasanjan + Water, as Rasa Kriyanjan
b) Kaseesa Rasanjan Shunthi Guda as Kasakrianjan.
c) Vimala Varthi Anjan :-
Shankha priyang manashila trikatu triphala Lohabhasma, Trikatu, saindhaval avan, Triphala Rasanjan
d) Kokila varthi anjan:- Maricha saindhava Lavana, pippali, samdraphena, sauveeranjan.
f) Hareetakyadi Varthi:-
Haretaki 1 part, Haridra 1part, pippali 1part, saindhava lavan 1/4

g) Sukhavathi varthi :
Nirmali phala shankha bhasm, Trikata, Saindhava lavan cheeni, samudra phena Rasanjan vidanga manashila Kukkutanda twak + water and Honey
h) Chandrodaya Varthi - Hareetaki, vacha, Kusta, pippali, Maricha, vibheetaki, shanka nabhi, Manshila + Aja Ksheera

6) Dhoom - With vidanga, patha, Apamarga, usheera, Ingudee

7) Tarpan :- With the medicated ghee prepared from Ksheeri vruksha Kashaya 4 parts, Haridra and usheera kashaya 1/4 part, ghritha 1part.

8) Putapaka:- With jangalamamsa, pippali, madhu, saindhava lavana, etc. medicines

Kaphaj Kacha chikitsa : - Rasakriyanjan :- Guda, samudra phena, sauveeranjan, pippali, maricha, Kumkama, madhu

Sannipathaj Timira Chikitsa

1) All the treatments explained previously should used according to the necessity
2) Anjan :- The medicated ghee prepared from usheer kwatha + pippali saindhava lavan + Ghrita + Honey .
3) Nasya :- lastimadu kadi taila (yastimadu vidanga maricha devadaru taila cow milk)

Sarvaj Kacha chikitsa

Anjan :- Sauveeranjan shouuld heat immers in Asta mutra and triphala Kashya 7 to 21 times - prepare the fine powder and should fill it in long bone of (in marrow space) Nisha char animals by perfect packing and should kept it in water for a month after that the powder should be collected and grind with Mesha shruga pushpsa swarasa or Yastimadu churnag for anjana.

PARIMLAYI TIMIRA CHIKITSA AND RAKTAJ TIMIRA CHIKITSA

1) Like pittaja Timira chikitsa
2) a) Drakshadi varthi anjan (Draksha, usheera, Lodra, Yastamadu, Shankha, Tamra, padmaka, chandana, Aja Ksheera)
b) Karpora Samudraphena swetha Kanchana and Chandana.

Intra capsular Lens extraction:-

Removal of Lens with its capsule, is known as intra capsular lens extraction (Vitreous loss is the major complication after some period)

Preparation of the patient :-

1) One day before, the patient should be admitted inthe hospital, in the morning laxatives and at night sedatives should give to controle the tensions of the patient.

2) On the day of operation, light breakfast should give, eye lashes should cut-from their bases, and clean property.

3) Half an hour before the operation 2% G. homatropine drops (Pupil dilator) should put 3 to 4 times with 10 minutes interval

4) Anaesthesia :-

a) 4% Cocaine drops with adrenaline (1:1000) should put in Conjunctival sac 4 to 5 times with 5 minutes interval

b) Facial nerve should be blocked with 2% Novacaine solution, 1-2 cc, should inject at temparo mandibular joint, to paralise orbicularis oculi muscle.

c) Retro bulbar ciliary block, with 2% Novocaine solution, 1/2 to ICC, should inject at the junction of medial 2/3 and Lateral 1/3 of Lower orbital margin, needle should pass backwards medial and slight upwards, to paralise the iris, to reduce intra ocular pressure and to dilate the pupil .

Stepes of Operation :-

1) Eyelids should be sterilized with spirit, conjunctival sac should be washed with normal salina face mask is put and eye lids are separated with universal eye speculum.

2) Conjunctiva episcleral tissue is hold at timbus in 6^0 clock position with fixation forceps, conjunctival flap should be separated at the site of incision.

3) Cataract knife with its sharp edge, to wads the sugeon is introduced from the temporal side (9^0 clock position in right eye, 3^0 clock position in left eye) after passing through the anterior chamber, counter puncture is made at the opposite limbal area and by sawing movements the upper segment of sclero corneal junction is cut.

4) Sutures are given widely to keep the cornea in position, the incised corneal flap is bended down wards to face the anterior chamber and Iris.'

5) With Iris forceps - Iris scissors Iridectomy should perform at pupillary area for easy lens extraction and to prevent glaucoma

6) Lens with capsule should be extracted by separating it from suspensary ligament with intra capsular forceps by the gentle pressure and rotatory movements from the periphery of anterior lens capsule at 6^0 clock position and lens is removed. 7) Iris is reposited with a repositor .

8) Suturing should complete and air is inserted into anterior chamber with syrenge to form anterior chamber without adhesions

9) Conjunctival flap is resposited, G. pilo carpine drops are inserted (to con strict the pupill) and bandaged.

10) Patient should lie flat on his back for 24 hours.

11) Next day bandage should be removed and observed for any conjunctival discharges oedema, condition of anterior chamber, pupil Iris and aqueus whether they are normal or abnormal and also asked about perception of vision (counting the fingers etc)

12) G. pilcarpine drops should continue for 5 days, later G. atropine drops should continue for 5 weeks

13) Operated eye should cover with a pad for a month, later proper powered spectacles are given

The aphakia 9) Absence of Lens) is corrected by -

for **Distant vision** 10.00.D. spherical lens

If astigmatism associated + 2 or 3. D. 180 Cylindrical lens should be added

for **near vision** - 13.00 D spherical, + 2 or 3.D. 180^0Cylindrical lens, should used

	Spherical	Cylindrical lens	Axis
Distant vision	+ 10.00 D	+ 2 or 3. D	180^0
Near vision	+ 13.00 D	+ 2 or 3. D	180^0

EXTRA CAPSULAR LENS EXTRACTION

Extraction of Lens matter by leaving the capsule inside (Chances of after cataract which may need second operation in future - Vitreous prolapse is not present)

Method :- a) Preparation b) Anaesthesia c) Corneal incission d) iridectomy are same as intra capsular extraction)

Anterior Lens capsule is incised with a cystitome or with cataract knife with, the tip of lens expressor lens matter is removed from the lower part by firm counter pressure on sclera at 12 0 clock position Or after incission of capsule the Lens matter can be removed by cryo's apparatus.

Note :- Post operative care is as like intra capsuler or extraction.

INTRA OCULAR LENS IMPLANTATION (I.O.L)

Operative technique is like extra capsular extraction but after extraction of Lens matter, artificial Lens is introduced into capsule instead of spectacle.

3) Nasya with
a) Anutaila
b) Vidarigandhadi Ghritha
c) Kakolyadi ghritha
d) Ksheri sarpi

Note : - In Kacha all the treatments of Timira can be given except Raktha mokshana, if Raktha mokshana is compulsary Jalaukamokshana can be advised

KAPHAJ LINGANASHA SHASTRA CHIKITSA

Indications of kaphaj Linganash shastra Chikitsa :-

1) Completely formed or pakwa drusti (Mature cataract)
2) Hard (Solid state, not semi solid)
3) with Complete loss of vision
4) only kaphaj linganash
5) Drusti should not contain following 6 abnormalities.
   a) Aavarthaki - Chala drusti with black and red colour.
   b) Sharkara - Vere hard drusti like arka ksheera
   c) Rajeemathee - Thin elongated drusti with lines like shali shooka (Rice grains with capsule)
   d) Chinnamshuka - Irregular drusti with cutting pain and burning sensation.
   e) Chandrakee - drusti is bright as Bronze and multi pigmented like pea cock feathers.
   f) chathrakee - Drusti is multi pigmented and resembling umbrella (Vagbhata)

7) Drusti Should not Contain the following features.
   a) Semi lunar shape b) like sweat drop c) like a pearl d) fixed (Sthira) e) Vishama (irregular) (These symptoms are seen when associated with Iritis, Synechia and immature cataract) f) Thin at central part g) with vessels h) Bright (Partial opacification) i) Painful (If associated with glaucoma) j) Blood collections (Uveitis with hypaema) (sushrutha)

8) The Apakwa linganash (immature cataract) is contra indicated because the drusti is imperfectly formed, irregular, thin like cheese on curd, spreads upwards during surgery, causes pain etc. complications and drusti revitiates even after surgery so only apakwa linganash is contra indicated for surgery.

9) The common contra indications of siravyadan are also applicable here

10) Only kaphaj Linganash without other doshic vitiations is indicated for the surgery.

PROCEDURE OF KAPHAJ LINGANASH SHASTRA CHIKTSA

In a normal season , after sneha sweda karma. the patient is asked to sit down on a stool comfortably, asked to see towards nasal side, and should give co operation while the operation, The head and Limbs should be properly holded by the assistants not to move during the operation. The eyes are properly opened to expose the middle part of eye perfectly. " Vyadana Karma has to do with Right - hand in left eye operation and with left hand in Right eye operation". The instrument used for yadana Karma is "YAVA VAKRA shalaka, The puncturing area is known as " DIIVA KRUTHA CHIDRA" where blood vessels are absent and so doesn't cause bleeding complications.

Selection of the Site of vyadana karma:-

1) 2 Part sof Shukla mandala towards apanga should leave for puncturing (Sushrutha)

2) 1/2 angula from Krishna mandala and 1/4 angula from apanga should leave for puncturing (Vagbhata)

While puncturing proper care should be taken if not, cause so many complications

Signs of adequate vyadana karma :-

1) No Pain 2) Some specific sound comes during puncturing
3) Water bubble like dosha comes out through punctured area
4) Drusti prapthi (Visualisatiion)

Signs of in adequate vyadana Karma :-

1) Pain 2) Bleeding 3) Lacrimation 4) Oedema 5) Hyperaemia 5) Head ache 7) Improper visualisation obstructed vision (vyadan karma is not get succeded again sneha sweda vyadan should perform)

Post vyadana regimen:-

1) Stanya pariseka
2) Vata Kapha hara mrudu sweda (Kara sweda).
3) Gentle pressure on eye ball with blunt end of shalaka to expel the Kapha perfectly.

4) Blowing out the nose by closing the opposite nostril (ucchinghan) to expel out the residual kapha.
5) After perfect elimination of doshas
If vision is normal Ghritha drops instillation or ghritha pichu should put at the site and Netra bandana(eye bandage) is applied.
6) Patient is advised to lie down on opposite side or in supine position
7) for every 3 days Bandage should be removed for Cleaning, mrudu sweda and for observation- up to 10 days.
8) Langhana or post oleatiion regimen should follow
9) Bed rest 10) following pathya vidhi up to 10 days
11) Application of Drusti prasadan anjanas

Apathya :- Contra indications for the maintenance of health
1) Sneezing 2) Coughing 3) Blechings 4) spittings 5) Bending the head 6) Drinking more liquids 7) Bathing 8) Brushing of teeth 9) Eating hard or solid items. 10) Body movements etc are rejected for 10 days ofter operation

TREATMENTS FOR THE COMPLICATIONS:

1) in red eye or haemorrhagic lesions due to vyadana karma in improper place - is treated with Yastimadu - ghritha + stanya pariseka.
2) If vyadana Karma did more nearer to Apanga, causes pain oedema exudation etc lesions in that condition Bhru madya mrudu sweda and lukewarm ghritha pariseka advised.
3) If vyadana karma didi more nearer to krishna mandal, causes inflammation, at that condition virechan, Jalaukamokshan, Luk ewarm ghritha Aashcyotan advised
4) In Atiyoga of vyadana karma, sneha sweha Anuvasan Vasti are advised. In apakwa Linganash extraction Luke warm madhura ghritha Aashchyotan and shiro vasti should do

5) In pain burning sensation oedema and in Hyperaemia:-

a) sariva gyrica Doorva yava + Ghritha (Pakwa ghritha) mukha or varthma lepa
b) Fried Tila and swetha sarshapa, should grind with Mathulunga swarasa for mukha or varthma lepa
c) Draksha yastimadu Kusta saindhava, lavana grinded with Aja ksheera for mukha or varthma lepa.
d) Ksheera Kakoli sariva Teja patra manjista yastimadu grinded with Aja ksheera for mukha or varthma lepa.

e) Devadara, Daru haridra padmaka shunthi grinded with Ajaksheera for mukha lepa or varthma lepa.

6) Pariseka or Aashchyotan yogas
a) Lodra saindhava lavan Yastimadu Draksha kwatha + Aja Ksheera as eye drops
b) Yasti madu, Nelothphala, Kusta, Draksha, Laksha, sharkara, saindhavalavana, Kwatha+ Aja Ksheera as eye drops
c) Shathavari, prushni parni, musta, Aamalaki, padmaka (Kalka), Aja ksheera ghritha (Pakwa ghritha) used as eye drops.
d) Bhadradarvadi Kakolyadi ghritha - Lepa seka Anjan.

7) If pain is not relieved with above treatment (lalata, Apanga, upanasika). Dhaha karma is adviced .

8) Drusti prasadan Anjanas
a) Mesha shrunga pushpa shireesha pushpa dhava pushpa jathee pushpa Muktha pisti Vydoorya - Grindred in Aja Ksheera Pasted and kept in a copper vessel for a week - varthi is prepared and Anjana is given with Rose water.
b) Srotonjan Pravala samudra phena manashila maricha grinded with Aja Ksheera - Varthi Prepared and Anjan is given with Rose water.

7) PITTA VIDAGDHA DRUSTI

(Day blindness)

The vitiated pitta dosha deranges the drusti produces yellow pigmentation to the drusti and visualises the objects in Yellow colour if doshas spread into 3rd patala causes day blindness (can not see the objects at day time)Due to pitta prakopa but can see the objects at night due to pitta shaman.

It is pittaja aushada sadya vyadhi (Ashastra Krutha)

It can be corelated to central opacity of Lens and cornea macular lesions central retinal lesions, retinitis pigmentosa, Amblyopia etc.

8) KAPHA VIDAGDHA DRUSTI

(Naktandya) (Night blindness - nyctalopia)

The vitiated kapha dosha deranges the drusti, prouced white pigmentation to the drusti and visualise the objects in white colour. if dosheas spread in to 3rd patala causes night Blindness (Cannot see the objects at night) due to kapha prakopa but ue to Kapha shaman or Kapha vilayan can see the objects at day time.

It is kaphaja Aushada sadya (Ashastra kruth) vyadhi. It can be corelated to Night blindness due to vitamin A deficiency and peripheral retinopathy.

1) **Aphakia** - Absence of the crystalline lens in the eye.

Causes :- 1) Operative removal of the Lens due to cataract formation 2) Dislocation of lens into vitreous humour 3) spontaneous absorption of the Lens after discission.

Clinical features :- 1) Dim vision (high Hyper metropia) 2) Jet black pupil 3) deep anterior chmaber 4) Tremulousness of Iris (Irido donesis) 5) Absence of 2nd, 3rd purkinje's images 6) absence of accommodation 7) Linear scar at upper Limbus if aphakia is due to cataract operation.

TREATMENT :-PRESCRIBING CONVEX SPECTACLE

Distant vision = + 10.00 D sperical and
+ 2 or 3 180° cylindrical Lens

Near vision = + 13.00 D sperical and
+ 2 or 3. 180° cylindrical Lens.

2) Microphakia - Smaller Lens (It is a congenital abnormality)

3) Spherophakia = Presence of spherical Lens

4) Lenti conus = Presence of conical shaped Lens

5) Cataract = opacification of Lens

6) Ectopia Lentis = Due to weakness of zonule the Lens is dragged to the opposite side.

7) Sublaxatin of Lens = Partial dislocation of Lens.

8) Luxation of Lens =
Dislocation of Lens either into Anterior chamber or posterior chamber

9) Coloboma of Lens = Improper formation of Lens

10) Immature cataract = Partial opacification of Lens

11) mature cataract = Total opacification of Lens

12) Lental sclerosis = Degeneration of fibres of Lens (nucleus) by age.

13) After cataract -
These are the opaque Lens residues when the Nucleus and cortex are removed by an extra capsular extraction operaton.

DISEASES OF UVEAL TRACT (VASCULAR LAYER OF EYE BALL)
TERMINOLOGY OF UVEAL TRACT LESIONS:

1) Uveal tract = Iris ciliary body and choroid
2) Anterior Uvea = Iris and ciliary body
3) Posterior Uvea = Choroid
4) Uveitis = inflammation of Uveal tract
5) Iritis = inflammation of Iris
6) Cyclitis = inflammation of choroid
7) Choroiditis = Inflammation of Choroid
8) Irido cyclitis = Inflammation of Iris and ciliary body
9) Anterior Synechia - Adhesion of Iris with cornea
10) Posterior synechia - Adhesion of Iris with Lens.

11) Iris bombi - due to seclusio pupillae Iris bulged forwards due to pressure of aqueous humour, known as Iris bombi

12) Irido donesis - Moving of iris along with head movement due to Aphakia or subluxation of Lens.

13. Irido dialysis - separation of Iris from ciliary body

14. Rubeosis iridis - formation of new vessels on Iris due to diabetes etc causes.

15) Iridencleisis - A piece of Iris is included in a scleral wound at limbus as filtering wick through which Aqueous flows out into sub conjunctival space and intra ocular pressure is reduced, it is done especially in peripheral anterior synechia

16) Irotomy - This operation is carried out to lower the intra ocular pressure in cases of Iris bombe and secondary glaucoma in which 4 punctures are made in the Iris for proper aqueous circulation.

17) Iridectomy dialysis - Taking a part of iris from its ciliary attachment to open the angle of anterior chamber.

18) Peripheral iridectomy ;- making a small button hole in the peripheral part of Iris for free circulation of aqueous humour.

19) Enucleation - Removing of eye ball in absolute glaucoma, malignant intra ocular tumours, phthisis bulbi and sympathetic ophthalmia.

20) Evisceration:- In panophthalmitis etc lesions the suppurative infective material of eye ball is scooped out after removal of cornea by leaving only scleral cup.

TREATMENT PRINCIPLES OF PITTA VIDAGDHA DRUSTI AND KAPHA VIDAGDHA DRUSTI

A) In Pitta Vidagdha Drusti

1) Ashastra Krutha (Aushada Sadya.)
2) Pitta Dosha hara chikitsa should give .
3) Pittaja Abhishyanda chikitsa should give .
4) Oral administration of Triphala ghritha or Tilwaka ghrith for Oleation.
5) Vaman etc shodhan Karma should do for body purification
6) Local Treatments like seka, Aashcyotan,Tarpan, Putapaka, Anjan, Nasya etc. should give.
7) Oral administradtion of Chakshushya drugs.

B) In Kapha Vidagdha drusti

1) Ashastra Krutha (Aushada sadya)
2) Kapha dosha hara Chikitsa should give
3) Kaphaja Abhishyanda Chikitsa should give
4) oral administration of Trivruth ghritha or Tilwaka ghritha or purana ghritha for Oleation.
5) Vamana etc shodhan Karma should do for body purification.
6) Local Treatment like seka, Aashchyolan, Tarpan, putapaka, Anjan, nasya etc. should give.
7) Oral administration of Chakshushya drugs.

COMMON ANJANA YOGAS FOR PITTA VIDAYGDHA DRUSTI AND KAPHAVIDAGDHA DRUSTI

1) Gyrica, Saindhava lavan, pippali Godantha masi (Equal parts).
2) Gomamsa choorna, maricha, shireshabeeja, manahshila (equal parts)
3) Kapittha vruntha + madhu - as anjan
4) Swayam guptha beeja + madhu-as anjana
5) Kubjak, ashok chal, Amra, priyang, padmaka, Neelothphala, Renuka, pippali,Hareetaki, Aamalaki + Madhu or ghee, The medicine should preserve in vamshi naala (tube of the bamboosa stick) as Anjan.
6) Arma jambu pushpa rasa, Renaka + madhu ghritha as anjan
7) Rakta padmaka or kamala Neelothphala kesar gyrica should grind with Gomayaras and used as gutikanjan.

ANJANAS IN PITTA VIDAGDHA DRUSTI

1) Rasanjanaadyanjan :- Rasanjan Jathi patra ras (Or ghee or Aamalaki) madhu Taleesa Patra, swarna gyrica , should grind with Gomaya rasa and used as choornanjan.

2) Kashmaryaadyanjan :- Kasmari pushpa Yastimadu Daru haridra, Lodhra, Rasanjan, fine powder prepared and given as anjana with madhu.

3) Saindhavadyanjan :- Saindhavalavan, mudga, Trikatu, Sauvereranjan, manahshila, Haridra, Daruharidra, Goyakruth, Swetha Chandan, used either as choornanjan or Gutikanjan.

4) Swarna bhasma + gheee or Honey - as anjan
5) Gomayarasa + go ksheera + Goghritha (pakwa) as Rasakriyaanjan.
6) Swarna gyrica + Talisa Patra choorna as Rasakriyaanjan
7) karpooraadyanjan :- Karpoora Sauveranjan, Should grind with mamsarasa, Koorma or Rohit matsya pitta and used as Ananjana.

Anjanas in Kaphavidagdha drusti or Nakthandya

1) Srotonjan, saindhavalavan Pippali Renuka should grind with Aja mutra for varthi anjan
2) Renuka pippali (Vitusha beeja) Sukshma ela, should grind with Gomaya ras or yakruthrasa for anjana.
3) Pippali of yakruth pippali yoga + madhu as anjan.
4) Fried (In ghee or taila) Yakruth or pleeha, grinded with sarshapa taila - used as anjan.
5) Maricha rubbed in curd, the essence is used as anjana.
6) Shaphari matsya Kshara as anjan
7) Hingula or Tankana or Karnamala + madhu, as anjan.
8) Ghritha + Gomaya rasa + madhu - as Rasa Kriyanjan.
9) Gyrica + Talisa patra as Rasakriyanjan
10) Tagar Trikatu Triphala Haritala manahshila samudra phena, grinded with Ajaksheera and used as varthi anjan.
11) Karanja Neelothphala swarna gyrika, kamalkesar, grinded with gomaya ras and used as varthi anjan
12) Pure vatsanabhi choorna manhshila grinded with mathulunga swarasa for anjana (R.R.S.)

CONGENITAL ABNORMALITIES OF UVEAL TRACT

1) Persistent pupillary membrane:- The pupil in the foetus is closed by a thin membrane that disappears in the 7th month of foetal life. But some times a few shreds of this membrane remain and called persistent pupillary membrane, it causes visual obstruction.

2) Congenital Aniridia:- Failure of the development of Iris (A rudimentary Iris present - smaller and hidden behind the sclero corneal margin)

3) Congenital coloboma of Iris and choroid:-
Imperfect development of Iris and choroid with gaping.

4) Coloboma of Macula:-
Defect in the choroid at the region of macula.

5) Albinism :- Deficiency of pigment in the Uveal tract gives rise to photophobia defective vision and nystagmos.

6) Hetero chromia Iridis - The 2 Irides may be in different colour or one sector of the Iris has a different colour from the rest of the Iris tissue.

7) Choroideremia:- Entire or partial absence of the choroid.

IRITIS

IRITIS :-
It is the inflammation of the Iris, often associated with inflammation of ciliary body hence called Irido cyclitis (Anterior uveitis)

Causes ;-a) Exogenous inflection (perforated corneal ulcer, penetrating injury to the eye ball)
b) Secondary infection (From interstitial keratitis, scleritis)
c) Endogenous infection (Via blood stream such, as syphilis Tuberculosis, Leprosy, Gonorrhoea, Brucellosis, toxoplasmosis)
d) Allergic reaction (Bacterial toxin, Lens protein, symphathetic ophthalmia)
e) Metabolic disorders (Diabetes, gout, Rheumatism)

Pathology:-
Inflammation of iris causes 1) exudation of albuminous fluid with lecucocytes and fibrin into stroma and anterior chamber 2) collection of unusual exudates in the stroma causes oedema of iris 3) Aqueous becomes turbid with hypopyon and hyphaema 4) Irritation to sensary nerve endings causes pain 5) changes in the pupillary reaction 6) Formation of posterior synechia (Adhesion between Iris and Lens) 7) Occlusio pupillae (collection of exudates in the pupil 8) seclusio pupillae (Adhesion of whole pupillary margin to the Lens capsule) 9) Development of degenerative patches on Iris due to chronic inflammatory changes.

Symptoms:-
1) Pain in the eye that radiates to forhead cheek and teeth
2) Lacrimation and photophobia due to reflex irritation.
3) Dim vision due to turbidity of aqueous, collection of exudates in pupil, and due to posterior synechia.

Signs:-
1) Circum corneal congestion (due to Anterior ciliary vessels)
2) Some extent of Conjunctival congestion
3) Anterior chamber is hazy deep with hypopyon or hyphaema.
4) Iris is muddy in colour due to collection of exudates
5) Pupil small irregular and sluggish in reaction to light
6) ciliary tenderness when associated with cyclitis

Complications
1) Posterior synechia
2) Occlusio pupillae
3) Seclusio pupillae
} cause secondary glaucoma
4) Complicated cataract
5) Corneal opacities

13) Trikatu Keep in Aja yakruth and allow to dry later on Trikatu should be collected and anjana given with chiri Bilwa rasa (R.R.S) .
14) Maricha grinded with the blood of bed bug, used for anjana (R.R.S).
15) Rasanjan Haridra, Daru haridra jathipallava Nimba pallava, grinded with Gomaya rasa for anjana
16) Triphala grinded with yakruthras - as anjan.
17) Tagarqqdyanjan:- Tagara pippail shunthi Yastimadu Talis patra Haridra darau haridra musta etc are grinded with yakrath rasa fro anjana
18) Renuka, pippali aja asti- majja Ela Aja yakrth - Grinded well and given as Anjana .
19) Manashila Hareetaki Trikatu Bala Tagara Samudrapena - Grinded with goat's milk for anjana.
20) Go mutra, go or Aja pitta madyam Yakruth Aamalaki Swarasa - Grinded and used as Anjana .
21) Gomootra Gogritha samudraphena pippali Katphala saindhava lavan and madhu Rasakriya is prepared and preserved in the Vamshi Nala (Cavity of bomboosa Stick)
22) Aja vasa yakruth and ghee pippali saindhavalvan madhu Aamalaki swar as Rasakriyanjan
23) Srotoanjan grinded in Yakruthras as anjan

Nasya 1) Brungarajadya tail
2) Nrupavallabha taila
3) Abhijith taila
4) Medicated ghee prepared with medha Lodhra guduchi manjista daruharidra Yastimadu tila taila and go ghritha.

Tarpana With Ksheeri sarpi :-

Oral Remedies :- 1) Triphala ghritha 2) maha Triphala ghritha 3) Nrupa vallabha ghritha 4) Maha Triphaladya ghritha 5) jeevanthyadi ghritha 6) Patoladya gritha 7) Ksheeri sarpi or purana ghritha (daily usase with meaals).8) Triphala choorna or Kashaya, with ghee 9) Mahavasadi quath 10) Yakruth Pippali voga (Puta Paka) 11) Yakruth or pleeha of a cow and goat which is fried in taila or ghritha is gred in Taila or ghritha 12) Tamboola Yaktam khadyotam (the small sparkling creature with betal leaf)13) Rohitha matsya eggs + brunga ras. 14) Oral intake of Jeevanthi Atimuktha (Madhaveelatha) Erenda shephalee Shatavaree etc. Leaves which are fried in ghee 15) Sapthaa mruta loha.

9) DHOOMADARSHI
(Smoky Vision or Hazyvision)

It is pittaja sadya vyadhi in which drusti is vitated due to headache fever exertion and crying etc causes and visualise the things as smoky or hazy

It is a symptom appears commonly in the errrors of refractive media (Precipitations in aqueous and vitreous, Retinal lesions inflammation of cornea(Keratites) refractive errors like myopia hyper metrpia etc. corneal oederna immature cataract uveitis Glaucoma etc.) The transparent media be comes hazy so only visualises the things as hazy.

USHNA VIDAGDHA DRUSTI
(By vagbhat)

It is a disease of drusti occurs due to ushnabhitapthasya jala praveshaath etc causes (Exposure to cold immediately after exposure to heat) Because of immediate opposite exposures The tridoshas and Raktha vitiates, the vitiation reaches the head, eyes, and so the person visualises the things imperfectly at day time and cannot visualise at night.

AMLA VIDAGDHA DRUSTI
(By Vaghbhata)

It is a lesion of drusti, occurs due to excess usage of sour (Amla) things, the Tridoshaas and Rakatha vitiate the drustimandala and causes collection of exudation and dirt in drusti mandal, itching sensation and visual errors.

Note : - Amla vidagdha drusti, Ushna vidhgdha drusti, Dhooma darshi and pittavidagdha drusti are having similar treatment principles

10) HRASWA JADYA

It is pittaja asadya vyadhi in which drusti mandal is vitiated, causes difficult and imperfect vision at day time and bigger objects are seen as smaller.

Commentry - 1) Vision is very poor at day time it self so at night the patient cannot see any thing .
2) Poor vision at day time may get vision at night due to pitta shaman it can becorelated to Retinitis pigmentosa etc,diseases.

11) NAKULANDHYA
(A type of night blindness)

It is Tridoshaja Asadya Vyadhi in which drusti mandal is vitiated causes shining of the drusti as like mangoose, visualises the things in multi colours and so cannot see the things at night

Treatment 1) Improvement of general health
2) Analgesics - Antibiotics
3) Sub conjunctival hydro cortisone injections
4) Atropin eye ointment
5) Cause should be treated 6) using of dark goggles
7) Surgical interference

Specific varieties of Iritis

1) Syphilitic Iritis:-
a) in severe congenital syphilis, pseudoglioma may develop with interstitial keratitis
b) In late secondary or tertiary stage, yellowish vascularised nodules (Gummatus iritis) appear at pupillary margin and at ciliary borders of iris
c) Plastic exudation that may cause broad posterior synechia
d) Nodules heal leaving depigmented patches
e) Washer mann and kahn reaction positive

2) Gonorrhoeal iritis:- Greenish gelatinous fibrinous exudates in anterior chamber and with Extensive posterior Synechia.
3) Tuberculous iritis:- Mutton fat keratic precipitates, Koeppe's nodules at pupillary margin, hypopyon with caseating material and thesclero corneal junction is eroded ultimately.
4) Diabetes Iritis:- Formation of new vessels on iris (Rubeosis iridis), definite hopopyon and secondary glaucoma
5) Allergic Iritis: Lens protein allergy in Extra capsuler lens extraction followed by second operation (needling for cataract).
6) Reiter's Uveitis:- Uveitis associate with spondylosis, sacroiliitis with the history of urethral discharge. The clinical features are ocular pain ,congestion, fibrinous exudation in anterior chamber and with posterior synechia.
7) Stills disease :- Juvenil rheumatoid arthritis with chronic Uveitis (Band degeneration of cornea, complicated cataract and Blindness)
8) Sarcoid Uveitis:- This type of anterior Uveitis associated with the presence of Iris nodule at ciliary Junction, Large pale K.P may be present ,it associate with sarcoidosis in bones, skin, viscera, Lymph glands and lungs (sarcoidosis is a mild or attenuated Tuberculosis)
9) Leprosy Uveitis:- Iris nodules develops which contain leucocytes and Leprosy bacillus. K.P. and other common signs of Uveitiis are also present.
10) Herpes simplex Uveits :- It is a sequel to herpetic keratitis
11) Herpes zoster Uveitis:- It associates with herpes zoster ophthalmicus.
12) Hetero Chromic Uveitis :- Associate with atrophic and discoloured Iris.

CYCLITIS

It is an inflammation of ciliary body. It always associate with some degree of Iritis, so usually termed as Irido cyclitis or anterior uveitis.

A) Acute cyclitis:-
Aetiology - Same as Iritis
Pathology - 2 types, as follows

a) Serous type :-
The inflammatory exudate poured into anterior chamber is albuminous and toxic, causes impairment of corneal endothelial nutrition and the inflammatory cells sticks to the lower triangle of cornea, called Keratic precipitates.

b) Plastic type:- The fibrinous exudate which poured into posterior chamber organises and causes total posterior synechia
The exudate which has extended into anterior vitreous produces cyclitic membrane behind the lens, The fibrinous exudate of vitrious may cause retinal detachment, the exudate that organised in the medial surface of ciliary body causes destruction of ciliary Process that results reduced aqueous secretion and producing hypotony (phthisis bulbi) of eye ball.
II) Signs and symptoms of Acute cyclitis:

A) Serous type :-
1)Pain and redness of eye ball
2) Moving spots before the eye
3) Dim or hazy vision
4) Circum corneal congestion
5) Ciliary tenderness
6) Grey spots on the posterior suface of cornea (Keratic precipitates -K.P)
7) Deep anterior chamber
8) Cloudy aqueons
9) Oedema of eye lids.
10) Raised intra ocular pressure at first, later intra ocular pressure reduces.

B) Plastic type :-
1) Extensive posterior synechia
2) Deep anterior chamber
3) Formation of cyclitic membrane behind the lens
4) Hypotony of eye ball
5) phthisis bulbi results.

Treatment :- As like Iritis

II Chronic Cyclitis :-

Chronic inflammation of ciliary body.

Diagnostic Points :-

1) Keratic precipitates on back of cornea,
2) Dust like opacities in the anterior vitreous
3) Atrophic changes (Heterochromia of Iris)
4) Considerable reduction of vision.
5) Other common symptoms of cyclitis

III) Purulent irido cyclitis :-

(Panophthalmitis)

It is a suppurative inflammation of anterior Uvea, vitreous and Retina, If the irido cyclitis is not controlled properly or if the infection is virulent, the purulent infection gradually extends to the posterior segment and causes panophthalmitis

Clinical features

Fever, headache, pain, redness in the eye ball, marked reduction of vision, swelling of eye lids, ciliary and conjunctival congestion, cloudy cornea, Hypopyon purulent vitreous (Yellow reflex at pupil on oblique illumination) constricted pupil with sluggished reaction, inflammed Tenons capsule, Finally ends with phthisisbulbi. Evisceration operation should do in time.

IV) Sympathetic ophthalmitis:-

It is a serious condition characterised by plastic inflammation of Uveal tract in one eye due to the effect of a similar inflammation in the other, following a penetrating injury.

CHOROIDITIS - (POSTERIOR UVEITIS)

The inflammation of the choroid is known as choroiditis. in most cases retina affects secondarily and the anterior part of the Uveal tract may be concomitantly affected.

Signs & Symptoms ;-

a) Visual disturbances (Floating specks may appear, defective visual acuity, distortion of objects (meta-morphopsia) objects may appear smaller (Micropsia), objects may appear bigger (macropsia), Flashes, sparks, bright circles may appear due to stimulation of sensory cells of retina (photopsia), defective field of vision and central vision)

b) On ophtholmoscopic examination retina shows patches of inflammatory exudates derived from choroid.

c) Vitireous opacities appear due to collection of inflammatory exudates. Destruction of nerve cells of retina in various parts depending upon the type of infection and vurulence of the organism.

Complications

1) Complicated cataract
2) Optic neuritis & atrophy
3) Degeneration of visual field.

Types of Choroiditis :-

1) Suppurative choroiditis - The whole choroid and retina are inflammed and ultimately leading to panophthalmitis.

2)Non suppurative Choroiditis - Isolated foci of inflammation scattered over the fundus.

3) Disseminated choroiditis - Inflammatory patches in the fundus with healthy area in between.

4) Anterior choroiditis - Anterior part of choroid afftects, it commonly associate with interstitial Keratitis.

5) Central choroiditis - Central part of choroid affects.

6) Juxta papillary choroiditis - Choroid nearer to optic disc affects with defect in the field of vision

7) Diffuse choroiditis - Greater part of fundus is affected by gradual spread.

8) Toxoplasmosis uveitis - Caused by Toxoplasma gondii, transfered from mother to child in utero - the characteristic uveal lesion is a Circum scribed inflammation of choroid at Posterior pole

9) Toxocara canis uveitis - It is caused by the larvae of a nematode called Toxocara canis which Lives in cats and dogs. it causes white granulomatos lesion in choroid.

10) Tuberculous Posterior Uveitis- produces tubercles in the choroid near posterior pole.

11) Syphilitic posterior Uveitis, occur in congenital or acquired syphilis.

12) Sympathetic ophthalmitis- is a plastic inflammation of the Uveal tract in one eye following a similar inflammation in the other

13) Panophthalmitis - It is an intense purulent inflammation of the entire Uveal tract(Polymorpho nuclear leucocytosis) which fills the eye ball with pus and ends in complete destruction of eye ball. Commonly associate with penetrating injury to cornea and removal of eye is invariably indicated.

14) Behcets syndrome:-Recurrent iritis with hypopyon and Ulcerative lesions of mouth and genitalia optic atrophy is common and prognosis is bad.

15) Stevens Johnson Syndrome:- It is characterised by skin rash, stomatitis, conjunctivitis, keratitis, corneal ulcer, Uveitis and panophthalmitis.

16) Vogt- Koyanagi syndrome - Uveitis associated with alopecia, vitiligo poliosis and hyperacousis

17) Harada's syndrome:- Uveitis with Retinal detachment

18) Heerfordt's disease:- Uveitis with enlargement of parotid glands and facial paralysis

19) Endophthalmitis :-Generalised inflammatory condition of Uveal tract with lymphocyes and the other tissue are secondarily affected. Retinal detachment and phthisis bulbi commonly follows.

20) Degenerative changes of choroid like choroidal sclerosis and senile macular degeneration etc also causes choroidal lesions

Common treatment principles of choriditis

1) Protection of eye from light with goggles
2) Atropine drops or ointment TID or QID
3) Sub conjunctival or Retrobulbar hydrocortisone injections
4) Systemic antibiotics
5) Antihistamine drugs
6) Systemic cortisones or hydrocortisones.
7) Control of specific infections
8) Rest
9) Analgesics and Anti inflammatories if needed
10) Surgical procedures if needed
11) For most of the chronic wide spreaded infections of choroid prognosis is very bad.

THE PUPILS

Pupil is the central perforation of Iris, it regulates the amount of light admitted to the interior of the eye. The average diameter is about 3 mm. it is controlled by sphincter pupillae (For constriction of pupil) and dilator pupillae (for the dilatation of pupil.)Examination of the size (3mm), shape (Circular), position (central), margins (regular) and pupillary reaction is very important for the diagnosis of the diseases.

A) Size of the pupil :-

Average size of pupil is between 2 to 5 mm in diameter and vary in size due to following factors

1) Infants and old - small pupil 2) Adolescents - Bigger pupil
3) Brown eyes smaller pupil than blue eyes.
4) During sleep first dilated then constricted
5) In Hypermetropia pupil is smaller than in myopia.

B) Shape of the pupil is normally circular But is lesions of central nervous system it may become oval or D shaped.

C) Position of Pupil - In normal it is central But may become eccentric in Flat sarcoma of Iris, synechia, cerebral diseases (neurosyphilis), and in congenital abnormalities.

d) Margins of Pupil -Normally pupillary margins are regular but may be irregular due to synechia, uveitis and neuro syphilis.

The following conditions may cause abnormality in the size shape and position of the pupils.

1) Congenital anisocoria (unequal size of pupils)
2) " coloboma of Iris (Gaping in Iris)
3) Artificial coloboma of Iris due to sugery for cataract, glaucoma and Iris prolapse. 4) Traumatic lesions.
5) Inflammatory lesions like uveitis synechia and due to corneal perforation etc.
6) Eccentric pupil due to flat sarcoma of Iris.
7) Iris atrophy due to increased intra ocualar pressure.

E) Pupillary reactions- 1) Reactions of the pupil to light

a) Direct light reflex - light should be focussed into one eye from the side by covering the other and pupillary constriction should be noted.

b) Consensual light reflex - Light should be focussed on one eye and pupil constriction should be noted in the other eye.

2) Reaction of the pupil to shade :-

Pupil will be dilated in the shade or dimillumination.

3) Convergence and divergence Reaction : - Pupil constricts when a person gazes at a near object and dilates when gazes at a distant object.

4) The Pupil reaction to painful stimuli (cilio spinal reflex):-

By Pricking the skin of neck or head the pupils dilate for a while.

F) Unilateral constriction of the Pupil :- Irritation of the parasympathetic nerve fibres of the 3rd cranial nerve which supplies the sphincter pupillae is the causative fator.

Ex. 1) unilateral cerebral irritation or.
2) Intra cranial lesion irritating 3rd cranial nerve at base of skull
3) Local use of miotics **ex** - pilocarpine, eserine drops.
4) Paralysis of sympathetic fibres which supply the dilator pupillae.

G) Unilateral dilatation of Pupil :- Stimulation of the sympathetic nerve fibres which supply the dilator pupillae

Ex. 1) Irritative lesion of ocular sympathetic 2) Due to cocaine.3) Paralysis of parasympathetic fibres of 3rd cranial nerve 4) Lesion of ciliary ganglion or peripheral nerve endings. **ex** - mydriatics .

H) Bilateral constriction of Pupil :- Effect of the drugs acting on pupillo constrictor centre of the brain. Ex. 1) opium, morphine, chloral hydrate. 2) pineal tumour 3) neuro syphilis.

I) Bilateral dilatation of Pupil :- it is due to peripheral neuritis

Ex: - 1) Dugs taken internally like, Belladonna, Hyoscine, strammonium
2) Complication of diphtheria 3) Anaemia 4) Thyrotoxicosis 5) Botulism 6) coma.

Mydriasis - Causing dilatation of pupil

Mydriatics - The medicines those cause pupil dilatation, these are used for examination of posterior compartment of eye ball, in the treatmet of Iritis Irido, cyclitis and corneal ulcer to prevent, synechia.

Ex. 1) Atropine solution or ointment 2) Scopolamine 3) Homatropine 4) Platyphy 5) Phenamine etc .

Note :- Mydriatics are contra indicated in glaucoma.

Miosis : - causing constriction of pupil

Miotics - The medicines those cause pupil constriction. These are used for the management of Glaucoma

ex 1) Pilocarpine solution or ointment 2) Eserine 3) furamon 4) Phosphacol

Corectopia - It is a congenital abnormality in which the pupil present not in the centre of Iris.

Anisocoria - Inequal size of pupils

Polycoria - Multiple pupils in Iris myotonic pupil or Adies pupil- Slow constriction and dilatation of pupil.

Occlusio Pupillae:- Pupillary area is filled with Organised exudates and causes difficulty in refraction and aqueous circulation.

Seclusio pupillae :- Adhesion of entire pupillary margin to the Lens capsule

Above 2 conditions causes glaucoma and Iris bombi due to obstructed aqueous circulation.

RETINA

A) Congenital and developmental defects of Retina

1) Coloboma of choroid and retina:- ophthalmoscopically a white area of exposed sclera can be detected as a congenital defect.

2) Opaque nerve fibres (or medullated nerve fibres):- As a developmental defect some times myelinated nerve fibres are also found. Ophthalmoscopically it appears as opaque white patches with a feathered edge at the margin of disc.

3) Albinism - Defective development of retinal choriodal pigments - causes photophobia, nystagmus and defective vision etc.

4) Aplasia - Hypoplasia of macula may occur congenitally and cause blindness.

5) Congenital pigmentation of the retina : small oval grey spots or groups of poly gonal black spots may present in retina due to the accumulation of retinal pigment epithelium, it doesn't cause any serious problems.

6) Colour blindness :- Total colour blindness - is rare, it is due to defective development of cones and some defects in higher cerebral centres.
Partial colour blindness - is relatively common and exact cause is obscure.

7) Retro lental fibroplasia (Retinopathy of prematurity)
It appears in the premature infants with the birth wight less than 1.5 kg.

The clinical features are 1) Grey appearance of peripheral retina 2) formation of Vasularised retro lental membrane 3) Retinal separation 4) shallow anterior chamber 5) peripheral anterior synechia 6) secondary glaucoma 7) Atrophic changes in the eye ball.

B) INJURIES OF THE RETINA

The injuries to the eye ball causes the following lesions .

1) **Contusion of Retina** Is caused by a severe blow on the eye ball, causes oedema of the retina at the posterior pole, with or without haemorrhages, the fluid exudes from capillaries and collect predominantly in the outer reticular layer of henle and in the rod and cone layer. The dimness of vision depends upon the intensity of lesion.

2) Retinal rupture - It occur in association with rupture of choroid.

3) Retinal haemorrhages occur with or without oedema .

4) Retinal separation - Due to injury, haemorrhage, exudates collection, give rise to separation of retina.

5) Solar Retinopathy:- Injury to retina due to Bright light exposure (eclipse blindness) causes blindness is known as solar retinopathy.

C) Retinitis :-

Inflammation of the retina is known as retinitis it usually associate with choroid (choroido retinitis) or optic nerve (neuro retinitis).

Pathological changes :- Congestion, Oedema, exudation of plasma and leucocytes, extravasation of blood in to the retina, choroido retinal atrophy and blindness.

Common Clinical features.

If macular region is involved causes.

1) Distortion of the shape of objects ex:- straight lines appear as wavy (metamorphopsia)
2) Objects appear smaller than normal (micropsia)
3) Objects appear bigger than normal (macropsia)
4) Impaired visual acuity 5) photo phobia.
6) If lesion present very peripheral, only blurring of vision present.
7) On ophthalmoscopic examination fundus shows slightly hazy retina haemorrhagic points, spots, exudations, pigmentary changes, blurred disc margins etc .are found

1) Purulent retinitis Or septic retinitis : -

Retina is infected with virulent pyogenic Organisms, the infection spreads from choroid, finally it may cause panophthalmitis or endophthamitis.

2)Cyto megalic inclusion disease.

Human cyto megalo virus infection is characterised by distended tissue in which nuclei contrain large acidophilic inclusion bodies. It causes macular lesion or exudative chorio retinitis.

3) Syphilitic Retinitis arises in association with Uveitis, in which diffuse retinitis, attenuated vessels depigmented retina and optic atrophy are present.

4) Massive exudative retinitis - Coats disease, It is a rare disease of the young which presents a large raised yellowish white area as the result of haemorrhage and exudate collections between the outer layers of retina. Vision get lost due to retinal separation and glaucoma

5) Sub acute infective Retinitis (Septic retinitis of Roth)

The characteristic feature is the presence of round or oval white spots (Roths spots) in the posterior part of fundus, commonly arises due to Bacterial endocarditis and puerperal septicaemia, vision mostly impaired and also causes death.

6) Vasculitis retinae

Exudations are seen around the vessels. inflammation of veins is knwon as Phlebitis in which veins become thickened congested and tortuous
Inflammation of the arteries is known as Arteritis.

7) Eales disease Or periphlebitis retinae : Profuse recurring haemorrhages into the vitreous

8) Retinitis proliferans :- The retinal haemorrhages organise and cause vitreal and Retinal bands or membranes that cause atrophic changes in retina.

9) Photo retinitis - Inflammation of retina due to bright light exposure.

10) Sarcoidosis (epitheloid granuloma) Clinical features - candle wax spots, whitish areas, Oedema of optic disc, optic atrophy, choreo retinitis, periphlebitis, etc. the disease occurs in association with posterior Uveitis.

11) Toxo plasmosis :- It is protozoan infection from cats,it causes chorio retinitis.

12) Toxo cara canis, toxocara cati and Ascaris lymbricoides etc round worms produce retinal lesions.

D) RetinoPathies:-

Retinopathies occur in association with some general diseases like hypertension diabetes nephritis toxaemias of pregnancy, arterio sclerosis etc. The retinal changes are probably caused by increased capillary permeability and degenerative changes in the retinal tissue from anoxaemia.

1) Hypertensive retinopathy:- It may occur in 4 types.

a) In simple hypertension without sclerosis seen in the young, the retinal signs are constriction of the arteries which appear to be pale with acult angled branching, while haemorrhages may occur but not exudates.

b) Hypertension with involutionary sclerosis, occuring in older patients, the picture of arterio sclerotic Retinopathy appears, vascular constricutions, dilatations, sheathing of vessels, deposition of hard exudates, haemorrhages without any oedema.

c) Arterio sclerosis in the young (Diffuse hyperplastic sclerosis) Hyper tension with glomerulo nephritis produces the ophthalmoscopic picture as, narrow and tortuous veins with nicking at arterio venous crossings, multiple haemorrhages, oedema cotton wool patches, hard exudates collection which scattered diffusely and produce macular star, vision is seriously impaired and causes death from uraemia.

d) malignant hypertension extreme attenuation of vessels, Entire retina may be clouded, generalised oedema, papilloedema, cotton wool patches, macular star and vision is gravely affected.

2) Retinopathy in toxaemias of pregnancy

It occurs in late months of pregnancy, it has many of the characteristics of hypertensive retinopathy, The features are narrowing of vessels, angiospasm, oedema, haemorrhages, profuse exudations and generalised to cause retinal detachment if Angiospasm weight gain present that indicates systemic retention of fluid, that may cause blindness and harm for the mother and child, hence termination of pregnancy is advised.

3) Lupus erythematosis retinopathy

If occurs in 10% patients, of Lupus erythematosis, in which cotton wool spots in posterior retina, flame shaped haemorrhages, and minor papilloedema, other symptoms are part of sjogren's syndrome (Kerato conjunctivitis,scleritis epi scleritis, Uveitis and butterfly skin eruptions)

4) Diabetic retinopathy

It usually occur in elderly persons with other features of diabetes, presence of dot (Punctate haemorrhages) or blot (larger haemorrhages) or clusters of grapes like haemorrhages, development of micro aneurysms due to degeneration of vessel wall, hard white yellow waxy exudative patches at posterior pole, Oedema is not marked, Arterio sclerosis hypertension and renal disease are often superimposed upon the diabetic fundus, finally it causes retinitis proliferans, retinal detachment and blindness..

5) Proliferative or Neovascular Retinopathy

Progressive obliteration of the pre capillary arterioles results in focal areas of retinal anoxia followed by a neo vascularisation These new formed vessels originally within the retina but break in to vitreous where they are responsible for recurrent vitreous haemorrhages, finally Organisation of vitreous and retinal separation occurs.

6) Renal retinopathy

It is found commonly in chronic glomerulo nephritis with hypertension. signs of advanced arterio sclerosis are found in retinal arteries, other signs are oedematous fundus, blurred disc margins, flame shaped haemorrhages, soft cotton wool patches of exudates, macula star and hyaline, lipoid exudative deposits appear in later stages, It occurs Bilaterally and causes blindness.

7) Arterio Sclerotic retinopathy

Sclerosis of the retinal arteries is due to high blood pressare and usually seen in elderly persons.

Changes in the vessels of retina-

1) Tortuosity of the small arteries especially at macula
2) alterations in the size breadth of the areterial lumen.
3) The vein is concealed at the crossing by the sclerosed artery.
4) The vein is compressed at the crossing by the sclerosed artery so that the peripheral portion of the vein is dilated while the central portion remain normal

5) Copper wire arteries - owing to the thickening of the arterial wall by the sclerosis , light is reflected back from its wall giving a coppery appearance
6) In more advanced sclerosis, light is reflected back from arterial wall giving a silvery appearance (Silver wire arteries)
7) minute miliary aneurisms are some times seen.
8) Flame shaped haemorrhages along the vesels 9) White solid exudates usually found in the posterior part of fundus.
10) No Oedema of retina or disc.

Complications:-

a) Amaurosis fugax - blurring of vision due to retinal arterial spasm
b) If arterio sclerosis is neglected, leads to retino pathy (with haemorrhagic exudates)
c) Thrombosis of retinal vein
d) Optic atrophy.

E) Neoplasm of Retina

1) Primary Neoplasms :-

Retino blastoma or Glioma of the retina or neuro epithelioma of retina :-
This is a malignant growth, congenital in origin occurs in children under 5 years of age. The tumour is composed of small round densely packed cells with largenuclei arranged around the vessels. It rapidly spreads in the eye ball and cauces retinal detachment, vitreal degeneration enlargement of eye ball and the infection also spread in to cranial cavity along the optic nerve.

Symptoms :- Yellowish white reflex at pupil, pain in later stages, dimvision, secondary squint, enlargement of eye ball etc.

Signs - Ist stage

Yellowish white plaques either covered by retina or vitreous or blood vessels or haemorrhagic exudates are seen with ophthamoscopic examination. (Amaurotic cats eye)

2nd stage :- wide spread of tumour in the eye ball and development of glaucoma is seen.

3rd stage : - extra ocular stage or stage of metastasis, eye ball is enlarged, pushed forwards and retro ocular extention of the infection through optic nerve (Involves all the tissue which it comes in contact

Treatment : - Enucleation of the eye ball should be undler taken as quick as possible, if not it causes death.

2) Secondary Neoplasms :-

Secondary neoplasms of retina occurs by the invasion of primary and secondary choroidal neoplasms

3) Retinoschisis
Splitting of the retina at the level of outer plexiform layer (smooth sharply demarcated detachment) due to retinal cysts.

F) VASCULAR DISORDERS OF RETINA

1) Retinal arterial hyperaemia - is caused by inflammatory lesions of the retina choroid, characterised by fullness and tortuosity of the arteries.

2) Retinal venous hyperaemia : - It is caused by congenital heart disease heart failure, increased intra orbital pressure, increased intra cranial pressure thrombosis of central retinal vein etc. The venous hyperaemia is characterised by dilatation and tortuosity of the veins.

3) Anaemia of Retina :- If is due to Thrombos is of central retinal artery, spasm of the retinal arteries, compression due to sudden rise of intra ocular pressure, cardiacfailure, profuse loss of blood, and in quinine amblyopia.

Clinical features:- are pallor disc, narrowing of retinal arteries, loss of vision etc.

4) Retinal haemorrhages :- The causes are a) Injuries b) lesions of retinal and choroidal vessles c) diseased blood vessels (Atheroma) commonly associate with heart and kedney diseases and in the old people. d) Circulatory problems, e) changes in the composition of vessel wall and blood f) Valvular heart disease and cardiac hypertrophy g) Loss of blood etc.

Signs symptoms :-
1) pre retinal haemorrhages (Sub hyloid haemorrhages) - the bleeding occupies between internal limiting membrane and vitreous, the haemorrhage occupies a circular shape but later spreads horizontally, occur at macular region.

2) Intra retinal haemorrhage
a) Superficial type (it occur in nerve fibre layers.)
b) deep type (it occur in nuclear layers)

The interference with vision depends upon the size and location of the haemorrhage. Minute haemorrhages are absorbed without any traces, bigger haemorrhages causes lesions and visual disturbances.

5) Oedéma of retina :- This may be diffuse or localised, the retina appears pale cloudy instead of bright red appearance. Oedema tends to throw the retina into radiating folds. (Star shaped folds)

6) Macular Oedema : -
Extra cellular fluid may accumulate in the foveal region by leakage from the local capillaries. it is of 2 types.
a) Cystoid oedema (simple, without foveal structural alteration)
b) Non cystoid or amorphous Oedema, when the normal capillary architecture at the macula has become destorted.
7) Central serous retinopathy - Circular dark raised swelling of macula, caused by exudation from the para foveal or choroded capillaries, impairs the central vision upto some extent.
8) Exudative retinopathy of coats (explained in Retinitis)
9) Proliferative retinopathy (or reinitis proliferans) explained in Retinitis
10) Retro lental fibroplasia (Explained in congenital developmental abnormalities.)

G) RETINAL CHANGES IN THE DISEASES OF BLOOD

Retinal haemorrhages occur in blood diseases due to capillary permeability because of deficient oxygenation.

1) Anaemia :- In severe anaemias the veins are frequently engorged and in the posterior half of retina haemorrhages appear which are in flameshape, occationally are associated with soft exudates and fundus appears pale
2) Sickle cell haemoglobin peripheral arterioler occlusion are common in the retina and retinitis proliferans develop.

3) Plycythaemia :- In more severe cases marked venous engorgement, cyanosis of veins, Oedema of the disc and retinal haemorrhages occur.

4) Leucaemia : - Engorged and tortuous veins, round and flame shaped haemorrhages, soft exudates, fundus is pale or orenge coloured, oedema of retina and optic disc etc occurs due to capillary anoxia.

5) Occlusion of central retinal artery. The site of obstruction is just behind the lamina cribrosa where there is normally narrow vessel. The obstruction commonly occur due to thrombus embolus and arterio spasm of peripheral vessels.

Clinical features :-
1) Sudden complete loss of vision
2) Pupil widely dilated and no reaction to light .
3) Retina be comes milky white
4) Macula pink (cherry red spot)
5) Vessels are thin attenuated.
6) Thrombosis of Retinal vein,:- It usually occur in elderly arterio sclerosis person and involves either central retinal vein or one of its tributaries. If central vein Obstructs that is just behind lamina cribrosa and tributaries obstruct at arterio venous crossings.

Thrombosis causes venous engorgement with dilated and tortuous veins, fundus is scattered with haemorrhages. vision greately reduces if macular area affected and within few weeks causes atrophic retinae with fine pigmentary chonges.

H. DEGENERATIVE CONDITIONS OF RETINA

1) Senile macular degeneration (Hereditory) It occurs in the aged persons.

2) Circinate retinopathy .
It is due to chronic oedema involving a considerable area of the retina at and around the macula, as a part of hypertensive or diabetic retinopathy .

3) Benign peripheral retinal degeneration.

There are a number of retinal degenerations which do not-threaten the retina, even seen in many normal eyes

Ex. 1) Snow flakes (dotted white appearance at ora serrata)
2) Paving stone degeneration (Due to chorio retinal atrophy)
3) Reticular pigmentary degeneration
4) Equatorial drysen, commonly found in elders with peripheral cystoid degeneration.

4) Angioid streaks:-
Dark browny pigmented streaks which anastomose with each other and may be mistaken for blood vessels, situated near the optic disc at a deeper level than the retinal vessels, these are due to changes in the elastic tissue of Bruch's membrane, paget's disease of bone, Ehlers Danlos syndrome and sickle cell disease may be associated with angioid streaks.

5) Pigmentary retinal dystrophy (Retinitis pigmentosa)
It is a congenital and familial disease characterised by night blindness and ultimately causing total blindness. the exact aetiology is obscure.

a) Small jet black pigments start in the equatorial region then gradually spreads centrally and peripherally and resembles bone corpusles b) Attenuation of retinal vessels c) degeneration of rods. d) field of vision show concentric contraction e) Ring scotoma is found in corresponding with the degenerated zone of retina. f) As the case progresses the field becomes smaller and at last reduced to restricted area around the fixation point, eventhough the central vision retained for a long time. g) Disc atrophies and appears in waxy yellow colour, Optic atrophy sets in and gradually increases h) In the later stages cataract develops i) Ultimately it causes total blindness.

I) DETACHMENT OF RETINA OR RETINAL SEPARATION.

Retina is separated from underlying choroid eithr by fluids or solids. Retina mostly depends on choroid for its nutrition, if it is separated from choroid it may under go degenerative changes.

1) Primary detachment of retina, the cause is not obvious, usually associated with a tear or hole in the retina, This is commonly found in a) old persons with peripheral choroideo retinitis b) High myopia c) Contusion injury to the eye ball

2) Secondary datachment of retina the cause is obvious, they are a)Intra ocular tumours b) Exudative choroiditis c) Fibrous tissue formation in vitreous d) Haemorrhage between choroid and retina.

Clinical features :-
1) Vision gradually reduces and may become blind 2) Appearance of shades in visual fields when gazing in a fixed direction and retinal tear can be identified in ophthalmoscopic examination.

Treatment 1) Cause should be treated 2) Surgical correction (Diathermy coagulation to drain the sub retinal fluids to produce adhesion between choroid and Retina.

DISEASES OF THE OPTIC NERVE

The optic nerve is the second cranial nerve meant for visual perception. it is a tract formed by the ganglian cells of retina. it comes out from eye ball by piercing the sclera at Lamina cribrosa a little distance to the posterior pole of eye ball. it enters the cranial cavity through optic foramina and ends at Lateral geniculate body, from here optic radiations reaches the visual cortex of occipital lobe of cerebrum for visual perception and discrimination.

Optic nerve may be divided into,
1) Intra ocular portion (in eye ball)
2) Orbital portion (eye ball to optic canal)
3) Intra canalicular portion (in optic canal)
4) Intra cranial portion (in cranial cavity)

The optic disc is known as head of the optic nerve present a little inside to the posterior pole where all the ganglian cells are united to form optic nerve. there is a funnel shaped central small depression known as physiological cup. Optic disc is cirular but some times oval, light pink in colour and much lighter than the rest of fundus. The margins often present 2 rings an inner scleral and outer choroidal, the central artery and vein of the optic nerve pass along the inner wall of the disc.

A) Congenital Abnormalities of optic disc

1) Coloboma of optic disc (partial formation of the optic disc

B) Inflammatory conditions :- 1) Inflammation of optic nerve is known as optic neuritis 2) inflammation of optic nerve head is knownas papillitis 3) Inflammation of orbital part ofoptic nerve is knwon as retro bulbar optic neuritis

I) Papillitis (Intra ocular optic neuritis)	II) Papilloedema (Pierocephalic oedema or chocked disc)
1) Inflammation of the optic nerve head, The cause is obscure, But may arise due to general debility septic focus etc.	1) Non inflammatory oedema of optic disc, commonly due to raised intra cranial pressure, orbital tumour, abscess, Hypertention, nephritis and leukaemias etc
2) Disc is hyperaemic with blurred margins and the disc swelling rarely more than 2 Dioptres	2) Disc margins are blurred and the disc swelling is frequently high (6 to 10 Dioptres)
3) Venous engorgement and haemorrhages less marked	3) Venous congestionand haemorrhages are marked (macular star)
4) Loss of sight is sudden and profound	4) loss of vision is gradual and negligible
5) usually unilateral	5) usually bilateral
6) condition is temporary and recovers in 2-3 weeks. If condition is severe disc becomes pallor due to optic atrophy.	6) Condition is progressive if not treated in time and causes blindness due to optic atrophy
7) Central scotoma for red and green objects.	7) Gradual concentric contraction of the fields.
8) Treating the aetiology septic focus; B. complex and cortisione therapy may be benificial	8) Cause should be treated, B Complex therapy cortisone therapy may be benificial.

III) Retrobulbar optic neuritis :-

Inflammation of the orbital part of the optic nerve is known as retro bulbar optic neuritis.

1) Acute stage :- It is due to disseminated sclerosis, Neuromyelitis optica, infection from sphenoid and ethmoid cells, lead and methyl alcohal poisoning.

Signs and symptoms :- Pain with movement of eye ball, especially in upward direction, sudden profound loss of vision, hyperaemia and blurring of disc margin, scotometry shows central or pericentral scotoma - especially for red and green objects.

2) Chronic stage or Toxic amblyopia :- It is due to toxic effect of Tobacco, quinine Arsenic ethylalcohol etc. causes Bilateral gradual blurring of vision, vision is normal but misty, fundus is normal and with centro caecal or central scotoma.
Treatment :- Stoppage of consumption of tobacco alcohol etc and administriation of B12 - B Complex etc.

IV) Optic atrophy

Atrophy of the optic nerve is called optic atrophy

1) Consecutive atrophy :- It occurs in association with certain diseases of retina
eg :- Diffuse chorio retinitis, retinitis pigmentosa, etc (Here ganglian cells undergo degeneration.)

2) Secondary atrophy ;-
It occurs as the complication of the papillitis - papilloedema etc. diseases.

Signs & symptoms : -
The colour of the optic disc dull white, margins blurred, physiological cup filled up with glial tissue, and blood vessels show pathological changes like narrowing sheathing etc.

3) Primary optic atrophy :- It occurs without obvious lesion of fundus. But observed mostly due to syphilitiic affection, disseminated sclerosis, pressure on the optic nerve, haemorrhage in optic nerve sheath, massive haemorrhagic disorders, Arsenic poisoning, cranial stenosis, Toxic amblyopias, malnutrition etc.

Signs & Symptoms : -
The optic disc is bluish white in colour, enlarged physiolgical cup, clear margins and no vessel chunges.

Treatment 1) Cause should be treated 2) Stopage of toxic things like Tobacco methyl alchohol etc.3) B1, B6, B12 administration etc.
Tumours of optic nerve :- Rare but some times the following malignant tumours arise 1) Glioma it it arises in optic nerve fibres 2) meningioma it arises in the endothelial cells of meningeal sheath of optic nerve. These 2 should be excised)

AQUEOUS HUMOUR

It is a clear watery fluid occupying the anterior and posterior chambers of the eye ball. it is not a stagnated fluid but continuously secreted by ciliary process of ciliary body and passed over the Lens, through pupil enters into the Anterior chamber and then drained into vascular system

Reaction - AlK aline (PH 7.1 to 7.3) specific gravity - 1.002 to 1.004
Viscosity - 1.029., Refractive index - 1.34

Composition :-
Water 98. 69 %, Solids 1.3% (It closely resembles cerebrospinal fluid)

Functions:-

1) Maintains intraocular pressure (18 t0 23 mm Hg in schiotz tonometer)
2) Gives shape for the eye ball
3) Act as a refractive media
4) Supplies nutrition and drains the metabolites from the surrounding structures.

Aqueous affection

1) Increased intraocular pressure of eye ball is due to stagnation of aqueous flow or increased aqueous secretion.
2) Severe aqueous leakage causes lowered intra ocular pressure, causes shrinkage of eye ball (phthisis bulbi)
3) Aqueous is a transparent water like structure, acts as a refractive media but if it is polluted with inflammatory precipitations, vision is obliterated (Interstitial keratitis, corneal ulcer, corneal perforations, uveitis and due to post operative lesions).
4) Collection of pus in the anterior chamber (Aqueous) is known as hypopyon
5) Collection of blood in the anterior chamber is known as hyphaema
6) collection of macroscopic deposits in the lower part of cornea due to uveitis, the precipitations floats in the aqueous known as keratic precipitates.

Vitreous humour :-

It is a transparent colourless jelly like substance fills the posterior compartment of eye ball behind the lens. It is separated from Lens by a retrolental space. its outer surface presents a thin condensation of its structure known as hyaloid membrane, vitreous is traversed by a canal from optic disc to posterior capsule of lens known as hyaloid canal, It has no blood supply but receives nourishment from surrounding tissue, It is incapable for inflammatory changes, but degenerative changes only occur .

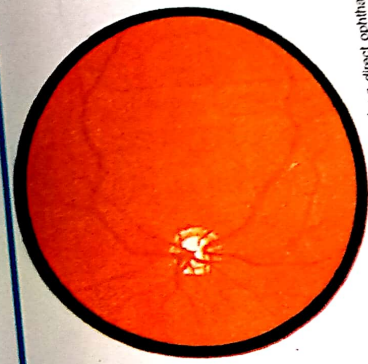

Fig. 1 Normal fundus of the left eye as seen by a direct ophthalmoscope. The oval area on the nasal side is the optic disc. The tiny circular area at the temporal side of the disc is the fovea. The oval area on the temporal side of the disc is the fovea about 21/2 disc diameters on the retinal veins and the narrower contralis. The wider and darker vessels are the retinal arteries (Magnification about 15 times)



Fig. 2
Medullated or opaque nerve fibres in the retina

C. Primary optic atrophy

B. Coloboma of the optic disc

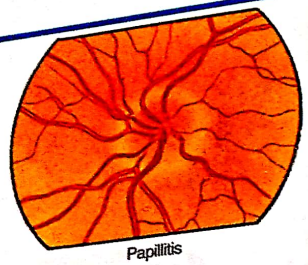

Papillitis

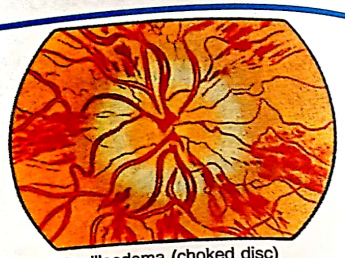

Papilloedema (choked disc)

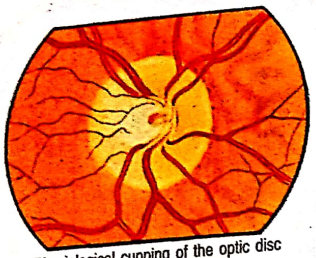

Physiological cupping of the optic disc

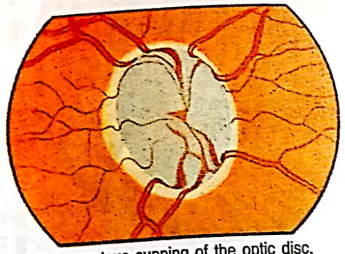

Glaucomatous cupping of the optic disc.



Fig. 2
Retinitis pigmentosa with bone corpuscle formation, attenuated retinal alterioles and a yellowish disc (Parsons)

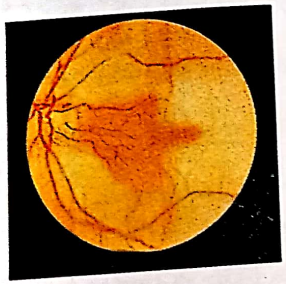

Fig. 1
Dental retinal artery occlusion with a cherry red spot and sparing of a temporal cilio-retinal vessel.

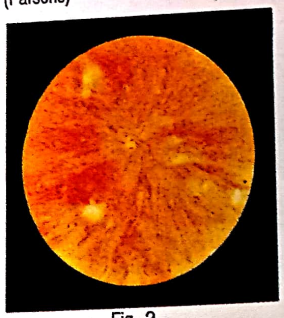

Fig. 2
Central retinal vein thrombosis (Parsons)

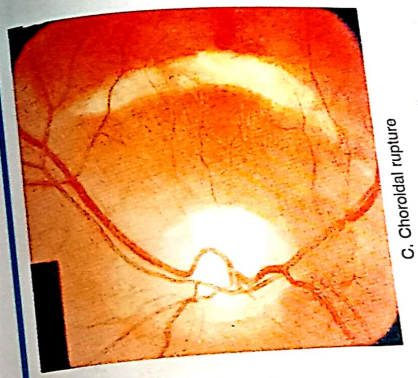

C. Choroidal rupture

Disseminated Choroiditis

Fig. 2
Chronic Cyclitis
(Parsons)

C. Posterior synechiae



Fig. 1
Plastic iritis with
posterior synechia

C. Posterior synechiae

Fig. 4
Corneal Nebulae

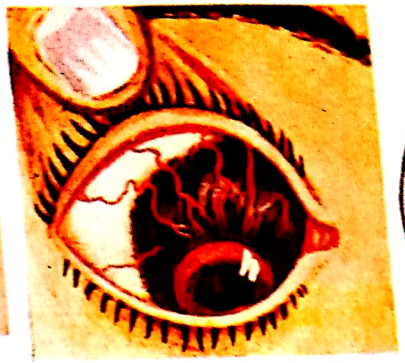

Fig. 3
Ciliary Staphyloma

Interstitial Keratitis (Parsons)

Hypopyon ulcer

Dendritic ulcer

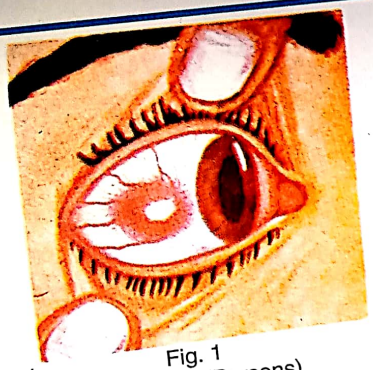

Fig. 1
Episcleritis (Parsons)

Fig. 2
Scleritis (Parsons)

Fig. 1
Conjunctival type of congestion
(May and Worth)

Fig. 2
Circumcorneal or ciliary congestion
(May and Worth)

Fig. 4
Subconjunctival Haemorrhage
(May and Worth)

Fig. 2
Trachoma, Follicular Stage
(Parsons)

Fig. 3
Trachoma, cicatricial Stage
(Parsons)

Fig. 1
Trachomatous Pannus
(Parsons)

Fig. 1
Chronic Dacryocystitic
with Mucocele of the
lacrimal Sac.



Fig. 4
Ectropion

Fig. 2
Acute Dacryoystitis

Fig. 3
Blepharitis

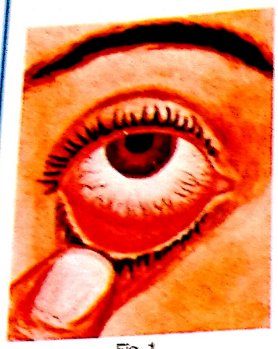

Fig. 1
Acute muco-purulent conjunctivitis
(Parsons)

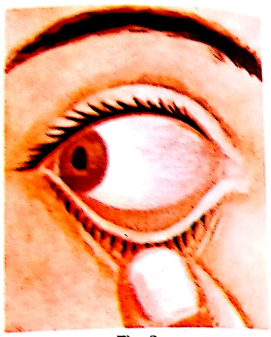

Fig. 2
Angular conjunctivitis
(Parsons)



Fig. 3
Folicular conjunctivitis
(Parsons)

Fig. 4
Phlyctenular conjunctivitis
(Parsons)

Congenital defects :- 1) Persistent remains of the hyaloid artery :- usually hyaloid artery disappears before the delivary it self but some times the remnants attached to the posterior pole of lens casule which appears as a small blackish dot when viewed with the ophthalmoscope.

2) Peripheral inflammatory lesions, Neoplasms may produce opacities haemorrhages, degenerative chages in the vitreous that may cause considerable visual defect.

3) Fluidity of vitreous (Synchisis) :- Fluidity of vitreous due to alteration of the consistency of the vitreous due to opacities, high myopia, old age and peripheral inflammatory conditions the patient feels moving spots in the field of vision and finally it may cause retinal separation due to increased pressure.

4) Shrinkage of Vitreous :- It occurs due to age (Senile degenerative changes) vitreous detached posterioly, due to adhesions, retinal separation also occurs. Patient complains of floating spots and flashes of light in visua field.

5) Muscae Volitantes :- Thses are fine translucent dots or filaments only seen subjectively especially when they are viewed against a brightly illuminated background. there is no pathological significance but a sensitive myopic patient may fear.

Treatment :- No effective treatment is known except correction of the refractive errors.

6) Opacities of vitreous :- These occur in the vitreous due to inflammatory changes and haemorrhages of peripheral structures.

a) Protein coagula of the vitreous:- These dot like opacities visible due to liquefaction of vitreous .

b) Asteroid hyalitis :- Numerous white particles resembling snow flakes appear in vitreous even in the normal, the disease dosesnot cause any visual defect and the exact cause also obscure.

c) Synchisis scintillans :- Numerous shining crystalline bodies (cholesterol crystals) are seen in fluid vitreous the crystals churned up with eye ball movement. It is due to long standing Uveitis. It rarely produce symptoms and no effective treatment is known

d) Degenerative changes of vitreous due to high myopia.

e) Exudes from Uveitis cause diffuse clouding in vitreous .

f) Blood from the retinal vessels may invade the vitreous and cause opacities.

g) Extensive membrane formation, organisation of exudates or haemorrhages(Retinitis proliferans) may cause vitreous opacities.

Signs - Symptoms ;- Some degree of visual disturbance discomort from floating specks, visual acuity is not greatcly impaired.

Prognosis - Mostly opacities are absorbed and residual opacities remain without much problem.

Treatment
1) Peripheral lesions should be treated.
2) Supplementation of vitamin C-K P
3) Potassium lodide by mouth, diaphoretics, cathartics and sub conjunctival saliva injections may benifit to the patient.

7) Vitreous haemorrhages :- Blood in Vitreous is always derived from the retinal vessels and vessels of Uveal tract as the vitreous humour has no blood vessels in post natal life.

The causative factors are injuries, Arterio sclerosis, Hypertenisve and diabetic retino pathy, high myopia, sequela to surgical procedures, Eales disease etc.

If the haemorrhage is minor doesn't Obstruct the vision and it may be absorbed but wide spread haemorrhages cause visual loss and prognosis also bad.

Treatment -
1) Cause should be treated
2) It can be tried like vitreous opacities.
3) Not Satisfactory.

8) Vitreous abscess : -
It arises due to perforation of cornea or penetrating injury to eye ball or endogenous infection (endophthalmities) etc.

Sign: A yellow reflex at pupil in oblique illumination
Treatment ;- Evisceration of the eye ball.

ERRORS OF REFRACTION

Refraction :- The method by which the light rays after travelling through the refractive media falling on retina (fovea centralis) for visual perception is known as refraction

Refractive media : - Cornea, aqueous humour, pupil, Aqeous, Lens, vitreous humour and retina

Emmetropia - It is a normal refractive condition of the eye in which the parallel light rays from a distant object are brought to foccus on retina with the accommodation at rest.

Ametropia :- it is an abnormal refractive condition of the eye in which the parallel rays from a distant object are brought to foccus either before or beyond the retina, is known as Ametropia (Refractive errors)

1) Myopia (short sighted) it is a refractive error of the eye in which, with the accommodation at rest, the parallel rays from a distance object are brought to foccus in front of the retina

2) Hyper metropia (Long sighted) It is a refractive error of the eye in which, with the accommodation at rest, the parallel rays from a distance object, are brought to focus beyond the retina.

3) Astigmatism It is the refractive condition of the eye in which the refraction differs in different meridians of the eye (Ex:- Normal in one meridian and myopic or hypermetropic in another meridian)

4)Aniso metropia it is the condition in which there is considerable inequality in the refraction of the two eyes.

EX:-
1) Uni ocular trauma (one eye is normal another is affected)
2) Uni ocular Extraction of lens in cataract (3) High myopia etc
4) Congenital causes

Note :- If the difference in refraction is more than 2.5-D in the two eyes Causes difficulty for binocular vision Because it produces 5% difference in the size of retinal image.

MYOPIA (SHORT SIGHTED)

Defination:- It is the refractive condition of the eye in which with the accommodation at rest, the parallel light rays from a distant object are brought to foccus before the retina in stead of on fovea centralis of macula of retina, is known as myopia or short sighted or Hraswa drusti. In myopia the patient cannot see the distant objects properly (difficulty in distant vision)

Causes:- (1) congenital or developmental or Heriditory (2) increased antero posterior axis of the eye is the commonest cause which is known as Axial myopia (3) Increased refractive inde of the refractive media will converge the rays so only brought to be focussed before the retina like in lental sclerosis, is known as Index myopia .(4) when the curvature of cornea is greater then normal causes curvature myopia (5) The position of the lens moving fowards or increased convexity produces myopia .



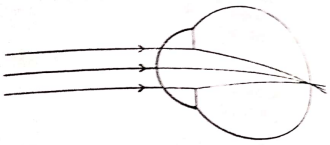

Emmetropia, hypermetropia and myopia. In emmetropia (E), parallel rays of light are focused upon the retina. In hypermetropia (H), the eye is relatively too short; in myopia (M), it is too long



Myopia

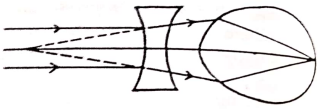

Correction of myopia with concave spherical lens

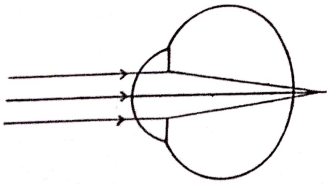

Hyper Metropia

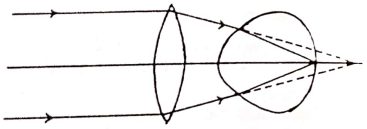

Crrection of hypermetropia with convex spherical lens

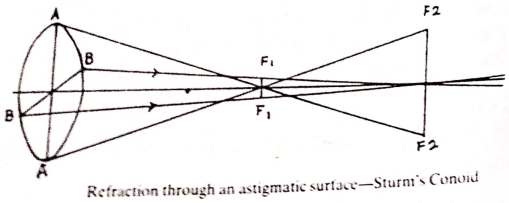

Refraction through an astigmatic surface—Sturm's Conoid

Clinical types of myopia :-

1) Congenital Myopia -
Some times high Anisometropia (one eye is normal and other eye is high myopia) is seen congenitally and Bilateral congenital myopia commonly associate with convergent squint ingeneral congenital myopia associate with cataract, microphthalmos, Lenticonus, aniridia, megalocornea, retinal separation etc. disorders.

2) Developmental myopia or simple myopia -
It is a safe variety without degenerative changes, mypoia may tatain maximum 5 to 6 D. A Child is born as hyper metropic but at the age of 4 yrs it will become emmetropic due to normal development of body But in some conditions the eye maybecome myopic due to accelaration of the maturity (long eye), It is said to be nonpathological or Non progressive mypoia, commonly observed in school going age group.

3) Degenerative or progressive or pathological myopia-
It is a complicated myopia due to degenerative changes in the eye ball, the refractive error may reach even more than 20 D. The associated complications are. a) Reduction of Vision b) Ectasia of posterior segment of eye with thinning of sclera c) curvature anomalies of Lens and cornea d) Chorio retinal degeneration e) Retinal detachment f) Vitreous degeneration g) Posterior cortical or nuclear cataract h) Retinal haemorrhages i) Large myopic disc with temporal crescent j) optic atrophy.

4) Acquired myopia -
Myopia may also develop due to injuries after glaucoma operation, interstitial keratitis and due to drugs like steroids sulfonamides etc.

Signs and symptoms of myopia -

1) Dimness of vision for distant objects
2) There is no difficulty for near vision unless the defect is too high (Getting head ache while reading writting etc.)
3) In case of High myopia due to affection of near vision the Child holds the book very close to his eyes while reading.
4) If the error is uncorrected the pathological mypoia may cause blind ness.

Treatment :-

1) Nutritious food or vitamines supplementation.
2) Prescribing of concave Lens (-) of proper strength or contact Lens.
3) Symptomatic therapy for complications
4) Hygienic measures
5) Eye exercises etc.

II) Hyper metropia -

Defination:- It is the refractive error of the eye in which with the accommodation at rest, the paralel rays from a distant object are brought to foccus beyond the retina, instead of on fovea of macula of retina.In hyper metropia the patient complaints of dim vision for near things.

Causes - 1) Shortness of the eye ball in the antero posterior axis, this is the commonest cause due to underdevelopment of eye during child hood., is known as Axial hypermetropia.

2) Refractive index of the refractive media (mainly lens) may be low, This type is known as Index hypermetropia.

3) If the curvature of the cornea is less than normal (flat), is called curvature hypermetropia.

Clinical types of Hyper metropia :-

1) congenital hypermetropia. This is uncommon and assoicate with other Abnormatlities like microphthalmos.

2) Developmental hypermetropia:- Most of normal infants are born with + 4 D hypermetropia, it should be corrected physiologically upto 4 yrs. of age but due to delayed development the hypermetropia continued ,this is known as developmental hypermetropia.

3) Acquired hypermetropia

It is due to removal of crystalline Lens on account of cataract surgery (Aphakia), shortening of eye's length following scleral resection operation, partial dislocation of Lens posteriorly can also cause this condition.

Signs and sympotms:-

1) If there is moderate hypermetropia the Patient complains of dimvision only for near objects.

2) If there is high degree of hypermetropia the patient complains of dim vision for both near and distant objects.

3) If hypermetropia is minimal there are no visual symptoms, as the error is corrected by prolonged contraction of ciliary muscles which causes fatigue of muscles and produces eye strain or asthenopia (eye strain, head ache blurring of vision, pain in the eye, red ness and heaviness of lids)

Treatment :-

1) hygienic measures 2) eye exercises 3) prescribing of proper power convex Lens (+) 4) Symptomatic treatment of complications.

III) Astigmatism : -

It is the refractive condition of the eye in which the refraction differs in different meridians of the eye.

Ex - In the horizontal meridian the eye is emmetropic but in vertical meridiian It is hyper metropic or mypoic.

Causes :- 1) variation in the curvature of cornea - lens or both.

2) Partial dislocation of Lens

Types :-

1) Regular astigmatism (simple, compound and mixed) 2) Irregular astigmatism.

1) Irregular astigmatism :-. Here the light rays are refracted very irregularly (Different groups of foci in various positions) due to corneal ulcers, keratitis, penetrating injuries, surgical lesions, kerato conus etc.

Correction :-

1) spectacle lenses are not useful.
2) Contact lenses are useful upto some extent
3) Keratoplasty is advisable.

2) Regular astigmatism : - Light rays are not focussed at a single point but here the meridians of greatest and least refraction are at right angled to each other (Light rays are not regular totally in all meridians but regular in each meridian that is right angled to each) It is due to corneal curvature irregularities and subluxation of Lens.

It is of 3 types

1) simple astigmatism 2) compound astigmatism. 3) Mixed astigmatism.

1) Simple regular astigmatism :-

one meridian is emmetropic and the other either myopic or hypermetropic it is again 2 types a) simple myopic regular astigmatism b) simple hypermetropic regular astigmatism.

2) Compound regular astigmatism :- The Both meridians are Ametropic. either myopic or hypermetropic so it is again two types a) Compound myopic regular astigmatism (the two focal lines fall before the retina. b) Compound hypermetropic regular astigmatism (the two focal lines fall beyond the retina).

3) Mixed regular astigmatism Both the focal lines are ametropic among them one is myopic (focal line fall before the retina) another is hyper metropic (focal line fall beyond the retina).

Signs and sympotms - With a small degree of astigmatism there may not be any visual disability but with greater degree distant and near visual disturbances and Asthenopia develops (Red eyes, headache, eye strain and pain while reading etc.) for especially near works.

Treatment :- Regular astigmatism is corrected with cylindrical Lens of proper strength (in simple astigmatism only with cylindrical Lenses and in compound and mixed astigmatism correction with cylindrical and sperical lenses.)

IV) Presbyopia :-

This is a physiological phenomenon which affects every eye usually after the ageof 40 yrs, in which the near point of distinct vision receedes beyond the distance at which we are accustomed to read ordinary print (Beyond 28 cm from the eye).

It is physiolgical process in which the crystalline Lens undergo gradual loss of plasticity and weakness of ciliary muscle so only the Lens lost the capacity to accommodate the near point from 28 cm after the age of 40 yrs.

Symtoms : -1) Difficulty in doing near works like reading writting sewing composing etc, As the age advances the difficulty increases more and more.

Treatment : - 1) age Prescribing the convex Lens of proper strenght
2) Rough calculation of strength of Lens as per age, is as follows.

S.No	Age	Strength of Lens.
1	40 yrs to 45	+ 1. Dioptres
2.	45 " to 50	+ 1.5. "
3.	50 " to 55	+ 2.00 . "
4.	55 " to 60	+ 2.5 "
5.	60 " to 70	+ 3.00

Refractive Index :-

Light rays travels through the air at a speed of about 300000 km/ second

Refractive index :- relative measure of transmission of light

Refractive index of a media = Light velocity in air / Light velocity in 2nd media.

Refractive index of human Lens = Light rays velocity in air / Light rays velocity in lens

= 300000 km/ second = 2,14, 285 km/second

= 1.4.

Note : - The refraction depends upon the difference between refractive indices of two media and the affect of the beam of light traverses the interface between the media.

Refractive index of cornea - 1.38

" " Aqueous humour 1.34

" " Crystalline Lens = 1.4

" " Vitreous humour = 1.34

Note : - Refractive index increases in myopia and decreases in Hypermetropia.

Accommodation of Lens:-

Adjustment of the optical apparatus so as to change the refractive power of the eye, when the image of a near object is brought into foccus on the retina, is described as accommodation.

There is no need of accommodation.For focussing the parallel rays of distant objects, but accommodation is needed to focus the divergent rays of near objects, for that the dioptric power of the Lens should be increased by increasing its curvature, for this mechanism under the influence of nerve impulses there is contraction of ciliary muscle relaxation of suspensory ligament and the fibres attached to the Lens capsule, this results in loosening of capsule and the Lens become more convex in shape owing to its elasticity. After near objects, visualisation to see the distant objects the dioptric power of the Lens should be reduced by flattening of lens (ciliary muscle relaxation, contraction of suspensary ligament and fibres attached to the Lens capsule, causes flattening of Lens). This adaptation takes place continuously for the proper visualisation of the objects at different distances.

If the object is brought closer then a point is reached at which inspite of strong contraction of ciliary muscle the object is not focussed, the rays from that object is so divergent. The nearest point at which the object is clearly focussed with full accommodation is the near point. The distance between the near point and the eyes increases with age due to hardening of Lens and become diffficult appoximately after 40 yrs of age (presbyopia) the far point is at infinity (20feet) and the distance between the far point and near point is called Range of accommodation.

The greater distance between the object and the eye, the lower the degree of accommodation ; and the closer the objects viewed the greater the degree of accommodation.. The accommodation get failure in paralysis, spasm, due to constant near work, after diphtheria, in certain cranial injuries injection of atropine intc conjunctival sac, in poisoning with methylalcohol plasmocide, etc.

1) In normal eyes the parallel rays from infinity fall on the principle foccus of the lens.

2) In myopia the rays are convergent and focussed before the retina so only for the correction, divergence sperical Lens(concave) of proper strenght is used for the correction.

3) In hypermetropia the rays are divergent and fall beyond the retina so only for the correction, convergent sperical Lens(+ convex) of proper strength is used for the correction.

4) In presbyopia inability to read the small print occurs due to the reduced accommodative capacity of Lens (the Lens cannot become more convex to focus the more divergent rays of near things) so only sperical convex Lens is used for the correction of this error.

5) In irregular Astigmatism light rays are most irregular in all meridians so spectacle Lendses are not useful only contact Lenses and Keratoplasty are benificial.

6) In simple regular astigmatism cylindrical Lenses correct the error

7) In compound and mixed astigmatism cylindrical + sperical Lenses are needed for the correction of error.

8) Accommodation of Lens required only for Near objects to converge the diverging rays emerging from near things.

9) In hyper metropia or presbyopia correction shold be proper, to give rest for the accomodation of Lens if not causes accommodative asthenopia.

10) The symptoms of accommodative asthenopia are eye strain, head ache, eye pain, redness, heavyness in lids, hazy blurring of vision etc.

11) Simply giving the spectacles cannot control the disease for that cause should be treated, nutritious food, vitamins should be supplemented, patient is advised not to expose to hot, dusty, Bright things.

12) Some children are habitated to handle the books very close to the eyes - that cause visual errors so parents should take care for avoiding those things.

13) Mydriatics (pupil dilator) are used for fundoscopy but it is contra indicated in glaucoma

14) Heavy exercises, intake of toxic things like tobaco alcohal etc. Bright light or dimlight prolonged exposure, chronic exposure to foreign bodies, malnutrition, hypo vitaminosis, injuries, unhygienic conditions, all the common aetiological points causes visual errors, so all those should be avoided.

VISION

Eye ball is the end organ of optic nerve, it is meant for visual perception. The light rays after travelling through the refractive media has to fall on fovea centralis of macula of the retina.

The white and monochromatic light rays which fall on fovea causes Bio-chemical stimulus in cones and cone fibres, those reach the cerebral cortex through the optic tract and cause photophic vision(Bright and colour vision perception) the rays of low intensity face on the peripheral portions of retina where rods are predominent and causes Bio chemical stimulus in rods and rod fibres, those reach the cerebral cortex through the optic tract and produce scotopic (dim) visual perception. For the normal perception of vision Length of the eye ball ; Normal (position surfaces, refractive Index, functions) refractive media, Normal Intra ocular pressure, Reltina, optic disc, optic tract and visual centre are responsible.

So many factors affects the visual perception, those are .
1) Deviation of visual axis 2) Lesions of appendages of eye ball 3) corneal lesions like flat cornea or Kerato conus, central corneal ulcers or opacities 4) Aqueous precepitations (Hypopyon Hyphaema) 5) Affection of pupillary reflex 6) Accomodatory problems of lens, central lental opacities, cataract 7) Vitreous degeneration, Vitreous haemorrhages 8) Retinal detachment, atrophy, Retinitis improper production of Rods and cones macular degeneration, macular burn 9) Lesions of optic disc, optic nerve, central connections and visual centre .10) Congenital lesions, traumatic lesions, Idiopathic causes. 11) Malnutrition, Vitamin defficiencies chronic systemic lesions, endocrinal disorders, poisionous thinks regular usage of Tobacco, alcohol (Amblyopias) Above factors causes disturbances in the normal Visual perception.

BLINDNESS

Day Blindness (Hemeralopia)

The Vision is poor in Bright light But better in dim light (In dim light the pupil dilates and so the peripheral cornea lens and retina are used for vision).

Causes :-

1) Pathological changes in macula.
2) Central opacity of Lens or cornea
3) Congenital abnormality Commonly associate with total colour blindness.

(In Ayurvedic science it is corelated to **pitta vidagdha drusti** in which during the day time due to piita prakopa the person cannot see the things But can see the objects at night due to pitta shaman).

COLOUR BLINDNESS

Inability to recognise the colours either partially or in total, is known as colour blindness.

Causes :-

A) Congenital Causes :-

It is bilateral and incurable (either partial or total blindness) No colour is recognised and see the things in grey.

B) Acquired Causes :-

It is due to diseases of macula, and optic nerve ex: Toxic amblyopias, macular affections in various diseases.

There are 3 Primary colours (Red - green - Blue) which when mixed together produce rest of the colours of spectrum.

It congenital colour blindness the 3 basic colours are not seen, they are grouped into the following 3 groups.

1) **Total Colour Blind ness (Achromics)**
All the 3 colour factors are not seen

2) **Mono Chromics :-** Among the 3 only one colour factor is seen .

3) **Dichromics :-** Among the 3, only 2 colour factors are seen, it is sub divided into
a) Protanopes - Red colour blind
b) Deuteranopes - Green Colour blind.
c) Tritanopes - Blue Colour blind.

NIGHT BLINDNESS (Nyctalopia)

It is a condition in which the vision is defective at night But good in the day time.

It occurs as a symptom in certain retinal diseases and some times associate with systemic disorders like vitamine " A" deficiency etc.

Causes :-

1) Congenital -Hereditory causes :-
It associate with other anomalies of retina as in oguchi's disease(usually occurring in Japan.)

2) Diseases of eye ball like :-
a) Retinitis pigmentosa b Peripheral chorio- retinitis c) myopic degenerative changes in the peripheral retina. d) Chronic simple glaucoma with marked contraction of visual field . e) Retinal detachment.

3) Systemic diseases :-
a) Vitamin A deficiency
b) Pathological changes in liver, like cirrhosis of liver.

Note :- It is mainly due to damage of rods or deficient regeneration of visual purple due to vitamine "A" deficiency. that can be measured with adaptometer.

Amaurosis :-
Amaurosis means complete loss of eye sight.

Causes :- 1) Vitreous haemorrhage as in Eale's disease 2) Acute exudative choroiditis 3) Detachment of retina 4) Thrombosis of central vein of retina 5) Acute retrobulbar neuritis 6) Occlusion of central artery of retina 7) Acute congestive glaucoma 8) Injury as by pen knife, arrows or bombs etc. 9) Neuro myelitis optica or Devic's disease 10) Optic neuritis.

Amblyopia :-
It is a disease in which partial loss of vision occurs not due to any obvious or demonstrable organic lesion (inherent defect with no demonstrable physical sign) ex. toxic amblyopia due to Tobacco usage etc.

a) It is due to supression of macular function, Known as amblyopia ex anopsia.It commonly associate with squinting eye in the child .

b) disuse of the macula as in case of uncorrected high myopia or due to opacity of the media (corneal opacity or cataract etc.)

Hemianopia :-
It is a condition in which one half of the visual field of each eye is affected or damaged .

Causes :-
Syphilitic meningitis, gumma or tuberculoma at the base of brain,

Tumour or aneurism in the neighbourhood of the optic tract, cerebral haemorrhage ; thrombosis trauma and tumour of the occipital lobe of the brain.

It is produced by a lesion in the optic tract, Lateral geniculate body, optic radiation or calcarian cortex of one side. It is characterised. by sparing of the macular area.

Diplopia (Double Vision)

When an object appears double it is called diplopia. it is of two types 1) Uniocular diplopia 2) Binocular diplopia .

1) Uniocular diplopia :-

When two images of an object fall on the retina, uniocular diplopia is produced.

Causes of uniocular diplopia. :-

a) Sub luxation of lens b) incipient. cataract c) Large irido dialysis d) Kerato conus e) Retinal detachment.

2) Binocular diplopia :-

When the images of an object do not fall on the corresponding points of the retinae, diplopia is produced. Diplopia disappearse by closing one eye It may be grouped as .

a) Vertical Binocular Diplopia :- When one image is situated above or below the other.

b) Horizontal Binocular diplopia :- when the images are placed side side, it is called Horizontal Binocular diplopia.

1) Homonymous Binocular diplopia :- The false image present on the same side of the deviated eye .

2) Crossed Binocular diplopia :- The false image is seen Opposite side of the deviated eye .

Causes of Binocular diplopia :-

1) Paralysis of extra ocular muscle.
2) Displacement of eye ball due to space ocupying lesion in orbit.
3) Restriction of the movements of the eye ball due to pterigium or symblepharon etc.

Phthisis Bulbi :-

It is an atrophic condition of eye ball which becomes soft and shrunken.

Causes :-

a) Keratomalacia b) Panophthalmitis. c) Endophthalmitis d) Severe Irido Cyclitis e) Absolute glaucoma.

The solid contents of the eye ball are disintigrated and become pus, Hypotomy follows shrinkage of eye ball.

Treatment :- Enucleation of the eye ball.

Internal Ophthalmoplegia :-

It is a condition in which there is paralysis of intrinsic muscles of eye ball (ciliary muscle, sphincter pupillae of Iris) Causes loss of accommodation of Lens due to oculomotor nerve palsy.

External Ophthalmoplegia :-

It is a condition in which there is paralysis of Extra ocular muscles (4 recti, 2 oblique and Levetor palpebrae superioris) commonly due to syphilis.

Colour haloes :-

Haloes are seen as coloured ring around artificial lights. The conditions in which colour haloes are seen are as follows.

1) Acute or sub acute conjunctivitis :- The flakes of mucous over the cornea give rise to colour haloes owing to their prismatic effect.

2) Closed angle Glaucoma :-

The haloes appear in this disease due to Oedema of corneal epithelium and altered refractive index of the corneal lamellae .

3) Lenticular Haloes :- Lental changes during early cataract may produce haloes.

Note :- Among the above 3 diseases, haloes of acute conjunctivitis can be easily recognised and for the differential diagnois of closed angle glaucoma and early cataract, stenopic slit is passed across the eye if haloes. remains in tact that is glaucoma, and if haloes broken up that is cataract.

Dimvision :-

It is a symptom, observed in many diseases . It is due to following causes.

1) Central corneal opacity or ulcer.
2) Corneal oedema.
3) Interstitial Keratitis.
4) Keratopic precipitations.
5) Aqueous precipitations (Hypopyon. Hyphaema etc).
5) Occlusio pupillae and seclusio pupillae etc.
6) Lental & Capsular opacities.

7) Glaucoma 8) Vitreous degeneration, haemorrhages etc. 9) Macular degeneration 10) Optic neuritis. 11) Vitamin A deficiency 12) Chronic specific systemic. disorders 13) Toxic amblyopia 14) Hypertensive, Diabetic. retinopathy etc. 15) Lesions of central connections etc. 16) Increased or Decreased Anterio posterior diameter 17) Increased or Decreased refractive index of the media 18) Lesions of Lens accommodation. 19) congenital or developmental or heriditory causes 20) Idiopathic causes.

BLINDNESS PROFILE AND ITS CONTROL

The Term Blindness implies to loss of perception of light either partially or totally. If the vision is reduced more than 3/60 Those patients can be treated as the blind.

At present Nutritional deficiencies Trachoma ,Glaucoma, cataract, ocular injuries, Retinal lesions, optic nerve lesions and visual centre lesions, are the common diseases that cause blind ness.

As per, I.C.M.R. Survey.

1) Cataract	Blindness	55%
2) Glaucoma	"	3 %
3) Nutritional	"	2%
4) Corneal	"	20%
5) Posterior segment	"	20%

Govt of India has launched National plan for the control of Blindness (NPCB) in 1976, to establish permanent eye care facilities to controle and treat the blindness. The eye care centres are established at different levels of the country. Many primary health centres, Districts hospitals ,medical colleges, and voluntary organisations.etc, are conducting the surgeries for cataract glaucoma etc diseases,and distributing vitamin A, B .Complex, folic acid Iron etc tabs, and educating thepeople to prevent the traumatic eye lesions etc. Like this govt of India is trying maximum to controle the blindness.

A) KU-POSHANAJANYA NETRA VIKARA

(Mal- Nutritional and Vitamin deficiency, eye diseases).

Eye ball the organ of vision is the most important sensory organ among the five (Pancha gyanendria)" Sarvendrianaam Nayanam pradhanam " A blind man though he is having the richest facilities, are merely useless so only it is advised to save the eye from the diseases. There are so many factors responsible for causing the eye diseases, among them nutritional deficiencies and vitamin deficiencies are also causes different types of eye diseases, they are follows.

1) Vitamin "A" Deficiency :-

Vitamin A deficiency causes xerosis (Xerophthalmia), Keratomalacia, Night blindness, skin lesions, demyelination, diminished resistence to infections etc. The daily requirement is 4000. I.U. The sources are " Leaf Vegetables, yellow fruits, milk, butter, fish, egg, animal fat, codliver oil, halibut oil carrot, shigru leaves etc.

Xerosis ;-

The dry lustreless conjunctiva with degenerative changes is known as xerosis (dirty grey coloured patches and Bitodes spots are seen at or near Limbal conjunctiva).

Keratomalacia :-

Degenerative changes are seen in Conjunctiva (Dirty grey coloured patches, bitods spots and dry lustre less conjunctiva) and cornea (dull, insensitive, hazy cornea, softening , tissue necrosis and with severe complications.)

Stages of Keratomalacia :-

1) Night blindness - due to diminished production of visual purple (Rodopsine)
2) Conjunctival degenerative changes.
3) Pre Xerotic changes of cornea (dull hazy cornea with slightly reduced sensation.
4) Corneal tissue necrosis with epithelial desquamation.
5) Corneal ulceration spreads in total and finally cornea is sloughed out.
6) Complications like Anterior staphyloma, Adherent leucoma, panopthalmitis, Blindness etc arises.

Treatment :-

1) Oral and systemic vitamine A administration (beneficial in pre xerotic stages).

2) Systemic vitamin "A" 100000 units deep I.M. injection, weekly twice for 4 weeks.
3) Antibioties, Atropin 1 % ointment, lubricant eyedrops etc are given.

2) **Vitamin B. Complex :-**
Beneficial in Toxic retino neuropathy and Toxic amblyopias

B1 (Thiamine) :-
The deficiency causes Beriberi, Toxic retino neuropathy etc.
a) Paraplegic or dry beri beri, causes peri pheral neuritis ptosis and lesions of lateral rectus muscle.
b) Cardiac Beri beri or wet beri beri causes peripheral neuritis and ocular palsies.
c) Cerebral beri beri or Wernicke's encephalopathy causes ophththalmoplegia.

The sources are,
Lean pork, beans, peas, nuts, grains Flour, beaf, Yeast etc.

Note :- The daily requirment is 100 mg.

B2 (Riboflavine) :-
Sources are same as B1, The deficiency affects Glossitis, cheilosis, Vascularising Keratitis, Burning sensation in the eyes and Photo phobia. The daily requirement is 10 mg .

Nicotinic acid :-
The deficiency causes pellagra, glossitis and skin lesions, The daily requirement is 150 mg.

B12 (Cynocobalamine) :-
The deficiency causes peripheral neuritis, it is useful in Trigeminal neuralgia, Herpes zoster and in Tobacco amblyopia. The daily requirement is 1000 micro grams.

Vitamin " C" (Ascorbic acid) :-
The deficiency causes scurey, ocular haemorrhages, chronic inflammation etc. **The daily requirment is 300 to 500**

Vitamin "D" (Calciferol)
The deficiency causes Rickets, osteo malacia, tetany, altered Calcium metabolism, myopia cataract etc. The daily requirement is 1000 units.

Vitamin " K" (Dimethylnaphthoquinone) :-
The deficiency causes intra ocular haemorrhages. **The daily requirement is 20 mg.**

Vitamin "P" (Flavone) :-

The deficiency causes intra ocular haemorrhages. The usual therapeutic dose is 1 gram daily.

The changes in the proteins, fats carbohydrates and minerals of the body tissue also produces visual problems.

1) In senile cataract :- Changes in proteins fats etc causes denaturation of Lens, leads to cataract.

2) Denaturation of scleral coat (Thinning) due to malnutrition may leads to Anterior or posterior staphyloma, myopia etc.

3) Anaemia (Raktha dhathu Kshaya) May produce so many changes in Retina and optic nerve .

4) The changes in the ratio of Calcium and phosphate, sodium and potassium may produce cataract .

5) Iron and Folic acid deficiency (vitamin minarals) also produces visual errors.

B) EYE DISEASES IN COMMON INFECTIONS

1) In Septic Abortions :-
a) endophthalmitis b) Orbital cellulits

2) In measles :-
a) Conjunctival hyperaemia, sub conjunctival haemorrhage b) Kopliks spots in Conjunctiva & Xerosis c) acute muco purulent conjunctivitis d) Optic neuritis - dimvision.

3) In Diphtheria :-
a) Membranous conjunctivitis b) Paralysis of accommodation c) Paralysis of extra ocular muscles, especially lateral rectas. muscles. especially lateral rectus.

4) In Typhoid Fever :-
a) Logophthalmos corneal ulcer b) optic neuritis.

5) In Whooping cough :-
a) sub conjunctival haemorrhage, orbital haemorrhage, proptosis.

6) In mumps :-
a) Acute dacryo cystitis b) Uveitis.

7) In meninngo coccal meningitis :-
a) Metastatic conjunctivitis b) Loss of pupillary reaction c) paresis of extra ocular muscles d) metastatic endophthalmitis and panophthalmitis e) complete loss of vision due to optic neuritis.

8) In Tuberculosis :-
a) Conjunctivitis, Interstitial Keratitis, uveitis, chorio retinitis etc.
b) Tubercular meningitis may lead optic atrophy c) Intra cranial tuberculoma may produce papilloedema .

9) In Syphilis (Acquiried) :-
In Primary stage chancre of the conjunctiva and conjunctivitis occurs

In Secondary stage :- Uveitis and nodules develop on the iris.
In tertiary stage :- Chorio retinitis development of gummata in the orbit.
In congenital syphilis:- Interstitial Keratitis, Uveitis and chorio retinitis develops.

6) In Leprosy :-
Nodules on the skin of the eye lids, falling of the hairs of eye lashes and eye brows, conjunctivitis, Keratitis, pannus formation, leucoma, Lepromatous nodules on Sclera, Granulomatous Uveitis and Dacryocystitis develops.

C) Parasitic Infections :-
1) In Malaria :-
a) Dendritic ulcer of cornea
b) Embolism of retinal artery develops.

2) In toxoplasmosis :-
Necrotizing chorio retinitis develops particularly in infants.

3 In taenia echino coccuas infection :-
a)Hydatid cyst in the orbit .
b) Intra cranial cyst formation may produce papilloedema.

4) In Taeniasolium Infection:-
a) Cysticercus cyst in retina and vitreous .
b) Cyst formation the orbit - & Conjunctiva.

D) Metabolic diseases.
1) In gout and Rheumatism
a) Episcleritis Scleritis and Uveitis develops.
2) In Diabetic mellitas
a) Changes in refraction.
(When blood sugar falls causes Hyper metropia, when blood sugar raises cause myopia)
b) Haemorrhagic iritis and new blood vessels on the Iris.
c) Diabetic cataract
d) Diabetic retinopathy
e) Lipaemia retinitis (Retinal vessels appear as filled with milk.
f) extra ocular muscle palsies
g) Optic neuritis etc develops.

E) Diseases of Kedney - Nephritis :-
1) Passive oedema of eye lids.
2) Renal retinopathy develops. (Flame shaped retinal haemorrhages and woolly exudates in retina)

F) Toxaemia of Pregnancy :-
1) Loss of vision due to spasm of retinal vessels.
2) Retinopathy (retinal detachment due to transudation in the sub retinal space)

G) **Cardio vascular system :-**

1) Hypertensive retinopathy
2) Benign and malignant hyperten.
3) Cardiac regitation from mitralsion Valvular disease causes central retinal artery occlusion.

H) **Blood Diseases :-**

1) In Leucaemia
   a) Dilatation of Vessels
   b) Retinal haemorrhages
   c) Sub Conjunctival haemorrhages.

2) In purpura and haemophilia
   a) Sub conjunctival retinal and orbital haemorrhages develop.

3) In pernicious anaemia Retinal haemorrhages are seen with central white spots.

I) **Intra Cranial Lesions :-**

1) Meningitis a) Cerebrospinal meningitis produces unilateral paralysis of 3,4 and 6 cranial nerves, papillitis and endophthalmitis .b) Tubercular meningitis produces papillitis and papilloedema.
2) encephalitis causes 3rd nerve palsy, ptosis, nystagmus and paresis of convergence.
3) In sub dural haematoma papilloedema occurs.

4) In sub arachnoid haemorrhage
   a) Sub hyaloid haemorrhage in retina b) proptosis c) Ocular palsies occur

5) In Intra cranial tumours.
   a) Papilloedema b) Ocular palsies (in pitutory tumour - Bi temporal hemianopia occurs).

6) In head inury .
   a) Contraction of the pupil
   b) Dilatation of pupil without pupillary reflex due to raised intra cranial pressure.
   c) Paralysis of extra ocular muscles if the base of the skull is involved.
   d) Optic atrophy e) Sub conjunctival haemorrhage
   f) Field defects if Visual path way is affected.

7) In intra cranial aneurisms .
   a) Aneurisms in the vessels of circle of willis causes ocular palsies.
   b) Aneurisms of the internal carotid artery, out isde the cavernous sinus causes optic atrophy.

c) Aneurism of internal carotid artery inside the cavernous sinus causes oculomotor palsies and pulsating exophthalmos.
8) In migraine - central vision defects and hemianopia are produced.

J) **Demyelinating diseases.**

1) In disseminated sclerosis causes Nystagmus, Dim vision, due to retro bulbar neuritis, and extra ocular palsies.

2) In neuro myelitis optica (Devic's disease) Causes sudden blindness due to papillitis, and dilatation of pupil due to loss of visual acuity
3) Schlders disease (encephalitis peri-axialis diffusa) causes blindness papilloedema and optic atrophy .

K) **Diseases of Muscles :-**

1) In myasthenia gravis
Causes ptosis and defect in the eye move ments due to weakness of muscles.

L) **Endo Crine Disorders :**

1) In thyrotoxic exophthalmos, or grave's disease (excessive thyroxin secretion).
   a) Bilateral Exophthalmos which is reducible on pressure.
   b) Retraction of the upper lid .
   c) Lid lag on attemp to lookdown .
   d) Weakness of convergence
   e) Pigmentation of skin of upper lid.

2) In Thyro trophic exophthalmos (Excessive thyrotrophic hormone).
   a) Marked proptosis which is irreducible on pressure.
   b) Marked chemosis of Conjunctiva and oedema of the lids.
   c) Exposure Keratitis
   d) External ophthalmoplegia.
   e) Optic atrophy

3) Deficient secretion of thyroxin causes cretinism in infants it causes puffy eye lids, posterior cortical cataract and in adults it causes myxoedema it produces solid oedema of eye lids.

4) Parathyroid deficient secretion (Tetany) may cause cortical cataract.

5) Pitutory tumour causes Bitemporal hemianopia (Loss of vision in both temporal sides) later nasal sides also affects and causes complete blindness.

INJURIES TO THE EYE LIDS AND EYE BALL

Injuries of the eye lids and eye ball can be grouped under the following categories.
1) Mechanical injuries 2) chemical injuries .
3) Thermal injuries 4) Electrical injuries.
5) Radiational injuries.

I) Mechanical injuries :-
a) Contusion injuries b) penetrating or perforating injuries c) Retained Foreign bodies.

a) Contusion injuries caused by blunt instruments :-
Clinical Features :-
1) Eye Lids :-
Ecchymosis or bruising of eye lids or Haematoma (Black eye) of eye lids occurs. The injury causes swelling of eye lids and surrounding tissue, it may be impossible to separate the eye lids for several days But the blood gradually becomes absorbed and full ocular mobility is restored. Immediate cold compress is needed to stop furthur bleeding.

2) Conjunctiva :- Lacerated with sub conjunctival haemorrhages.

3) Cornea :- Abrasions, corneal opacities etc. causes dimvision, photophobia discomfort and Lacrimation.

4) Sclera :- Get Ruptured with Prolapse of Uveal tissue and even vitreous (if the injury is severe.)

5) The Anterior chamber :- Hyphaema, increased intra ocular pressure and reddish brown cornea..

6) Iris - Pupil :-Traumatic miosis due to irritiation of nerves, then traumatic mydriasis due to paralysis of pupillo motor fibres, Iridodialysis (detachment of Iris from ciliary body), Antiflexion of Iris, irregular pupil and traumatic aniridia entire iris may torn off from ciliary body and sinks to the bottom of anterior chamber.

7) Lens :-Concussion cataract, Sub luxation of Lens, and dislocation of Lens.

8) Vitreous humour :- Liquification of vitreous, vitreal haemorrhages, opacities, organisation of opacities (may lead to Retinitis proliferans,)

9) Retina :- Retinal oedema, Retinal haemorrhages, and retinal detachment.

10) Choroid :- Rupture of choroid and choroidal haemorrhages.

11) Optic nerves :- Avulsion of optic nerve which is rare.

12) Intra ocular pressure :- Secondary glaucoma or hypotony of eye ball.

Treatment :-

Blackeye :- Cold compress, bandage,
Subconjunctival haemorrhage :- Naturally disappears within 2 or 3 weeks and Local eye drops like argyrol is useful.
Rupture of Cornea and Sclera :- Suturing and ulcer therapy.
Hyphaema and Raised intra Ocular Pressure :-
Paracentesis to drain the pus.
Corneal abrasions without glaucoma ;-
1% Atropin sulphate drops (mydriatics) Hydro cortisone drops and antibiotics are useful
Irido donesis & Irido dialysis :- Surgical correction.
Concussion cataract :- Cataract surgery.
Dislocated Lens :- Lens should be removed.
Choroidal, Vitreal and retinal Haemorrhages:- Prognosis is not good, rest and laser therapy etc. are beneficial upto some extent.
Traumatic Glaucoma :- (Miotics) diamox caps etc and surgery are useful.
Any foreign body :- If lodged in cornea sclera etc.- should be detected and removed.

B) Penetrating or perforating injuries. by sharp instruments. or small particles travelling at a high speed.

In this lesion apart from actual trauma there is always high risk of introduction of infection into eye ball that cause severe complications.

a) Vertical cut injury of lid may cause cicatrisation and ectropion, a wound on the lid margin produces a notch (traumatic coloboma).
b) Wounds of Conjunctiva (incised or lacerated) associate with sub Conjunctival haemorrhages.
c) A penetrating corneal wound always leaves behind an opacity after healing. there is always a chance of falling of intra ocular pressure immediately following the injury due to leakage of aqueous humour through the perforation.
d) Wounds of the sclera - a penetrating injury of sclera commonly associated with prolapse of uveal tissue and also vitreous. .
e) Wounds of the Lens - cause traumatic cataract and may also cause secondary glaucoma.
f) Infection by spreading through the perforation may cause severe iritis, Iridocyclitis, hypopyon, panophthalmitis etc complications.
g) Risk of sympathetic ophthalmia in the other eye.

Treatment :-

1) Injury of lids must be carefully repaired in layers if not causes epiphora ectropion and coloboma of lids.
2) Removal of obvious dirt by normal saline wash very gently.
3) Excision of or separation of entangled intra ocular tissue.
4) Repair of the wound - Anti infective treatment (corneal -scleral tear suturing)
5) Instillation of 1 % atrophin sulphate solution with eye bandage (contra indicated in glaucoma)
6) Exogenous infection should be controlled by sub conjunctival anti biotics. or cortisones.
7) If lens is affected cataract surgery should be done
8) If secondary glaucoma develops miotic eye drops and diamox 250 mg caps daily twice by month should be given.
9) Corneal opacity should be corrected by Keratoplasty.
10) Anterior synechia is corrected by synecheotomy to prevent secondary glaucoma.

C) Retained Foreign bodies :-

These are of two types 1) Extra ocular Foreign bodies and 2) Intra ocular foreign bodies.

1) Extra ocular foreign bodies :- particles of coal, dust, iron, husk of paddy, wings of insects etc. lodge in the conjunctiva (in sub tarsal furrow) or embedded in the corneal epithelium or in the substancea propria. There is immediate discomfort, watering and foreign body sensation (blepharo spasm and severe discomfort present in corneal foreign bodies). Corneal foreign bodies may produce severe complications like corneal abrasions, opacities and ulcerative keratitis etc.

Treatment :-

1) Identification of the location of foreign bodies.
2) Removal of Conjunctival Foreign bodies with a sterile swab stick after application of Local anaestetic drops.
3) Corneal Foreign bodies should be removed with a spud or needle.
4) Application of antibiotic, and atropin ointment.

2) Intra Ocular Foreign bodies with perforating wound in the eye ball:-

The foreign bodies which commonly penetrate the eye are, particles of Iron, stone, glass, lead or spicules of wood etc. signs and symptoms depend upon the size and shape of foreign body and the extent of its entry into the eye ball (The features of perforating or penetrating wound are observed) it causes spread of infection into the eye and cause gross damage to the eye even end either with endophthalmitis or panophthalmitis.

The metalic particles stimulate Local reaction and fibrosis, Iron particles produces specific degenerative changes known as SIDEROSIS and copper particles produces CHALCOSIS .

Treatment ;-

A Thorough Examination of eye ball is needed to ascertain whether the Foreign body has actually penetrated the eye ball or not.

1) Clinical examination of each part with corneal loupe, ophthalmo scope, slit lamp and by special radiographic techniques and the location of the Foreign body should be detected.

2) Either by a hand magnet or forceps the foreign bodies should be removed from the interior of eye ball.

3) Wound healing therapy.

CHEMICAL INJURIES OR BURNS

External contact of chemicals in the form of solid liquid powder or gas, occuring in private houses laboratories or in Industries etc In general chemical burns comprises two main groups a) Alkali burns b) Acid burns.

a) Alkali burns :- These are more dangerous than acid burns,usually lime caustic soda, caustic potash, liquid ammonia or ammonium hydroxide etc are responsible agents.

Changes in the ocular tissue :-

The proteins are converted into gel like alkaline proteinates (soap or soft gelatine like) destruction of cell membrane, Lipoids are digested and become soft, so the chemical agent penetrates deep in to the tissues and causes necrotic changes in the tissues.

Conjunctiva :- Marked congestion oedema, necrosis, profuse purulent dis charge and symblepharon.

Cornea :- Destruction of epithelium, formation of opacities - ulcers and even the cornea may slough out causing anterior staphyloma.

Uveal Tissue :- Inflammation and the normal tissue replaced by granulating tissue.

Lens :- Become cataractous.

Eye ball :- get atrophied.

Note :-

At PH 11.00 to 11.2 alkalies cause severe damage to the tissue. The severity of the damage increases with the rise of P.H.

b) Acid Burns or Injuries :-

Inorganic acids like sulphuric acid, Hydrochloric acid, Nitric acid, are the common agents those cause injury to eye ball.

Strong acids causes instant coagulation of all the proteins with the formation of insoluble protinates (coagulative necrosis) this coagulated protein acts as a barrier so that there is no penetration of the chemical in to the deeper tissues and thus the lesion becomes sharply limited.

The ocular lesions are.

Conjunctiva :- There is necrosis followed by sloughing of tissues with symblepharon.

Cornea :- Sloughout completely and staphyloma forms.

Treatment of chemical burns :-

1) Thorough wash of conjunctival sac with plain water or normal saline immediately.

2) Chemical particles if any remained. it must be carefully removed with swab sticks.

3) Necrotic tags of Conjunctiva should be excised.

4) 1 % Atrophine sulphate, Steroids, Antibiotic ointment should be used to subside the inflammation and to create a suitable condition for the repair.

5) Soft contact lens application temporarily to prevent symblepharon.

6) Symptomatic therapy should be given to prevent secondary infection etc.

III) THERMAL INJURIES TO EYE BALL

These are usually caused by contact with hot bodies like glowing coal or molten metal or hot fluids. The ocular lesions depend upon the size and temparature of the hot body or fluid. It causes severe damage to conjunctiva and cornea. Ex :- at 47° C causes damage of corneal epithelium, at 65°.C Stroma suffers and at 80° C all the parts affects.

Treatment :-

1) Cold therapy 2) Excision of necrotic tags. 3) Instilling 1 % atropine sulphate ointment, steroids and antibiotics to subside the inflammation and burning pain.

4) Severe corneal damage can be corrected by Keratoplasty.
5) Symptomatic treatment.

IV) Electrical injuries to eye ball :-

High voltage electric current if passess through the head, near the orbit can cause ocular lesions like the following.

1) Ciliary and conjunctival congestion.
2) Punctate or diffuse interstitial corneal opacities.
3) Iritis and Irido cyclitis
4) Retinal haemorrhages and optic neuritis.
5) Electrical cataract.

Treatment :-

1) Lens extraction in Cataract.
2) Instillation of 1% atropin sulphate, Steroids and antibiotic eye drops.
3) Sub conjunctival cortisones and Antibiotics
4) Symptomatic treatment.

V Radiational Injury. :-

Any radiation if absorbed by a tissue causes radiational injuries, like the following.

1) Thermal Lesions :-

It occurs due to sudden release of a large amount of radiation as in exposure to arc lights or prolonged exposure to arc lights or prolonged exposure to small amount of radiation **ex:-** Development of cataract due to proloned exposure to infra red rays in furnace works and glass workers etc.

2) **Ablotic lesion :-**
Exposure to ultra voilet rays which occurs in workers engaged in o/y acetylene or arc welding (Photophthalmia)

3) **Ionizing lesions :-**
the lesions commonly seen in workers who deal with radio active ionising paints for coating the figures on the dials of clocks, who undergone deep xray therapy or radium therapy to the tumours of lids or eye ball. The Hair follicles eye lashes eye brows and lens (cataract) are affected.
Treatment :- 1) Wearing dark glasses to prevent the exposure of infra red or ultra voilet radiation. 2) For photophthalmia cold compress, Atropine, steriods and antibiotics, xylocaine drops, Bandage, relieve the symptoms.

Burns of Eye lids :-

Fire caustics, ultra voilet light or Beta and gamma radiation may cause great disfigurement, scarring, contraction of tissue, ectropion exposure keratitis and visual disability. Superficial burns affect only a part of the epithelium and are characterised by blistering, they are painful sensitive and rapidly heals without complications. Deep burns involve total destruction of the epithelium, scarring in sensitive surface, slow healing, metabolic disturbances and with complications for the management :-

1) Foreign bodies and necrotic tags should be removed 2) Oily drops instillation to prevent adhesion 3) Blisters are left intact 4) Dusting of antibiotic powders 5) Parenteral administration of antibiotics 6) Anti inflammatory and analgesic drugs 7) Superficial burns heal within 14 days 8) Deep burns which require longer time (More than 30 days) should be treated by skin graft at the earliest oppurtuntly, this accelerates healing and prevents contracture.

Burns of Conjunctiva and Cornea :-

The conjunctiva and cornea may be burnt by caustic alkalis such as caustic soda and lime, by caustic acids such as hydro choric acid salphuric acid Nitric acid etc. Alkalis cause more damage than acids. Burns cause destruction of the conjunctiva and corneal epithelium and induce inflammatory reaction in the subepithelial layer. The common clinical features are congestion and necrosis of conjunctiva, corneal abrasions opacities ulcers Blepharo spasm, photo phobia, Dimvision, symblepharon and may also cause panophthalmitis.

Treatment :

1) Irrigating the eye with tapwater or normal saline 2) Causative agent traces should be removed 3) Neutralising the causative agent a) Irrigating with weak acetic acid when injury occurs due to caustic alkalis b) Irrigating with weak sodium bicarbonate when injury occurs due to caustic acids.
4) Instillation of oily eye drops, 1 % atropin sulphate Hydrocortisone drops etc. 5) Putting of soft contact lens to prevent symblepharon 6) Bandaging.

PARALYSIS OF THE EXTRINSIC OCULAR MUSCLES.

Extrinsic ocular muscles are 6, they are 4 recti muscles and 2 oblique muscles. These perform the following actions.

S.No.	Name of the muscle	Action	Nerve Supply.
1.	Superior rectus	elevation and inward rotation. or intorsion	Oculo motor. Nerve(3rd Cranial)
2.	Inferior rectus	Depression, adduction and out ward rotation (Extorsion)	-do-
3.	Medial rectus.	Adduction or inward movement	-do-
4.	Lateral rectus	Abduction or out ward movement.	abduscens nerve (6th cranial)
5.	Superior oblique	Depression, intorsion and abduction.	Trochlear Nerve (4th Cranial)
6.	Inferior oblique	Elevation, extorsion and abduction.	Oculomotor nerve (3rd cranial)

The Extra ocular muscles and the movement of eye ball :-

1) Adduction or inward movement :- although the medial rectus is the main muscle, The superior and inferior recti also assist.

2) Abduction or outward movement - although lateral rectus is the main muscle, inferior and superior obliques also assists.

3) Direct elevation :- Superior rectus is assisted by inferior oblique
4) Direct depression :- Inferior rectus is assisted by superior obliqe

TYPES OF OCULAR DEVIATION

1) Paralytic ocular deviation :- In paralysis, defective function of one or more ocular muscles causes occular deviation, it is known as paralytic squint or strabismus.

2) Non paralytic squint or strabismus (Concomitant squint or Strabismus) it is due to anomalies of the power of convergence and divergence, A concomitant deviation is almost always Horizontal one (vertical deviation is rare, if occurs that is paretic origin).

A team of six muscles controles the move ments of eyes, four of them are the recti muscles responsible for rotating the eye ball in four cardinal directions (up, down, out and in) and the 2 oblique. muscles rotate the eye globe obliquely. The motility of the eye is controlled by voluntary and reflex mechanisms centred in cerebral cortex. **The lesions at the supra nuclear** Pathways produce conjugate deviations or paresis of both eyes equally which does not cause diplopia though themovements and positions are abnormal, due to the maintenance of relative coordination. **The lower neurous** affecting the nuclei, the nerves, the muscles produce diplopia and other paralytic squint features due to disturbed relative coordination. **The Kintetic Squint** is produced due to irritative intracranial lesions, irregular spasmodic contractions, un equal stimulation of nerve centres and due to to over action of certain muscles.

Aetiology :-

There are various causes for extra ocular muscle palsy, they are

A) Lessions of nerve supplying the muscle.

Ex :- encephalitis, neuro syphilis, disseminated sclerosis, neoplasms, Aneurisms, thrombosis haemorrhage or embolism, trauma, peripheral neuritis.

B) Lession of muscle it Self :- Abnormal insertion of a muscle or congenital musculo facial anomalies, trauma, myopathic conditions like myasthenia gravis, thyrotoxic and ocular myopathies.

Signs and Symptoms :-

Symptoms :-

1) Diplopia is the chief complaint and may be present in all or in certain directions of gaze.

2) vertigo nausea uncertain gait are associated if affected eye is kept open. on this account patients frequently keep the affected eye closed or covered.

3) Loss of binocular vision without diplopia are also observed in certain cases of ocular palsy of congenital origin .

4) Defective or excessive movement of affected eye in one or more directions.

5) Compensatory head posture or Tilting of head (ocular torticollis) in one direction, especially found in cases of congenital ocular palsies, it is adopted to prevent diplopia and maintain binocular single vision.

Signs :-

1) Deviation :- The angle of squint varies with the direction of gaze. The angle is maximum when the eye attempts to look in the direction of action of the paralysed muscle and there may not be any deviation in opposite direction.

a) Primary deviation :-

When the good eye fixes an object infront, the deviation recorded in the affected eye is called primary deviation

b) Secondary deviation :-

When the good eye is covered and the paralysed eye is made to fix an object, the deviation shown in the covered eye is called secondary deviation.

" The secodary deviation is always greater than the primary deviation in paralytic squint."

2) Compensatory head posture :-

a) In paralysis of the horizontally acting muscles , the head is turned to the direction of action of paralysed muscle.

b) If a vertically acting muscle in involved, there is tilting of head to one or other side (ocular torticollis) together with depression or elivation of the chin depending on muscle which is affected (head tilting is more marked in paralysis of the oblique muscles.)

ex :- If Right Lateral rectus muscle is paralysed, the right lateral movement of eye ball is restricted so the head turned to the right for the compensation to avoid diplopia etc.

Note :- Diplopia Nausea Vomitings etc are counteracted Partially by altering the position of head or by shutting or covering the affected eye.

3) Limitation of movement of affected eye in the direction of action of the paralysed muscle, it is recognised when the patient keeps his head fixed and tries to follow the Examiner's finger which is moved in different direction.

4) False Projection :-

The Paralysed eye does not see objects in their correct Location, it is due to increased innervation conveyed to the nerve supplying the paralysed muscle in an efford to force it to act, it can be examined by closing the patient's sound eye and telling him to point out quickly on object infront of him, with paralysed eye.

Varieties of Ocular Palsies :-

1) One muscle may be involved or Several muscles may be in volved. Lateral rectus and superior oblique commonly affected Isolately. In complete 3 rd nerve palsy rest of 4 muscles, sphincter pupillae and ciliary muscle etc are totally affected.

a) Single muscle involvement :- Either It is lateral rectus or superior oblique muscles .

b) External ophthalmoplegia:- Involvement of Recti and oblique muscles

c) Internal ophthalmoplegia :-Involvement of ciliary muscles and sphincter muscles.

d) Total or complete ophthalmoplegia :- 4 Recti. muscles, 2 oblique muscles, ciliary muscles ans sphincter muscles are involved.

e) Congenital ocular Palsy - Here diplopia may be absent due to supression of the false image by the brain by adapting compensatory head posture.

f) Paralysis of the lateral rectus : -There is limitation of movements out wards, face is tuned towards the paralysed side, Homonymous diplopia occurs on looking towards paralysed side, the images are same level and errect.

g) Paralysis of Superior Oblique :- There is limitation of movements down wards and towards sound side, the face is turned down wards and towards sound side, Hornonymous diplopia occurs on looking down, the false image is lower and its upper end is tilted towards the true image.

h) Paralysis of Oculomotor nerve :- Most of the muscles are paralysed and ptosis proceeds. on raising the eye lid diplopia with crossed higher tilted image occurs towards paralised side.

Treatment :-

1) Indentification of the cause is very important for the assessment of result (No recovery takes place in assoication with head injury) .2) Waiting for some period of time for giving scope for spontaneous recovery.3. If dipopia is trouble some the affected eye should be occluded or using proper prisms.4) Eye exercises 5) Surgical correction.

CONCOMITANT SQUINT OR NON PARALYTIC SQUINT OR STRABISMUS

Concomitant squints are produced by some anomalies of the convergence or divergence mechanism (supra nuclear affection). If is almost always have horizontal deviation (vertical deviation is rare if occurs that is paretic origin.) The visual axes don't meet at the desired objective point, i.e., one eye is fixed upon a certain object while the fellow eye is turned away, but have full range of movement and achieve the binocular single vision (No problem of diplopia). It is of two types

1) Heterophoria or Latent squint
2) Heterotropia or Manifest squint.

1) Heterophoria Or Latent Squint :-

It is a condition where there is a tendency of the visual axes to deviate from their normal alignment and which constantly being corrected by the neuro muscular effort prompted by the desire for binocular single vision.

Orthophoria :- Normal physiological condition in which the visual axes maintain a perfect parallelism

HeteroPhoria :- May be of 5 types depending on the direction of deviation.

1)	Esophoria	-	Convergent squint (Nasal side)
2)	Exophoria	-	Divergent Squint (Temporal side)
3)	Hyperphoria	-	Visual axis of one eye deviates upward in relation to that of the other eye.
4)	Hypophoria	-	Visual axis of one eye deviates downward inrelation to the other eye
5)	Cyclophoria	-	Wheel rotation of eye ball in ward or out ward (torsional)

Etiology :-

Predisposing factors :- ill health,eyestrain worries anxieties,proffessional prolonged close working (Tailers, proof readers, watch repairers etc). refractive errors anatomical defects (wide or narrow inter pupillary distane) Orbital asymmetry etc may cause squint.

Symptoms :-

If strong neuro muscular power present that compensate the heterophoria and no symptoms are produced.

Symptoms present only in decompensated heterophoria they are,
1) Head ache 2) Aching of the eyes especially after prolonged use of the eyes .3) Difficulty in changing focus from distant to near objects and vice versa 4) Blurring of vision 5) Intermittent diplopia usually under fatigue conditions. 6) Intermittent squint may occur.

Treatment :-
1) Cause should be treated.
2) Correction of refractive errors. 3) Eye straining things worries anxieties should be avoided.
4) Improvement of health .
5) Eye exercises
6) Usage of proper power prisms .
7) Surgical correction where heterophoria is due toanatomical defects.

MANIFEST SQUINT OR HETEROTROPIA

The deviation present all the time, fixation is maintained with one eye but not with both eyes at a time the angle of squint remains constant in all directions. There is no limitation of movements in either eyes. The primary and secondary deviations are equall.

Types :-

A) a) Intermittent - The deviation not presentall the time.
b) Constant - The deviation present all the time.
c) Uniocular - Deviation always manifested by same eye.
d) Alternating - Deviation is manifested and changing in the either eyes at different times.

B) a) Convergent squint - Visual axes are convergent
b) Divergent Squint - Visual axes are divergent
c) Vertical Squint - Upward or down ward deviation of visual axes.

Aetiology :- 1) Congenital defective development of extra ocular muscles 2) Refractive errors 3) Lesions of accommodation 4) Paresis of some extra ocular muscles 5) Heriditory factors 6) Debilitative disorders in child hood.

Symptoms :- 1) Physical deformity due to deviation of visual axis. 2) Refractive errors 3) Head ache and eye strain.

Treatment :- 1) When the visual axes become parallel binocular single vision is restored. 2) Correction of refractive errors.3) Orthoptic treatment (when angle of squint is small) 4) Surgery (in the presence of big Visual angle.)

NYSTAGMUS

The Normal fixation of the eyes (Steady fixation) is made possible by the neuro muscular coordination of the extrinsic ocular muscles, the retina, Vestibular apparatuas, proprioceptive end organs of cervical musculature which provide sensary stimuli, motor activity by the effect of oculo motor (3rd Cranial) nerve, and the muscle tone controle by cerebellum etc. So the lesions of any above may result in " involuntary ocular movements " which is termed as nystagmus.

Nystagmus is defined as a disturbance of ocular posture which consist of involuntary rhythmical oscillatroy rotatory deviations of the eyes, usually affecting the both eyes.

A) 1) Pendular nystagmus (both phases of the movement are of equal speed) a) Horizontal b) Vertical c) Rotatory d) Oblique

2) Jerking nystagmus (The movement is speed in one phase and slow in another phase)a) To Right b) To left c) to up d) to down e) Right rotatory f) Left rotatory g) oblique up to right h) oblique down to right.

B) 1) Ocular or fixation nystagmus
a) Physiologically induced nystagmus
b) Spontaneous nystagmus (Due to blindness, defective central vision etc.

2) Vestibular nystagmus (Due to lesions of vestibular apparatus)
3) Nystagmus of central (Brain) Origin
4) Congenital idiopathic nystagmus
5) Hysterical nystagmus.

Clinical Features :-
1) These depend upon the type of lesion..
2) Central vision is poor 3) Giddiness 4) Nausea
5) Improper fixation of objects (moving)

Treatment :-

Cause should be identified and treated.

DISEASES OF THE ORBIT

The orbit is a quadrilateral bony cavity contains the eye ball with optic nerve extra ocular muscles, Lacrimal gland vessels and nerves. all these structures are supported by Orbital fat. The Periosteum lining the bony walls of orbit is called the periorbita, infront the orbital base is partially closed by a septum extending form the upper and Lower orbital margins to the tarsal plates known as septum orbitale.

ORBITAL INFLAMMATION

It is of 3 types

1) Periostitis :- Inflammation of periorbita

2) Orbital cellulitis :- Inflammation of the cellular tissue of orbit.

3) Tenonitis :- Inflammation of the Tenans capsule which separate the eye ball from orbital contents.

1) Periostitis :-

Inflammation of the periorbita is known as periostitis, it is very rare, peri osteum near the orbital margins is commonly involved. Occasionally deeper periorbita. may be affected.

The pridisposing factors are suppurative processes in paranasal sinuses, Tuberculosis syphilis Trauma etc.

The Clinical features are a tender swelling which is fixed at the orbital margin, redness of the skin, collection of pus at the lession. discharge of pus through newly formed fistula and some times it may burst through orbital roof producing septic meningitis cerebral abscess etc.

Treatment : -

1) Treatment should be given for the principal disease (Like Tubercu losis syphilis etc)
2) Broad spectrum antibiotics
3) Evacuationof pus to prevent the spread of infection and to prevent fistula formation.
4) Symptomatic treatment.

2) Orbital Cellulitis :-

Inflammationof the cellular tissue of the orbit, usually terminating in suppuration.

Causes :- 1) Extension of inflammation from the neighbouring parts (Paranasal sinuses, teeth etc) 2) Traumatic lesions 3) Facial infection (erysipelus - Furunculosis) 4) Meta static lesions (Pyaemia - septicaemia)

Clinical Features :-

1) Swelling of lids with chemois 2) Eyeball is proptosed with reduced movements of the globe 3) Pain and diplopia follows when attempt to move the eye ball 4) Vision rarely affected (Due to retrobulbar neuritis) 5) Fever headache and discomfort in the body 6) Formation of abscess and spread of infection, if not treated properly and in time.

Complications :-

1) Optic neuritis 2) Meningitis - Brain abscess
3) Cavernous sinus thrombosis 4) Pan ophthalmitis.

Treatment ;-

1) Cause should be treated 2) Systemic broad spectrum antibiotics
3) Local heat application .4) Pus drainage by giving incision in the skin near the orbital margin .5) Symptomatic treatment.

3) Tenonitis :- It is the inflammation of the Tenons capsule of eye ball, It is a rare condition.

Clinical Features :- 1) Swelling of lids with chemosis 2) Proptosis 3) Limitation of eye ball movements 4) Painful movements of eye ball 5) Pan ophthalmitis treatment 1) Broad spectrum antibiotics 2) Evacuation of pus if formed 3) Symptomatic treatment.

Tumours of Orbit :-

Tumours of orbit are not very common

1) Benign Tumours :- Dermoid cyst, Dermo lipoma, osteoma,Angioma, neuro fibroma.

2) Primary tumours of optic nerve :- Glioma, Endothelioma, Fibroma

3) Malignant Tumours :- Sarcoma, Lympho sarcoma, carcinoma of Lacrimal gland.

4) Secondary tumours :- Extension from Naso pharyngial carcinoma, breast carcinoma hyper nephroma and neuroblastoma of adrenal medulla.

Clinical Features :-1) Unilateral proptosis, 2) Mobility of globe is impaired 3) Diplopia, 4) Visual loss 5) Palpable growth 6) Papilloedema 7) Optic atrophy.

Treatment :- Surgery and Radiation .

UNI OCULAR PROPTOSIS

It is uni lateral protrusion of eye ball.

Causes :-1) Haemorrhage in the orbit .2) Inflammatory lesions of oribt
3) Vascular lesions of orbit4) Neoplasms of orbit.
5) Invasion of some mass into orbit from surrounding structures etc.

लेख्य रोग

उत्सङ्गिनी बहलकर्दमवर्त्मनी च
श्यावं च यच्च पठितं त्विह बद्धवर्त्म ॥
क्लिष्टं च पोथकियुतं खलु यच्च वर्त्म
कुम्भीकिनी च सह शर्करया च लेख्याः ॥

(सु. उ. 9/2)

भेद्य रोग

श्लेष्मोपनाहलगणी च विसं भेद्या ग्रन्थिश्च यः कृमिकृतोंजननामिका च ॥

छेदन रोग

अर्शोन्वितं भवति वर्त्म तु यत्तथार्शः
शुष्कं तथार्बुदमथो पिडकाः सिराजाः ॥
जालं सिराजमपि पंचविधं तथार्म
छेद्या भवन्ति सह पर्वणिकामयेन ॥

(सु. उ. 8/6)

LEKHANA SADYA ROGA

Shastra Chikitsa Procedure

Lekhana sadya rogas are 9 , they are

1) Utsangini 2) Kumbheeka 3) Pothaki
4) Varthma sharkara bandha 5) Bahala varthma 6) Varthma
7) Klista Varthma 8) Kardama varthma
9) Shyava Varthma.

The surgery is explained in 3 Stages :-

1) poorva karma (preparation of the Patient)

2) Pradhana Karma (method of operation)

3) Pashchyath Karma (Post operative regimen)

1) Poorva Karma (Preparation of the patient for Surgery) ;-

a) Snehan (Oral administration of oleus drugs) b) Vaman c) Virechan d) Patient is asked to lie down (utthana shayan) on operative table where there is no dust air and heat pollution e) Patient should be controlled or holded by his friends, not to move during Lekhana therapy f) Eye lid should be everted for mrudu Sweda with a soft cloth by dipping in Lukewarm water. g) Everted Eye lid should be firmely gripped to conduct Lekhana therapy successfully.

2) Pradhana Karma (Lekhana Therapy) :-

a) Lekhana procedure commonly associate with pracchana chedana Bhedana etc. Procedures, (according to the condition of the diseases).

b) If eye lid is hard (kapha vata vitiation) Lekhan has to do with shastra

c) If eye lid is soft (Pitta Raktha vitiation) Lekhana has to do with leaves like shephalika etc.

d) In Utsanini Kumbheeka and Varthma Sharkara - **Chedan** and **Lekhana** has to do (in pakwa granthi **bhedan** and Lekhana has to do).
e) In varthmavabandha, klista Varthma, Bahala varthma and Pothaki **pracchana** and **Lekhana** has to do.
f) In shyava varthma and Kardama varthma uniform superficial Lekhana has to do
g) 1) Chedan pracchana has to do with mandalagra shastra.
2) Lekhana with mandalogra shastra or shephalika patra- Gojihwa patra etc.
3) Bhedana with Vreehi mukhu shastra,

3) PASHCHYATH KARMA (POST LEKHANA REGIMEN)

After the coagulation of beeding or exudations.
1) Mrudu sweda and pratisaran has to do.
With fine powders of manahshila Kaseesa, shunthi, maricha pippali, saindhava lavan rasanjan etc drugs and Honey.
2) After 5 to 10 minutes eye should be cleaned. with Lukewarm water.
3) Then Ghritha seka and Bandhana.
4) Treatment like wound healing therapy
5) 4th day nasya Karma Should do
6) After 5th day onwads Bandage should be removed.

Note :- In pothaki after Lekhana therapy prathisaran is advised with shunthi & saindhava lavan and pariseka with khadhira Aadhakee shigru decoction and Haridra Daruharidra Triphala Yastimadu decoction and madhu).

A) Symtoms of Adequate Lekhana therapy :-
1) Bleeding or other discharges should not present.
2) No itching sensation at the lesion.
3) No oedema
4) Relief from the problem ordisease
5) Gaining normal condition.

B) Symptoms of inadequate Lekhana therapy :-
1) Bleeding 20 Hyperaemai 3) Oedema 4) Abnor mal exudations 5) Dimvision 6) Problem is not relieved 7) Blackish Oedematous rigid eyelids with itching and sticky exudates with itching and sticky exudates 8) Inflammation of eye lids.

c) Symptoms of Excess Lekhana Therapy :-
1) Pakshma shatha 2) Pain 3) Increased exudations
4) Severe bleeding 5) Agravation of the disease with complications.

Treatment ;- 1) Vata hara sneha Sweda Pariseka 2) Lodhra Navaneetha should paste to erenda moola and processed according to puta paka - the extracted swarasa + Aja Ksheera - Aashchyotan has to do 3) Lodhra Navaneetha + Shalidhanya - puta pakwa swarasa + Ajaksheera Aashchyotan has to do swarasa + aja Ksheera Aashchyotan has to do.

BHEDAN SADYA VYADHIES SURGICAL PROCEDURES :

Bhedan Sadya Vyadhies are 5, they are 1) Anjana namika 2)Lagana 3) Bisa varthma 4) Krimi granthi 5) Sleshmopanaha.

The Common surgical treatment principles :-
1) Snehan 2) Swedan 3) Shodhan (Virechan etc) 4) Bhedana (giving incision) with vreehi mukha shastra 5) Pooya nirharan (evacuation of pus) 6) Prakshalan (cleaning the wound) 7) Pratisaran (applicatin of medicine) 8) Bandan (Bandaging) 9) Vrano pachar (Wound healing therapy) 10) Following the pathya vidhi.

1) Poorva Karma (Preparationof the patient) Like in Lekhana therapy
2) Pradhana karma :-
a) Giving incision (Bhedana) with vreehi mukha shastra to evacuate the pus.
b) In pain less bigger sleshmopanaha Lekhana and Bhedana should do .
c) In Bleeding type of upanaha pracchana and bhedan shouuld do.
d) Bigger type of Lagana - Bhedana, Kshara, Agni Karma should do.

3) Pashchyath Karma :- Pratisaran and Bandan with the following drugs.
1) In Anjana Namika Pratisaran with - manahshila Ela, Tagara saindhava lavana + Honey or Rasanjan + honey or Deepa shikha masi anjana.

2) Lagana :- Prathi saran with - Gorochan yava kshara, Tuttha, pippali and Honey

3) In Bisa varthma :- Pratisaran with Saindhava lavan kaseesa, pippali, pushpanjan manahshila Ela and Honey or ghee .

4) In Krimi grandhi :- Pratisaran with manahshila ela Tagara saindhava lavan + Honey or Triphala kwatha Tuttha kaseesa saindhava lavan Rasakriya - anjan or Rasanjan + madhu anjan.

5) Sleshmopanaha :- Pratisaran with pippali saindhava lavana and Honey.

CHEDAN SADYA ROGA SHASTRA CHIKITSA PROCEDURES

Chedan sadya rogas are 11, they are
1) to 5) - 5 types of arma
6) Sirajala 7) Sira pidika 8) Parvani 9) Varthma arsha
10) Shushka arsha 11) Vartma arbuda.

Note :- Chedan therapy is common for all the diseases

5 types of Arma chedan Chikitsa :-

a) Thin smaller membranous arma - only Lekhana therapy suggested.
Ex. Prastari arma, shukla arma and kshataja arma.

b) Thick wider fibrous membranous arma chedan and Lekhana suggested.
Ex. Adimamsa arma and snaya arma.

Poorva karma - (preparation of the patient for Excision therapy).
1) Sneha and Sweda
2) Shareer shodhan (Vaman virechana vasti etc.
3) Shiro shodhan (Nasya)
4) Oral administration of oleas foods
5) Lavan Pratisaran to disintigrate the tissue of arma.
6) Patient should be well prepared, physically and mentally for the therapy .
7) Patient is perfectly holded by his friends during the therapy.

Pradhana Karma :- Chedan Karma (Excision therapy)
1) Patient is asked to see towards apanga (outer canthus) if the arma is towards kaneenika and eye lids are widely opened.
2) Mrudu sweda at the lesion
3) Separation of arma from the floor with badisha (hooks) and thread
4) Elevation of arma with muchundi (Forceps)
5) Arma is separated and cut at the krishna mandala, then the flap is lifted towardsKaneenika Sandhi and 3/4th part of arma is cut with mandalagra shastra by leaving the 1/4 th part as residue to prevent the complications like Nadivrana Rakta srava and Drustinasha
6) The Residual part of arma should be Scraped out by the application of Lekhana anjana afterwards.

Pashchyath karma :- Post Excision regimen.
1) Pratisaran with Yavakshar shunthi, pippali, maricha and lavan.
2) Mrudhu Swea 3) Ghritha Seka 4) Cheen Bandan 5) After 3 to 5 days Bandage should be opened to observe the healing process 6) Wound healing therapy 7) Treatment of the complications if any.

After the excision of arma, if pain is associated that should be treated with the following aashchyotan (eye drops)

1) The decoctions should be prepared with Karanja beeja, Amalaki, Yasti madu and milk (should prepare according to Ksheera paka vidhi) + Honey.

2) Application of Yastimadu, Kamal Kesar, Doorva + Milk + ghee .

3) The residual part of arma should be scraped with the application of Lekhana anjana.

Symptoms of adequate Excision :-
1) Getting of normal colour to eyes .
2) Painless movements of eye ball
3) Relief from the problems etc.
4) No bleeding itching and exudation.

6) Siajala 7) Sira pidika chedan Chikitsa :-
Similar to arma chikitsa
(1)Chedan 2) Lekhan 3) Pratisaran)

8) Parvani Chedan Chikitsa :- Similar to Arma, 2/3 of Parvani should be cut with mandalagra shastra, and 1/3 should be scraped with Lekhana anjanas.

Pratisaran with saindhava lavan + Honey

Anjana for the sirajala, Sira pidika and Arma :-

Shankhadyanjan - Shankha nabhi samudraphena , Matsya Spatika padmaraga pravala Ashmantak Vydoorya pulak, mukta Loha Tamra + equally
Srotonjan - Fine powder should prepare for the Anjan therapy.

9) Varthmarsha 10) Shuskarsha 11) Arbuda Shastra Chiktisa :-

Same as Arma Chikitsa.
1) chedan 3/4 or 2/3 should be cut withmandalagra shastra.
2) Pratisaran with saindhava lavan kaseesa and pippali choorna.
3) 1/4 or 1/3 Residual part should be burnt with shalaka
4) If any residue is remained that should be scraped by Lekhana or Kshara anjana.

नेत्र क्रया कल्प

सेकं अश्च्योतनं पिण्डी बिडालक स्तर्पण स्तथा
पुटपाकं अंजनं श्चेति कल्पो नेत्र मुपाचरेत

आश्च्योतन और सेक

यथादोषोपयुक्तं तु नातिप्रबलमोजसा।
रोगमाश्च्योतनं हन्ति सेकस्तु बलवत्तरम्॥

(सु. उ. 18 अ.)

सोक आश्च्योतन विधि

''प्रागेवाक्ष्यामये कार्य त्रिरात्रं लघुभोजनम्।
उपवासस्त्र्यहं वा स्यान्नक्तं वाप्यशनं त्र्यहम्।
ततश्चतुर्थे दिवसे व्याधि संजातलक्षणम्।
समीक्ष्याश्च्योतनैः सेकैर्यथास्वमुपपादयेत्॥
''आश्च्योतनं सर्वाक्षिरोगेष्वाद्य उपक्रमः ।
नानाद्रव्यकल्पनया च रागाश्रु घर्षरुग्दाहतोदभेदपाकशोफकण्डुघ्नम्॥

(अ॰ स॰. सू॰ ३२ अ॰)

सेक आश्च्योतन मात्र

लेखने सप्त चाष्टौ वा विन्दवः स्नैहिके दश॥
आश्च्योतने प्रयौक्तया द्वादशैव तु रोपणे।
सेकस्य द्विगुणो कालः पुटपाकात् परोमतः
अथबा कार्यनिर्वृत्तेरुपयोगो यथाक्रमम्।

(सु. उ. 18 अ.)

अंजन प्रयोज्य

व्यक्तरूपेषु दोषेषु शुद्धकायस्य केवले॥
नेत्र एव स्थिते दोषे प्राप्तमंजनमाचरेत्।
लेखनं रोपणं चापि प्रसादनमथापि वा॥

(सु. उ. 18 अ.)

अंजन प्रमाण

हरेणुमात्रा वर्त्तिः स्याल्लेखनस्य प्रमाणतः।
प्रसादनस्य चाध्यर्धा द्विगुणा रोपणस्य च॥

रसांजनस्य मात्रा तु यथावर्त्तिमिता मता।
द्वित्रिचतुःशलाकाश्च चूर्णस्थानुपूर्वशः॥

(सु. उ. 18 अ.)

बिडालक

विडालका बहिर्लेपो नेत्रे पक्ष्मविवर्जिते।
तस्य मात्रा परिज्ञेया मुखलेपविधानवत्॥

पिण्डी वा पिंड़िका

पिण्डी कवलिका प्रोक्ता उच्यते वस्त्रपवृकैः।
नेत्राभिष्यन्दयोग्या सा व्रणेष्वपि निगद्यते॥

तर्पण

संशुद्धदेहशिरसो जीर्णान्नस्य शुभेदिने॥
पूर्वाह्णेवापराह्णेवा कार्यमक्ष्णोस्तु तर्पणम्॥
वातातपरजोहीने वेश्मन्युत्तानशायिनः॥
आधारौ माषचूर्णेन क्लिन्नेन परिमण्डलौ॥
समौ दृढावसम्बाधौ कर्त्तव्यौ नेत्रकोशयोः॥
पूरयेद् घृतमण्डस्य विलीनस्य सुखोदके॥
आपक्ष्माग्रात्ततः स्थाप्यं पंच तद् वाक्शतानि तु॥
स्वस्थे, कफे षट्, पित्तेष्टौ, दश वाते तदुत्तमम्॥
रोगस्थानविशेषेण केचित् कालं प्रचक्षते॥
यथाक्रमोपदिष्टेषु त्रीण्येकं पंच सप्त च॥
दश दृष्टावथाष्टौ च वाक्शतानि विभावयेत्॥
ततश्चापाङ्गतः स्नेहं स्रावयित्वाक्षिशोधयेत्॥
स्विन्नेन यवपिष्टेन, स्नेहवीर्येरितं ततः॥
यथास्वं धूमपानेन कफमस्य विशोधयेत्॥

(सु. उ. 18 अ.)

पुटपाक के भेद

ततः प्रशान्तदोषेषु पुटपाकक्षमेषु च॥
पुटपाकः प्रयोक्तव्यो नेत्रेषु भिषजा भवेत्।
स्नेहनो लोखनीयश्च रोपणीयश्च स त्रिधा॥

(सु. उ. 18 अ.)

NETRA KRIYA KALPAS (TREATMENT PROCEDURES)

In Ayurvedic samhitas, the local treatment procedures of netra are explainled in the name of Netra Kriya kalpa, they are

1. **Charaka** Mentioned 3 Kriya Kalpa 1) Bidalaka 2) Aashchyotana 3) anjanam (varthi, choorna - rasakriya)

II. **Sushrutha** mentioned 5 kriya kalpa. 1) Seka 2) Aashchyotana 3) Anjana 4) Tarpana 5) Putapaka.

III. **Sarangadhara** mentioned 7 kriya kalpa. 1) Seka 2) Aashchyotana 3) Pindi 4) Tarpana 5) Bidalaka. 6) Putapaka 7) Anjana.

" Vagbhata followed sushutha and Bhavanamishra followed sarangadhara in the description of Kriya Kalpa" :-

I) Seka :- It is indicated in acute condition of the diseases. " Medicine is poured on closed eyes (on closed eye lids) continuously, from 4" height, for a specific time, according. to doshas "

Types :-

I) 3 types : 1) snehan 2) Ropana 3) Lekhana

II) 2 types : 1) Ushna seka 2) Sheetha seka.

S.No.	Name of the method	Dosha Predominence	Duration / time.	Nature of medicine
1.	Snehan	In vata disorders	400 matra kalas (Aparahna)	Luke warm, Oily,madhura Amla Lavana aus-hada has to use.
2.	Ropana	In Pitta & Raktha disorders	600 matra Kala (madyahna)	cool, madhura Tiktha Kashaya Aushada has to use
3.	Lekhana	In Kapha disorders	300 or 200 matra Kala (Poorvahna)	Luke warm, Katu, Tiktha Kashya Aushadas has to use.

" In the Acute condition it can be done at any time "

After the treatment, eyes should be washed or cleaned with Luke warm water, and advised not to see the bright things and not to take Kapha Vrudhikara Aahara and vihara.

Samyak Seka Lakshanas 1) Roga Nivruthi (Relieved from disease) 2) Swabhavika Varna (getting natural colour) 3) Karya Patutwa, (Perfectness in the functions of the parts) 4) Vedana shanthi (Relief from pain etc)

Seka Yogas :-

1) Seka with medicated milk prepared from Erenda twak, patra, moola Ajadugda, is used in vataja Abhishyanda 2) seka with medicated milk prepared from Saindhava Lavana and in Aja dugda is used in vataja Abhishyanda. 3) Seka with medicated milk prepared from Lodhra, Yastimadu, (taken in equal quantity, fry in ghritha,) Ajaksheera is used in Pitta and Raktha abhishyanda.4) Seka with medicated milk prepared from Triphala lodhra Yastimadu manjista Sariba Kamala, grinded with water and can be used in pittaja and Rakthaja Abhishyanda.

II) AASHCHYOTANA

The medicated drops are put into eyes from 2" height, the doctor has to open the eyes of the patient with his left hand and has to put the drops with his right hand.

In sheetha ruthu And in pitta Raktha disorders cool medicine is used.

In ushna ruthu and in vata and kapha disorder luke warm medicine is used.

The medicine has to Kept in the eyes for 100 matra Kalas, after wards eyes should be cleaned with Luke warm water (Mrudu Sweda), and adivsed not to see the bright things.

Types :- 3 types, 1) Lekhana 2) Ropana 3) Snehana

S.No.	Name of the method	Dosha Pradha natha.	dosage of medicine	Nature of medicine
1)	Lekhana	Kapha Vikaras	7 to 8 drops	Luke warm, katu Tiktha Kashaya medicine.
2.	Ropana	Pitta & Raktha vikaras	12 drops	cool, madura tiktha kashaya medicine
3.	Snehan	Vata vikaras	10 drops	Luke warm, oily madhura amla lavana medicine.

1) In Kapha vitiation Aashchyotan has to do in Poorvahna (Morning)
2) In Pitta vitiation Aashchyotana has to do in madhyahna (After noon)
3) In Vata vitiation Aashchyotana has to do in Aparahna (evening)

Note :- Aashchyotana is contra indicated at night.

AASHCHYOTANA YOGAS

1) Aashchyotana with Triphala kashya is used in all types of Abhishyanda.
2) Aashchyotana with Stanya (Breast milk) can be used in vata, pitta and Raktha Abhishyanada
3) Aashchyotana with Ksheeri sarpi or ksheeri Navaneetha can be used in vataj pitta and Rakthaj Abhishyanda.
4) Aashchyotana with the decoction of Bilwadi panchamoola, Erendamoola, shighru Bruhathi, is used in vataj Abhishyanda.
5) Aashchyotana with the medicated milk prepared from Kantakari moola, is used in vataj Abhishyanda .
6) Aashchyotana with Aamalaki phala swarasa, can be used in pittaja Abhishyanda.
7) Aashchyotana with medicated milk prepared from Draksha Yastimadu, manjista, jeevaneeya dravya and milk
8) Saindhava lavana, shunti + ghritha kept for a month, after that with stanya Aashcyotan can be done in Netra paka.
9) Aaschyotana with Shigru patra swarasa in Raktaj abhishyanda
10) Aaschyotana with Milk + ghee in Raktaj Abhishyanda.

III) " PINDI OR KAVALIKA OR PINDIKA "

Medicated paste is kept in a fresh thin cloth and applied on the eyes is named as pindi.

1) In vata diseases - oleus hot medicine has to use .
2) In pitta diseases - Cool medicine has to use.
3) In Kapha diseases Rough hot medicine has to use.

PINDI YOAGA

1) Pindi with Triphala in all types of Abhishyanda.
2) Pindi with Aamalaki or maha nimba patra in pittaja Abhishyanda.
3) Pindi with Shigru patra, or Nimba patra in Kaphaja Abhishyanda.
4) Pindi with Lodhra which is fried in ghritha, grinded with Kanji is used in pitta and Raktha Abhishyanda.
5) Pindi with Erenda patra, mool in vataj abhishyanda.
6) Pindi with Nimba patra + Shunti + Saindhava lavan - in Kaphaj abhishyanda.

IV) BIDALAKA (Varthma Lepa)

Application of the medicated paste to the eye lids (externally,) except at the eye lashes (Pakshma).

Types of Bidalaka According to thickness of the medicated paste,

If the lepam is

1 " thick,	it is Utthama	(The best)
1/3 " "	Madyama	(Moderate)
1/4" "	Heena	(Minimal)

BIDALAKA YOGA

Application of the mediciated paste to the eye lids with following medicines.

1) Yastimadu, gyrica, saindhava lavana, Daru haridra, Rasanjan+ water in all types of Abhishyanda.
2) Neel Kamal, musta Daruharidra Kaleeyaka Yastimadu Lodra padmaka + Shatadhautha ghritha in Raktaj Abhishyanda.
3) Rasanjana in Kaphaj Abhishyanda
4) Hareetaki + Shunti + Tejapatra in Kaphaj Abhishyanda
5) Kumari + Chitraka patra in Kaphaj Abhisyanda
6) Dadima patra in Pittaj Abhishyanda
7) Vacha + Haridra + Nimba patra used in Kaphaj Abhishyanda
8) Shunti + Gyrica. in Kaphaj Abhishyanda
9) Lodhra get fried in Ghee and used in Vataj Abhishyanda.
10) Chandan + sariva + manjista + padmaka + yastimadu + jatamamsi Tagara + Lodr + jathi pushpa and Gyurica used in pittaj Abhisyanda.

V) ANJAN

Application of medicine to the internal surface of lid margin from Kaneenika sandhi to apanga sandhi, with anjana shalaka is known as Anjana.

CLASSIFICATION OF ANJANA ACCORDING TO ACTION OF THE DRUG.

1) Lekhana anjana :- Used in Kapha predominent disorders, drug has to prepare with all except madhura rasa.

i.e. in vata pradhana ;	with the predominence of	Amla - Lavan rasa
Pitta	"	Tikta Kashaya rasa
Kapha	"	Katu Tiktha Kashaya
Raktha	"	Kashaya Tiktha

Note :- Anjana scrapes and expels the dosha from Netra, varthma, sira, Netra Kosha and Ashru Vaha srotas, through the mouth, Nose and eye.

2) Ropana Anjanam :- The drug shoud be oily, with the predominence of tiktha and Kashayarasa, it gives strength and complexion to the eyes.

3) Prasadan anjan :- It is Prepared with madhura and sneha predominent medicines

It is used for drusti prasadana (improvement of vision) and to remove the roughness of drusti (Drusti snehana)

Note :- In vata rogas at evening, pitta roga at nights and in kapha roga mornings anjana has to do.

II) Classification of anjan according to akruthi (nature of the drug)

1) Gutica 2) Rasakriya 3) Choora

A) Gutica or Varthi:- Is used in strengthy disorders (mahabala roga).
B) Rasa Kriya :- Is moderate type of diseases (in madyama bala roga)
C) Choorna:- Is used in Heenabala roga (in minimal vitiation)

A) Gutica	a) Lekhana gutica	-	1 Harenu matra (dosage)
	b) Ropana gutica	-	1 1/2 Harenu matra
	c) prasadana gutica,		2 Harenu matra
B) Rasa Kriya	a) Lekhana Rasa Kriya	-	1 Harenu
	b) Ropana Rasa Kriya	-	1 1/2 Harenu
	c) Prasadana Rasa Kriya	-	2 Harenu
C) Choorna	a) Lekhana choorna	-	2 Shalaka
	b) Ropana choorna	-	3 shalaka
	c) Prasadan choorna	-	4 shalaka

III) Classification of Anjana according to Karma or Potency of drug (Dravya veerya)

1) Mrudu anjan	2) Teekshna Anjan
a) Snehan b) Ropana c) Prasadana	Lekhana

IV) Classification of Anjanas according to rasa (Drug taste)
1) Madura anjana 2) Amla anjana 3) Lavana Anjana 4) Katu anjana 5) Tiktha anjana 6) Kashaya anjana.

ANJANA SHALAKA ANJANA PAATRA

Anjana paatra (Vessel)		Rasa of the Anjana drug
Swarna Paatra	"	madura rasa drug
Roupya paatra	"	Amla
Mesha shrunga paatra	"	Lavana
Tamra or Loha paatra	"	Kashaya
Vydoorya paatra	'	Katu
Kamsya paatra	"	Tiktha

Anjana Shalaka :-
Note :-Shalaka should prepare with the metals as above
Ex :- 1) for madura rasa anjana shalaka should be prepare, with gold;etc
2) for Lekhana Karma, shalaka should be prepared with Tamra
3) Ropana karma - " " Loha shalaka
4) Prasadana karma - " " Swarna shalaka

Anjana shalaka should be 10 Angulas length, the two ends. should be blunt (should not sharp).Like jasmine (flower) , should be easy for handling, and should not be rough, thin, hard, and breakable.

when anjana has to apply :-
1) Body should be purified by siravyada virechana Nasya vasti etc.
2) Aamaavasta should be eliminated.
3) The eye should be free from Aama and should exhibit normal doshic symptoms, then only affer Ashchyotan Anjjana has to do.

ANJANA VIDHI

1) Mangalacharana 2) Devatha prarthana
3) Then patient is asked to sit without fear and tension.
4) Doctor with his left hand, has to open the eyes of the patient, and with his right hand he has to handle Anjana shalaka and has to do Anjana from Kaneenika sandhi to apanga sandhi and from Apanga sandhi to Kaneenika sandhi .
5) Anjan should not be more or less, hard or soft, Teekshna or mrudu, quick or delayed, if so causes injury to eyes
6) After anjana vidhi, by closing the eyes, eye ball should be rotated gently, eye lids should be moved slowly - by this the medicine perfectly spreads in the eyes.
7) The doshas dissolves and comes out in the state of lacrimation,
8) The eyes should be cleaned when discharge stops.
9) If required according to the condition **prathyanjana** has to give.

ANJAN NISHEDHA
(Contra indication of Anjana)

Anjan vidhi is not advisable for the following conditions or diseases like shrama, vegavarodha, udavartha, Rodan, madyapan, krodha, Bhaya jwara, shirodosha, Shirasnana, Netra aaghatha, sunstroke, pipasa, vomitting. Jagara, Nasya, rechan, Dhomapan.

If Anjana has given in above states causes Netra raga (Hyperaemia) srava (exudation), shoola (pain), shotha (oedema), Timira (Dimvision), and difficulty in opening and closing the eye lids.

ANJANA YOGA

1) Chooranjana yoga :-

a) Sauveer Chooranjan :-

Heat the sauveeranjan and dip in the Triphala Kashaya, for 6 times then 7th time has to dip in stanya, then the drug should be dried and powdered, this is useful in most of the eye diseases.

b) Maricha 1/2 part, pippali, samudra phena 1 part, saindhava lavana 1/2 part, sauveeranjan 1 part, togetherly powdered and used as anjan, in Kacha and netra vikaras.

c) shireesha beeja, maricha, pippali and saindhava lavan, choornajan used in savrana shukla

2) Rasakriyanjan Yoga :-

a) Krishna sarpa vasa rasakriya anjan:- Krishna sarpa vasa, Shankha, Nirmali phala, is useful in Andhatwa(Blindness).

b) Guduchi rasakriya anjan ;-Guduchi swarasa 12 grams, madhu 1 gram, saindhava lavana 1 gram mixed and grinded toghether, It is used as anjan, in Arma Timira etc. Netra vikara.

c) Babbola patra rasa kriyanjan Used in Netra srava.

3) Gutika Or varthi anjana Yoga :-

1) Karanja varthi anjan :-

Karanja beeja choorna Bhavana in palasha pushpa swarasa for many times. and used as the varthi anjana is in Netra pushpa.

2) Samudraphenadi Varthi anjan :- Samudra phena, shankha, Kukkutanda twak, shigru beeja,the prepared varthi anjan is used in shukra.

3) Naktandya nashini varthi anjan :-

Rasanjan, Haridra, Daruharidra, jathi patra, Nimba Patra - grinded with go maya ras and used as varthi anjan.

Note :- Generally Lekhana anjanas will be in powder form.
Ropana and prasadana anjanas will be either in varthi or Rasakriya form.

VI) AKSHI TARPANA

It is one among 7 Kriyakalpa, it gives nourishment to the eyes and cures the vata pitta vikara (Preventie as well as curative effects).

In this process the unctuous (oily) substance is kept in the eye for a specific time by special arrangements.

Indications 1) Tamyatha 2) Stabdatha 3) Shushkatha 4) Rukshatha 5) Abhighatha 6) Vata pitta vikara 7) Jihwatha 8) Katina varthma 9) Kruchronmeelan 10) Sirothpatha 110 Sira harsha 12) Arjuna 13) Abhishyanda 14) Adhimantha 15) Anyathovatha 16) Vata paryaya 17) Shukra roga 18) Sheerna pakshma.

Contra indications :-

1) Durdina (cloudy day), 2) Ati ushna Atisheetha ruthu (Hot or cold seasons), 3) Chintha (worries), 4) Aayasa (un easyness), 5) Bhaya (fear), 6) Shoka (weeping), 7) Shotha (Oedema), 8) raga (Hyperaemia), 9) Vedana (pain), 10) upadrava. (complications),

Procedure of Tarpana Vidhi

Poorvakarma :-

Kaya shodhana by vamana, virechan, vasti Rakthamokshan etc and Shiro shodhana with Nasya should do.

It can be given both in the morning and evenings.

Pradhana Karma :-

In sadharana ruthu (In normal season) either in themorning or in the evening it should be done.

The place should be Rajo dhooma rahitha. (without dust and smoke), Prakashavan (With bright light). Then the patient is asked to liedwon (utthana shayanam), with the paste of yava or masha, masha pali has to prepare and stick around the eyes in 2 " height, it prevents the medicine not to escape out from eye cavity. The medicine (ghritha manda) has to melt by putting the vessel in hot water **(Taptha ambu Pravilapitham),** the medicine has to pour into the cavity formed by masha pali while the eyes are closed **(nimeelitha Netram),** up to the level of eye lashes **(Aapakshmaargrath)** and the patient is advised to open and close his eye lids gradually upto specific time according to vitiation.

Aushada dharna Kalam Diseased part	Duration of the Procedure
1) In Sandhigatha rogas	300 matra kalas
2) Vardhma "	100 "
3) Shukla "	500 "
4) Krishna "	700 "
5) Drusti "	800 or 1000 "
6) Sarva	1000 "

--

1) Vataja Vikaras	1000 "
2) Pittaja "	800 "
3) Kaphaja "	600 or 500 "
4) Swasta "	500 "

--

1) Vataja 1 day 2) Pittaja 3 days 3) Kaphaja 5 days	Tarpana has to do

--

as per Jejjata	Alpadosha	-	1 day
	madyama dosha	-	3 days
	Ati dosha	-	5 days Tarpana has to do

as per Videha in healthy condition with 2 days gap.

Vataja daily

Raktha, pitta, dosha 1 day gap (alternatively)

Sanni Pathaj 2 days gap

Kaphaj 3 days gap

Pashchath Karma :- 1) After specific time of tarpana the micine should be removed by doing a perforation in mashapali at temporal side.

2) The eyes should be cleaned with yava pista.

3) Ushnodaka (Luke warm water) Prakshalana.

4) Shiro virechana & dhooma pana to save the eye from kaphaj disorders

5) Patient is advised not to see Bright - things.

Samyak Tarpitha Lakshanas :-

1) Prakasha kshamatha (tolerance to light)
2) Swastyam (health)
3) Vishada netra (fresh eyes)
4) Laghu Lochana (Lightness in the eyes)
5) Swabhavika Nidra (Sound sleep)
6) Swabhavika varna of Netra angas (normal colour and complexion of the parts.
7) Vyadhi nivaranam (health gain)
8) Laghutwam in Nimeshonmeshanam (easy in closing & opening the eyes)

ATI TARPITHA LAKSHANA

1) Gurutwa (heavyness in the eyes)
2) Avilatwa (dirty collections in the eye)
3) Atisnigda (oilyness in the eyes)
4) Ashrusrava (epiphora)
5) Kandu (itching sensation)
6) Upadeha (sticky debris collection in the eye)
7) Kapha complication.

HEENA TARPITHA LAKSHANA

1) Rukshatha (Roughness)
2) Avilatha (dirtyness)
3) Netra sravas (Lacrimation and discharges)
4) Roga vruddhi (Aggravation of the disease)
5) Rupa darshana avaroda (indistinct vision)

VII) PUTA PAKA

Indications and procedure is like Tarpana but the medicine preparation is specific i.e., the medicine is (Swarasa) extracted by puta paka vidhi. It is of 3 types .

1) Snehana putapaka 2) Ropana putapaka 3) Lekhana putapaka.

Vagbhata :- Explained prasadana putapaka instead of Ropana putapaka.

Ratio of the drugs :- Flesh 2 phala, dravya 1 phala, liquids 8 phala.

1) Snehan puta paka :- Used in Ruksha Netra, vata vikara, the medicine has to kept in the eyes for 200 matra kalas. 2 days can be given.

The medical combination is :-

Anupamamsa, vasa majja, kakolyadi varga dravyas, are used. The above medicines are grinded, bolus should be prepared and has to cover with vata hara patra and so on, this should be heated (Puta paka) swarasa should be extracted and used like in Tarpana Vidhi.

2) Ropana puta paka :-

Drusti balya. vata pitta Raktha vrana dosha hara. the medicine is kept for 300 matra kala, upto 3 days it should be done.

Combination of medicine :-

Jangala mamasa, madhu, ghritha Tiktha dravyas, stanya, the puta paka has to do for the perfect extraction of swarasa.

3) Lekhana Puta paka :-

It is used in the vitiation of Kapha dosha (Ati snigda patients). The duration is 100 matra Kala and the period is only oneday.

Medicine Combination :-

Jangala mamsa, Yakruth, Lekhana drugs like Kantha loha bhasma, Tamra bhasma, shankha bhasma. Pravala bhasma, saindhava lavana samudraphena, Kaseesa, srotonjan, dadhi, mastu, madhu, shunthi, maricha, pippali etc drugs.

Medicine should be extracted by Puta paka for the therapy.

" ANJANA YOGA " FROM SUSHRUTH SAMHITHA UTTHARA STANA

1) Anjana in shukra roga (of the children) :-

Shankha nabhi and saindhava lavan grined with Godadhi and pasted to Rasanjan, daily 2 times upto 7 1/2 days, Later on the drug should be grinded, varthi is prepared and Anjana is given with water.

2) Gutikanjan in Kukoonak disease :-

Trikatu Palandu Yastimadu Saindhavalavan Laksha - equally taken and grinded with water to prepare Gutikaanjan.

3) Gutikanjan in Kukoonak disease :-

Nimba patra, Yastimaduka, Daru haridra, Tamra bhasma, Loha bhasma, and srotonjan or Neelanjan equally taken grinded with water to prepare gutikanjan

4) Kukoonak hara anjan :-

Manahshila, maricha, shankha nabhi, Rasanjan, Saindhava lavan, Guda, madhu, taken equally and grinded to prepare anjana.

5) Kukoonak hara anjan :-

Madhurasa (moorva), Yastimadu, Aamra twak, ginded with water, to prepare anjana

6) Kukoonak hara anjan :-

Krishna loha antardhooma bhasma and ghritha or madhu given as anjan.

7) Pathyadi varthi :-

Hareetaki, Tuttha, Yastimadu, each 1 tula; maricha 16 tula, the fine powder of above drugs grinded with water and used as varthi anjan.

8) Kamsyadi varthi :- Or Rujapah varthi anjan

Kamsya mala (mase), yastimadu, saindhava lavan, Erendamoola - each 1 Tola; Bruhathi phala and moola 2 tola, grinded with Aja ksheera for 3 days, and pasted to copper vessel, next day again the paste should be grinded with Aja ksheera then pasted to copper vessel like this 7 times should grind and paste to the copper vessel. later on varthi should be prepared and preserve in a bottle, the varthi is used as anjana with Rose Water or water. In the pain ful lesions of eye ball.

9) Manahshilaadyanjan :-

Manahshila, Devadaru, Haridra, Daru haridra,Triphala, maricha, Laksha, Lashuna, Manjista, saindhava lavana, sukshma ela, swarna makshika bhasma, Lodra, Loharaja, Tamra raja, Tagara, Kukkutanda twak - equally taken and the fine powder should be grinded with cow milk for 3 days, varthi anjana is prepared and used in Timira, Arma, shukra etc diseases.

10) Tagaraadyanjan :-

Tagar, Maricha, Jatamamsi, shaileya, each one part ; manahshila Teja patra 4 parts; srotonjan, Neelanjan 16 parts, Yastimadu 16 parts - powdered and Preserved for anjana to treat the kings.

11) Bhadrodaya Anjan :-

Kusta, chandan, Ela, Teja patra, Yastimadu, Anjan, Mesha shrung pushpa, Tagar, Saptha Ratna, Uthphala, Bruhati, Raktha Kamal, Nagakesar, usheer, pippali, Tuttha, Kukkutanda twak, Daraharidra, Hareetaki, Gorochan, maricha, Vibheetak, Gruhagopika - Powdered and preserved the anjana for the treatment of kings.

12) Shresta Choornanjan :-

Srotonjan or sauveeranjan 8 parts; Tamra bhasma 1 part; swarna bhasma, 1 part, Rajatha bhasma 1 part,. The medicines or heated and dipped seperately in the following liquids-

Go maya rasa, Gomootra, Dadhi, Goghrith, madhu, tail, Madya, vasa, majja, Eladi gana, Kashaya Draksha rasa, Ikshu rasa, Triphala Kashaya Sarivadi Kashaya etc. 3 times in each above liquids. Then the medicine is packed in a cloth and kept in Rain water for 7 days after wards the medicine is dried and spatica, pravala, Tagar bhasmas are added - The medicine is powdered and preserved to give anjana for the kings etc.

13) Sannipathaj Timira Harnjan :-

Sauveeranjan is heated and dipped 21 times in Astamutra - Triphala kashaya - Then the Anjana is filled in the bone marrow cavity of Nishachar Pakshi and Kept for a month in flowing water after that the anjana is collected and grinded with mesha shrungi pushpa and Yastimadu choorna - and is used for anjan.

14) Kaphaja Timira hara anjan :-

Kaseesa Rasanjan Guda shunthi used as Rasa Kriyanjan

15) Kaphaj Timira hara anjan :-

Manashila, Trikatu, shankhanabhi, madhu, saindhava lavan, Kaseesa, Rasanjan, grinded with water - and prepared for Rasa kriyanjan.

16) Kacha roga hara anjan :-

Mesha shrunga 1 part, sauveeranjan 1 part, 2 parts shankha nabhi - grinded into fine pwoder for anjana

17) Kacha roga hara anjan :-

Phalasha, Rohitha, madhuk twak choorna, madhu, madhira, added and grinded to prepare the rasakriyanjan

18) Pittaja Timira hara anjan :-

Rasanjan, Madhu, sharkar, manahsila, Yastimadu, grinded with water and used as Rasakriya anjana.

19) Pittaja Timira hara anjana :-

Sauveeranjan, Tuttha, is grinded and fine powder prepared for anjana.

20) Ghridhra, Sarpa, Kukkuta Vasa and yastimadu, grined and used for anjana in vataja timira

21) Sroto anjan is grinded with Aja ksheera for 3 days and used for anjan in Kacha.

22) Gutikanjan in Diwandya :-

Saindhava, lavan, shimbhee Trikatu, Sauveeranjan, manahshila, Haridra, Daruharidra. Go yakruth, Rakthachandan - the fine powder is made vati and preserved to use as anjan .

23) Go or Aja Yakruth pleeha fried in sarshapa taila - dried, powdered and used as anjan in Naktandya .

24) Harenyadyanjan in Naktandya :-

Renuka, pippali, Aja asti - majja, Ela, Aja Yakruth - the fine powder is used as anjan.

25) Yakruth rasa + Sroto anjan used as varthi anjan in Naktandya.

26) Aja medo anjan in naktandya :-

Aja meda, Aja Yakruth, Aja ghritha, pippali, saindhava lavan, madhu, Aamalaki, Drakwa, used as Rasa krianjan in Naktandya (it is preserved in the cavity of Khadhira stick).

27) Go mutradi Rasa Krianjan in Naktardya:- Go mutra, go ghritha, samudra phena, pippali, madhu, Katphala, Saindhavlavan, The fine powder should be preserved in the cavity of vamsha stick for anjan.

28) Yakruth rasa - Triphala quath as rasakriya anjan in Naktandya.

29) Go Mutradi rasakriya In Naktandya:- Go mutra, go or Aja pitta, madira Yakrutha rasa, Amalaki rasa, should be prepared rasa krianjan for anjana.

30) Manahshiladyanjan in Naktandya :-

Manahshila, Hareetaki, shunthi, maricha, pippali, Bala moola, Tagar, samudraphena, the fine powder should be grineded with Aja ksheera to prepare varthi anjan.

31) Nakthandya Hara anjan ;-

Togar, pippali, shunthi, Yastimadu, Talispatra, Haridra, Daruharidra, musta, the fine powder should be grinded with aja Yakruth rasa to prepare varthi in the shape of yava to give anjan in Naktandya.

32) Srotonjan, Saindhava lavan, pippali, Renuka, the fine powder should be grinded with aja mutra to prepare varthi in the shape of yava to give anjana with Rose water in Naktandya.

33) Kashmaryadi anjan in Diwandya :- Kashmari pushpa, Yastimadu, Lodra, Daru haridra, Rasanjan, the fine powder should be grinded with Honey to give anjan in pitta vidagdha drusti.

34) Pittahara sheeta anjan ;-

Rasanjan or Karpoora, sauveeranjan should mix with mamsa rasa (of pakshi) and grinded with the pitta of Kacchapa or Rihitha matsya - fine powder is prepared to give anjana in pittaja Abishyanda and pitta vidagdha drusti etc.

35) Rasanjanadi anjan in pitta vidagdha drusti :-

Rasanjan, Amalaki Patra or jathi patra Swarasa, Madhu, Talisa patra, Gyrica, should be grinded with gomaya rasa for anjana.

36) Amra and Jambu Pushpa , should be grinded with Renuka Honey and Ghee to give anjana in Blindness.

37) Raktha Kamal, Neel kamal, uthphala, kesari Gyrica, should be grinded with Gomaya rasa, to prepare vati anjana with Gulabjal in Blindness.

38) Kubjakadyanjan in blindess :-

The flowers of Kubjak, Ashok, shala, Amra, Nalini, priyanga, uthphala, Renuka, pippali, Hareetaki, Amalaki, the grinded fine powder should be preserved in the tube of vamshi for anjana.

39) Gyrica ,saindhava lavan, pippali ,Godantha bhasma ,as anjana in Blindness.

40) Gomamsa, maricha ,shireesha beeja, manahshila - as Anjana in Blindness

41) Kapitta (Patra with patra vruntha) choorna with madhu as anjana in blindess

42) Swayamguptha phala choorna with madhu as anjana in blindess.

43) Shankadyanyanjan :-

Shankha nabhi, samudra phena, mastsya, spatica, padmaraga, praval, Ashmantak mani, vydoorya, muktha, Loha bhasma, Tamra bhasma - (equal parts.) srotonjan (equal, to all in total) the fine powder should be preserved in mesha shrunga vessel for anjana in Arma, sir jala, sira pidika.

44) Aklinna Praklinna Varthma hara anjan :-

Samudra phena, Saindhava lavan, shankha bhasma, shimbee, swetha maricha, the fine powder used for choornaonjan .

45) Aklinna Praklinna varthma hara anjana :-

Tuuttha, Rasanjan, Anjan, should grind with Rose water in a copper vessel and anjana is given with ghee.

46) Shrotonjan + Madhu given as anjan in praklinna varthma .

47) Amalaki patra phala 5 Tola, 40 tola water should heat up to 1/8 residue, then heated in a copper vessel to prepare rasa Krianjan, in Praklinna varthma.

48) Vamshi Moola Kashaya rasakriya should be prepared in a copper vessel for for anjana, in praklinna varthma roga.

49) Triphala quatha rasa kriya should be prepared in a copper vessel for anjana in praklinna varthma.

50) Phalasha Pushpa quatha rasaKriya should be prepared in a copper vessel for anjana in praklinna varthma .

51) Apamarga, quatha rasakriya should be prepared in a coper vessel for anjana in praklinna varthma .

52) Kamsya malam and Karpasa vastra masi and Aja ksheera well grinded for anjana in Praklinna varthma.

53) Kamsya malam and karpasa Vastra masi, maricha choorna, Tamra bhasma is used as anjana with Rose water in praklinna varthma.

54) Kaseesadi rasa Kriyanjan in puyalasa :-
Kaseesa, saindhavalavan, Ardraka - and madhu, well grinded and used as anjana.

55) Rasakriyanjan in Puyalasa :-
Kaseesa, saindhava lavan, Ardraka, Tamra bhasma, Loha bhasma and madhu well grinded and used as anjana .

56) Jathipushpanjan in Netrapaka :-
jathi pushpa, saindhava lavan, Ardraka, pippali, vidanga - the fine powders with madhu used as Rasa Kiryanjan.

57) Saindhava lavan, shunthi and ghritha used as anjana, in Netra paka

58) Dadima, Amlavetas, Ashmanthak, kola, kanji, saindhava lavan - water is added and boiled upto 1/4 residue, then the prepared rasa Kriya is used for anjana in Netra paka.

59) Saindhava lavana and ghee should kept in a copper vessel for a month and anjana is given in Netra paka.

60) Dadhi or dadhi masthu or sura in kept in a copper vessel for a month Later on medicine is collected and anjana given in Netra paka .

61) Ghritha + Kamsya mala, grinded and given anjana in Netra paka.
62) Saindhava lavan + Milk, grinded and given as anjana in netra paka.
63) Yastimadu + Swarna gyrika + madu, as anjan in Netra paka.
64) Saindhavalavan + Ghee + Tamra bhasma + Stanya, as anjana in netra paka.

65) Shukra vyvarnyahara anjan :-
Vamshankur, Bhalla tak, Tala, Narikela, should burnt with tilanala, 8 times water added and boiled upto 1/4 the residue, Hasti asti choorna is added to above decoction and grinded for 7 days the dried powdered is preserved for anjana.

66) Saindhava lavan as choornanjan in savrana shukla .

67) Shireesha beeja, maricha, pippali and saindhavalavan as choornanjan in savrana shukla.

68) Tamra bhasma 1 part, Rajatha bhasma 2 parts, shankha nabhi basma 4 parts, manahshila 8 parts, maricha 16 parts and saindhava lavan 32 parts the choornanjan is given in savrana shukla.

69) Shankha nabhi, kolasti, Kataka, Draksha, Yastimadu and madhu, grinded and given as anjana in savrana shukla

70) Madhu, Godantha, Samudraphena and shireesha pushpa as anjan in savrana shukla.

71) Ksharanjan in savrana shukla

72) Mugda bhasma, shankha nabhi choorna, madhu as anjana in savrana shukla .

73) Madhuksar + madhu as anjan in savrana shukla
74) Vibheetaki majja + madhu as anjanin savrana shukla
75) Shankha nabhi, shukthi, madhu, Draksha, Yastimadhu Kataka beeja, as choornanjan in savrana shukla.

76) Ikshu, madhu, sharkara, ksheera, Daruharidra, Yastimadu, saindhava lavana grinded and given as anjana in Arjuna .

77) spatica, praval, shankha nabhi, Yastimadu, madhu grinded and given as anjana in Arjuna.

78) Shankha nabhi, madhu, Sharkara, samudraphena, grinded and given as anjan in Arjuna

79) Saindhava lavan, madhu, Kataka beeja as anjana in Arjuna .

80) Rasanjan and madhu as anjana in Arjuna

81) kaseesa and madhu as anjan in Arjuna

82) Lekhyanjan in Arjuna shukra :-
Dhathu bhasma, Rasa aushada bhasma, Lavan, Ratana, Dantha bhasma, Shrunga bhasma, Trikatu, Karanja beeja, Ela and Avasaadak gana drugs, the fine powder is used as anjana.

83) Phanitha + madhu as anjan in siraharsha.

84) Rasanjan + Madhu = as anjan in siraharsha.

85) Kaeesa, Saindhava lavan and madhu as anjan in siraharsha

86) Amlavetas, stanya, phanitha, saindhava lavan as anjan in sira harsha.

87) Rasanjan, madhu, Ghritha, as anjan in sirothpatha .

87) Saindhava lavan, Kaseesa, Go ksheera, as anjan in sirothpatha

88) Shankhanabhi, manahshila, Tuttha, Daruharidra, Saindhava lavan + Madhu as anjan in siroth patha.

89) Sura, swetha maricha, makshika + Shireesha pashpa swarasa-grinded and given as anjan in sirothpatha.

90) Gyrica + madhu as anjan in Sirothpatha

91) Pata, Arjuna, shreeparni, Dhataki, Amalaki, Bilwam Bruhathi pushpa, Lodra, manjista, the fine powder with madhu or ikshurasa, anjana is given in Rakthaj Abhishyanda.

92) Chandan, Kumuda, Tejapatra, shilajith, kesara, loha bhasma, Tamra bhasma, Tuttha, nimba Niryasa, Trapu kamsyamala, powdered and well grined with madhu, varthi is prepared, for anjana in Rakthaj Abhisyanda.

93) Shunthi, Devadaru, musta, saindhava, lavan jathi pushpa, grinded with sura and Anjana applied in Netra Kanda .

94) Saindhvalavan, mircha , manahshila grinded with matulunga rasa and used as anjan in netra kandu.

95) Kaseesa, Samudraphen, Rasanjan, Jathi pushpa, grinded with madhu for anjana in Praklinna varthma

96) Shunthi, pippali, musta, saindhava lavan, swetha maricha, should be grinded with matulunga rasa - the powder is used as anjana in pistaka.

97) Bruhati or varthak, shigru, Indra varuni, patola, kiratatiktha, Amalaki etc. Riped fruits any of the above is taken, seeds are removed and the cavity is filled with pippali and srotonjan and kept for 7 days, later on medicine should be collected grinded with Honey and used for anjana, in pistaka.

98) Yavaadi ksharanjan in Balasagraditha

99) Poothi Karanja phala or puspa, shigru phala or pushpa, Rasanjan, Saindhava lavan, chandan, manahshila, Haritala, lashun, powdered and grinded with water to prepare varthi for anjana in Kaphaj Abhishyanda .

100) Hareertaki, Haridra, Yasti madu, powdered and grinded with water to prepare varthi, for anjana in Kaphaj Abhishyanda.

101) Saindhava lavan, Hingu, Triphala, Yastimadu, prapaundareeka, Anjan, Tuttha, Tamra Bhasma, grinded with water for Varthi anjan in Kaphaj Abhishyanda.

102) Trikatu, Tiphala, Haridra, vidanga, grinded with water for varthi anjan in Kaphaja abhisyanda

103) Netrabaa, Kusta, Devadaru, shankha, patha, Nakha, Trikatu, manahshila, grinded with water for varthi anjan in Kaphaja Abhishyanda

104) Jathi pushpa, Karanja Pushpa or beeja, shigru beeja or pushpa, Brahati phala or pushpa, Rasanjan, Saindhava lavan, chandan, manahshila, Haritala, Lashuna - grinded with water for varthi anjan inKaphaja abhishyanda.

105) Vydooryadyanjan in Shuktika :-

Vydoorya, spatica, pravala, muktha, shankha nabhi, Rajatha bhasma, swarna bhasma, powdered and grinded with sugar and Honey for anjan .

106) Samudra phena, is grinded with stanya or madhu and anjana is given in pittaja abhishyanda.

107) Yastimadu, Lodhra, Draksha, Sharkara, Kamal, grinded with stanya for anjana in pittaja abhishyanda

108) Lodra, Draksha, Sharkara, Kamal , Yastimadu, Vacha, grinded with milk for anjana in pittaja abhishyanda .

109) Amlavetas grineded with milk for anjana in pittaja abhishyanda, .

110) Chandan, udumbar twak, grinded with water for anjana in pittaja abhishyanda

111) Phalasha puspa or moola + Sharkara + madhu as anjan in pittaja abhishyanda

112) Shallaki Swarasa + Sharkara + madhu as anjan in pittaja abhisyanda.

113) Nishotha + Sharkara as rasakriyan in pittaja abhishyanda .

114) Yastimadu + sharkara + madhu as Rasakriya anjan in pittaja abhishyanda

115) Mustaadyanjan in pittaja abhishyanda:- musta, samudra phena, kamal, vidanga, Ela, Amalaki, Beejasar as Rasa kriyanjan.

116) Talisa patra, Ela, Gyrica, musta, shankhanabhi, powdered and grinded with cow milk for 3 days, used as anjan in pittaja abhisyanda

117) Aamalaki rasa Kriyanjan with stamya in pitaja abhishyanda

118) swarna bhasma + Stanya as anjan in pittaja abhishyanda.

119) Phalasha pushpa choorna + madhu as anjana in pittaja abhisyanda.

120) Shunthi, saindhava lavan Rasa kriya + Ghritha as anjana in vataj netra roga

121) Aanupa janthu vasa, saindhava lavan, shunthi choorna, as anjan in shuskakshipaka.

122) Saindhava lavan, Daru haridra, shunthi, powdered and grinded with mathulunga rasa, dried, ghee added and preserved, then with milk or water Anjana is given in shuskakshi paka .

123) Haridra, Daru haridradi ghritha (Ghritha prepared according to ghritha paka vidhi) + Saindhava lavan, given as anjan in shuskakshi paka.

124) Shunthi + Stanya or milk as anjana in shuskakshi paka .

125) Swarna gurica 1 part, saindhava lavan 2 parts, pippali 4 parts, shunthi8 parts, grinded with water, varthi is prepared and Anjana is given with Aja Ksheera in Abhishyanda .

126) Yastimadu, Haridra, Hareetaki, Devadaru, grinded with water, varthi is prepared and anjan is given with aja ksheera in vataj abhishyanda.

127) Madhu, saindhava lavana and Gyrica perfectly grinded and used as anjana in vataj netro roga.

ANJANA YOGA FROM ASTANGA HRUDAYA

1) Haritaladi Choornanjan :-

Haritala, sauveeranjan (1:1) and Tamra raja - well powdered and applied as choornanjan in pilla roga and pakshma shatha.

2) Cotton is made varthi and bhavana done in the decoctions of Laksha, Nirgundi, Brunga raj, Daruharidra for 7 times each. The Karpasa varthi is dipped in ghee and burnt, at Last the masi of Karpasa varti should be collected and used for anjana in pilla roga.

3) Saindhava lavan, Triphala, pippali, katuki, Shankha nabhi, Tamra raja, used as varthi anjana in pilla roga.

4) Pushpa kaseesa should be grinded with Tulasi rasa in a copper vessel and is used as anjana in pilla roga .

5) Rasanjan, sarja rasa, pushpanjan, manahshila, samudra phena, saindhava lavana, Gyrica, maricha, should be grinded with Honey, used as anjana in pilla roga.

6) Grandi Tagara should grind with Hareetaki Kashaya Ghee is added and is used as anjana in pilla roga .

7) Devadaru is grinded in Avi mootra, ghee is added and used as anjana in pilla rogs.

8) Karanja beeja, Tulasi, Jathi pushpa, grinded and used as rasa Krianjan in pilla roga.

9) Tutta 1 phala, swetha maricha 20, +30 phala Kanji,grinded in copper vessel and is used for seka or Anjana in pilla roga.

10) Vyaghree twak, Yastimadu, Tamra raja, should be grinded with aja Ksheera and fumigated with the smoke of shami and Amalaki patra which is coated with ghee the medicine is used as Anjana in netra shoola and shotha.

11) Talisadi Vatikanjan with stanya in Netra shoola and shotha.

12)" Sandhava Yoga " Anjanas are explained in Akshi shoola shotha and paka etc.

13) Shunti + stanya and grinded with cow ghee for anjana in shuskakshi paka .

14) Aanupa janthu Vasa + Shunthi + Saindhava Lavana is used as Anjana in Shuskakshi paka .

15) Hairs of human, dipped in the ghee, and burnt in " mallaka samputa " grind with the cow ghee for anjana inshuskakshi paka .

16) Go dadhi is pasted to silver vessel, after drying properly it is collected and grinded with dadhimastu, varthi is prepared, and is used for anjanaa in vataja Abhishyanda .

17) Jathi puspa, shankha, Triphala, Yastimadu, Bala - Grinded with Aakshodak and used as varthi anjana in pittaja Abhisyanda.

18) Saindhavalavana, Triphala, Trikatu, shankha, Samudra phena, shilajith sarja rasa, grinded and used as Varthi anjana in Kaphaj abhisyanda.

19) Go shakruth rasa, Go ksheera, Go ghritha (pakwam) and is used as Rasa Krianjan, in Dhooma darshi.

20) Karanja, Neelothphala swarasa, Gyrica, Kamalkesar, should be grinded with Gomaya ras and used as varthi anaja in Naktandya.

21) Renuka, Pippali, Sauveeranjan, Saindhava, lavan should be grinded with Aja mootra and used as varthi anjan in Naktandya.

22) Triphala, Trikatu, Haritala, Manashila, Samudra phena - should be grinded with Aja ksheera and used as varthi anjan in naktandya.

23) Rasanjan, Gyrica, Talisa patra, Go maya rasa ,madhu ,Go ghritha, grinded and used as rasa Krianjan in Naktandya.

24) Maricha rubbed in dadhi, the essence is used as anjan in Naktandya.

25) Guda, samudra phena, sauveeranjan, pippali, maricha, Kumkuma it is powdered and used as anjana with madhu in kacha.

26) Pippali, saindhava lavana, coocked in usheera kashaya, Go ghritha, Hoeny added, Rasa Kriya is prepared and used for anjana in sannipathaja Timira.

27) Rakthaja Timira Roga haranjan :-

Draksha, usheera, Lodra, Yastimadu, shankha, Tamra, chandana, kamala pushpa, padmaka, Neelothphala, grinded with avi ksheera and used as varthi anjana in Raktaj Timira .

28) The teeth and frotal bones of shasha, Go, khara, simha, ostra, and tail of white cow, maricha, shankha, chandana, samudra phena,. grinded with aja ksheera or stanya, used for varthi anjan in timira shukra.

29) Vimala Varthi :-

Shankha, priyangu, manahshila, Trikatu, Triphala, grinded and used as varthi anjan for vision improve ment .

30) Kokila varthi :-

Krishna loha raja, Trikatu, saindhava lavana, Triphala, sauveeranjan, grinded and used as varthi anjan. for vsion improvement.

31) Pittaja Timira hara Sauveeradyanjan :-

Sauveeranjan 5 parts, tuttha 5 parts, karkatak shrangi 3 parts, Amalaki 3 parts, karpura 1 part, powdered and used as choornanjan in pittaja Timira.

32) Pittaja Timira rogas hara Anjan :-

Sariba, padmaka, usheera, muktha, Lodra, chandan, used as varthi anjan or choorna anjan in pittaja Timira.

33) Pittaja Timira Roga hara anjan :-

Patra, Neelopthphala, sauveeranjan, Nagakesar, Karpoor, yastimadu, Gyrika, powdered and used as choorna anjan in pittaja Timira.

34) Vyaghra vasa or Varaha vasa + Yastimadu, powdered and used as choorna anjan in Timira.

35) Sauveeranjan should heat and dip in mamsarasa, ksheera, ghritha etc. powdered and used as choorna anjan in Timira .

36) Ratnadi choorna anjan :-

Ratna, Rajatha, spatika, swarna, sauveeranjan, Tamra, loha, shankha, chandana, kumkuma, Gyrika, powdered and used as choorna anjan for improovement of vision.

37) Shanmakshika Yoga :-

Maricha 1 part, Amalaki 2 parts, jalodbhava 3 parts, Tuttha 4 parts, sauveeranjan 5 parts, swarna makshika 6 parts, powdered and used as choorna anjana in Timira Arma jalasrava.

38) Akshabeejadi vati :-

Akshabeeja, maricha, Amalaki, Tuttha, yastimadu, should be grinded with water, used as varthi anjan in Timira.

39) Prathisaranjan :-

Maricha 10, Swarna makshika 1/2 karsha, Tuttha 1 phala , Yastimadu 1 karsha, dipped inghee and burnt, the bhasma is used for anjana in Timira.

40) Krishna sarpa vasa, shankha, kataka, sauveeranjan grinded and used as - Rasa kriyanjan in Timira .

41) Kukkutavistanjan :-

Cow milk is taken in a pot and added dead body of krishna sarpa and 5 scropians kept for 21 days. later on milk is chilled and cheese is collected that should be given to hen to eat after that the pureesha of the hen is collected for anjana in Timira.

42) Drusti shakthikaraanjan :-

Parada and Nagabhasma equally, double sauveeranjan, 1/16, karpoora, powdered and given as anjana.

43) Ghridhra mukha bhasma + Ghritha + Sauveeranjan powdered and used as choornanjan for vision improvement.

44) Ghritha, sauveeranjan, is kept in the mouth of krishna sarpa later collected and burnt perfectly + jata mamsi patra, the fine powder is given as anjana in savrana shukla.

45) Nagam (Lead) is melted and dipped 7 times each in Triphala kashaya, Bruangarajras, vatsanabhi Kashaya, Go ghritha, Aja ksheera, Yastimadu Kashaya. The shalaka (naga shalaka) is used as anjan shalka or the naga bhasma is used in the Timira, Arma etc.

46) Paashupatha Yoga in abhishyanda:- prapaundareeka, Yastimadu, Daruharidra, each 8 phala; 1 prasta water, boiled and concetrated decoction is prepared, then puspanjan 10 phala, maricha 1 karsha added and heated again - The powder or varthi is used for anjana in Abhishyanda and Drusti vikara.

47) Tutthanjan:- Tuttham is heated and dipped 7 times in the following liquids, the Gomutra, Gomaya rasa, kanji, stanya, Goghritha, vatsana, bhi madhu, then tuttam is powderd and used for anjana in Timira.

48) Timiranthaka Anjana :-

30 Parts naga bhasma, 5 parts Gandha pashana, Tamra and Talaka each 2 parts, vangam 1part and sauveeranjan 3 parts, mixed and well powdered for anjana in Timira.

49) Bhaskara Choorna :-

Tuttham is heated with the fire of badari sticks and dipped in Aja ksheera, Goghritha, madhu - each for 7 times, the purified Tuttam 2 phala, makshika, maricha, srotonjan, Katuki, Tagara, saindhava lavana, Lodra manahshila, Hareetaki pippali, Ela, sauveeranjan, Samudraphena each 1 karsha; Yastimadu 1 phala - burnt in a moosha, well powdered and used for anjana in Timira, Arma, Naktandya.

50) Drusti Prasadan anjan :- Sauveeranjan should be heated and dipped in the following decoctions each 7 times, Draksha swarasa ,Kamala mrunala swarsa. Goksheera, madyam, vasa ,Aakashodak. the medicine is powdered preserved and used for anjana inDrusti rogas.

51) Kaphaja Timira Haranjan :-

Maricha saindhavalavana pippali samudraphena each 2 parts, sauveeranjan 9 parts should be collected and powdered in chitta Nakshatra and used for anjana.

52) Timira Armadi roga haranjan :-

Jatamamsi, Trijathaka, Loha, Kumkuma, Neelothphala, Hareetaki, Tuttha, sita, kacha, shankha, Samudra phena, maricha, sauveerajan, pippali, Yastimmadu, (equally) wellpowdered and used use as anjan when Chandra enters in to Ashwini Nakshatra .

53) Timira roga hara choornanjan :-

Sauveeranjan 64 parts, Tamra, loha, Rajatha, swarna, each 1 part ; There are melted and dipped in madhuradi gana kashaya for each 7 times - These are powdered and added Vydoorya muktha, shankha bhasma, each 1 part well mixed and used as Anjana .

54) Asadya Shukra dosha haranjan :-

Narikelasti, Bhallatak, Tala pallava, Vamshi, burnt and mixed in water, well filtered then ostra asti choorna is added and is used for anjana.

55) Pundradyanjan in Shukra vyadhi :- pundra, yastimadu, Kakoli, simhee, Loha, (or Krishna agara) Haridra Rasanjan, should grind with Aja, ksheera, and fumigate with yava or amalatki partra which is dipped in ghritha, varthi is prepared and used for anjana .

56) Shukra hara anjan :-

The teeth of Go, khara, Ashwa, ostra, shankha, samudra phena, should grind with arjuna kashaya varthi is prepared and used for anjana.

57) Shukra roga haranjan :-

Langali kshara should dip in the amalaki phala swarasa and phaninjaka rasa, the fine powder is used for anjana.

58) Kathina shukra roga hara anjana :- Anjana is given with the shanka, kolasti, kataka, Draksha, Yastimadu and madhu .

59) Sura, Hastidantha, samudraphena, shireesha pushpa, the anjana is given in Kathina shukra.

60) Pippali, maricha, shireesha beeja, saindhava lavan, is used as choornanjan in Kathina shukra .

61) Saindhava lavan, got bhavan in Triphala Kashaya is used as anjana in Kathina shukra .

62) Maha neela gutikaanjan in shukra vyadhi :- (Bruhathi moola, Yastimadu, Tamra raja, saindhava lavana, shunthi, should be grinded with Aamalaki kashaya, pasted to coppervessel, fumigated with yava Aamalaki patra which is diped in ghee, the powder is collected, grinded with madhu and is used for anjana.

63) Sarva Shukra haranjan :-
Muktha etc ratnas, Dantha and shrunga of animals, gyrica etc Rasa Aushada, Trikatu, Ela, Karanja beeja, Lashuna, vrana hara Aushada etc are mixed, powdered and used as anjana.

64) Tamala Patradi Varthi :- Tamala patra, Go dantha, Shankha, samudra Phena, Gardabhaasti, Tamra etc are grinded with go mutra and Varthi prepared for anjana in shukra vyadhi.

65) Dantha Varthi : - The teeth of hasti varaha, ostra, Go, Ashwa Khara etc. Shankha, muktha, samudra phena, 1/4 maricha, varthi is prepared for anjan in shukra vyadhi.

66) Kshatha Shukrahara Varthi :-
jathi pushpa, Laksha, Gyrica, chandana, grinded and varthi is prepared for anjana.

67) Timira roga hara Lekhananjan :-
One drug of Triphala is burnt and masi prepared, with the Triphala decoctionof the masi is grinded, added saindhavaa lavana, Kachalavana well grinded and used for anjana.

68) Shuklarmadi rogahara anjan :- Sita, manahshila, Ela, lavan, shunthi, each 1/2 Karsha; Rasanjan 1/2 phala, should be grinded with madhu and used for anjana.

69) Kukonaka pthaki roga hara varthi :- Ela, Rasona, Kataka, shankha, maricha phaninjak, Katphala, should be grinded with sura and used for anjan.

70) Haridra, Daruharidra, Lodra, Yastimadu, Katuki, Nimba Pallava, Tamra raja, should be grinded with water and used for varthi anjan in Kukoonaka.

71) Loha raja should be heated dipped in ksheera madhu ghritha separately fine powder is prepared for anjana in Kukoonaka.

ANJANA FORM CHARAKA CHIKITSA

1) Saindava lavana and maricha 1/2 shana, pippali and Samudra phena 2 shana, sauveeranjan 1 shana should be collected and grinded in chitta Nakshatra and used for anjana in kacha, Netra kandu and Kaphaja netra diseases .

2) Bida lavana (Bida churna) should be grinded with Aja mootra (Goats unrine) for 3 days, then choorna anjana is given in Timira, Krimi and pilla roga.

3) Sauveeranjan, Tuttha, swarna makshik, manahshila, vana kuluttha, Yastimadu, loha bhasma, Ratna, pushpanjan, saindhava lavana, vana varaha damstra, kataka, powdered ans used as Choornanjan in Timira etc .

4) Sauveeranjan should kept in the mouth of Krishna sarpa for a month, it is removed dried powdered and added 1/2 quantity of jathi pushpa and saindhava lavana, perfectly grinded and used as choornanjan in Timira etc diseases .

5) Pippali, phalasha pushpa rasa, Krishna sarpa vasa, saindhava lavana, and grinded with old ghee and used for anjana.

6)) Krishna sarpa vasa, Madhu, Amalaki swarasa, grineded and used as Rasakriya anjana in Timira, kacha, Arbuda etc.

7) Amalaki, Rasanjan, Madhu, ghritha, grinded and used as Rasa Kiryanjan in pitta Raktha disroders and Timira .

8) Amalaki Saindhavan lavana pippali maricha and madhu used as Rasa Kriyanjan in timira.

9) Sukhavatee varthi.
Kataka, shankha, saindhava lavana, Trikatu, sita, (sugar) samudra phena, Rasanjan, madhu, vidanga, manahsila, kukkutanda twak grinded and used as vati Anjan in Timira etc diseases.

10) Drusti prada varthi :-
Triphala, Kukkutanda twak, Kaseesa, Loha bhasma, Neelothphala, vidanga, samudraphena, should be grinded with Aja ksheera in a copper vessel for 2 days and given as vati anjan in Timira.

ANJANAS FROM RASA RATNA SAMUCCHAYA.

1) Tamra druthi + madhu or ghritha or stanya used as anjana, in Timira Arma, Abhishyanda .

2) Gandaka druthi + madhu or ghritha or stanya used as anjana.

3) Shuklari varthi :- Shambuka, parada, naga, Kamsya Rasanjan bhasma, should be grinded in a copper vessel with chincha patra srarasa-varthi is prepared and anjana given with madhu, in Timira, shuklarma,pilla vyadhi etc

4) Nava netra dhatree varthi :-Tamra bhasma 16 parts, Yastimadu choorna 14 parts, kusta choorna 12 parts, vacha choorna 10 parts, Rajatha bhasma 4 parts, swarna bhasma 2 parts, saindhava lavana 8 parts , pippali choorna 6 parts, should be grinded with Aja ksheera for 3 days and collected in copper vessel - it is used as anjana in Abhishyanda, Adhimantha, savrana shukla, Timira etc.

5) Nayana rogahara Varthi :- Pippali 1/4 tula, saindhava lavana 1/2 tula, vacha churna 1 tula, Yastimadu 2 tula (Sthalaja) Jalaja Yastimadu 4 tula, tamra bhasma 8 Tula, should be grinded with aja ksheera for 3 days, varthi anjana is given with madhu in most of the eye diseases.

6) Shigru tailam+Karpoora used as Anjana in Timira, Arma and savrana shukla.

7) Swarnadi Varthi :-
Swarna, varata, rasa, should be grinded with putikaranja patra swarasa and varthi anjana is given with navaneeta in Timira and Arma.

8) Vishaadyanjan :-
Vatsanabhi, Shahkhanabhi (1:1) should be grinded with Amalaki rasa for a day and used as anjana in Timira .

9) Pushpaharanjan :-
shankha, varata, the masi is used as anjan with navaneeta in shukra

10) Nru Kaphalanjan :-
Human skull bhasma is given as anjana with stanya in Timira.

11) Kacha Andya haranjan :- Vatsanabhi choorna, manahshila (1:1) grinded with madhiphala rasa and used as anjana at nights in Kacha and Andhatha

12) Shadanga Varthi :-
Karpoora, Rasanjan, Naga bhasma, parada bhasma, pippali churna, loha bhasma, (equally) grinded with nandyaavartha Pushpa rasa for 3 days, Anjana is given with madhu in Timira arma shukla etc.

13) Dwadashanga Varthi ;-
Tamra bhasma, Tuttha, Tankan, Rasanjan, Triphala, Trikatu, Samudra phena, shankha, grinded with lemon juice for 3 days, varthi anjana is used with madhu in Timira, Kacha, Arma, shukra.

14) Patala haranjan :-
Sootha bhasma or Rasa sindhura, should be grinded with Laksha paste of Tankan + Aja ksheera and preserved in the Dhaanya Rasi for 1 month then the medicine along with Kaphardika is powdered and anjana is given with Honey or ghee in Timira.

15) Paradadi Varthi :-
Parada, Naga bhasma, Rasanjan, Loha bhasma, mudga moola choorna , sarjaras (equally) should be grinded with chincha patra swarasa for 7 days, preserved for one day in a copper vessel - Anjana is applied with madhu in Timira, Adimantha, shukra, Arma etc.

16) Eeka Trishanga varthi :-
Parada, naga bhasma, Rasanjan, Pravala Kaseesa, lodra, Tamra bhasma, Renuka, Trikkatu, Gyrika saindhava lavana, Tutta, Samudra phena, Triphala, Mukta bhasma, peetha Rohini Choorna, Babula patra choorna, visnukrantha choorna, putranjeeva choorna, dathura moola churna, chincha, patra choora, shat lavan (Pamshulavana, bidalavan Sauvarch lavan, Kachalavan, Samudra lavan, saindhavlavan,) should be grinded with Nimba patra rasa for 3 days, varthi anjan is given with madhu.

17) Garudanjan :-
Kataka, saindhava lavana, Tuttha, Rasanjan, Trikatu, spatica, musta, varata, Trilavan, Tamra bhasma, loha bhasma, Karpoora, Katuki. samudra phena, vacha, Nruka rotika, Naga bhasma, parada, Tankan, Neelanjan, Triphala, Yastimadu, should be grinded with Karanja Twak Kashaya for 7 days - Varthi anjana is given with water in visual problems.

18) Timira haranjan :-
Parada 1 part, Naga bhasma 1 part, Neelanjan 2 parts, Karpoora 1/4 part, grinded and applied as anjana in Timira.

19) Nagadi Varthi :-
Naga bhasma, parada, Amlaki, Karpoora, Mouktika, Goghritha, pippali, Saindhava lavan, Rasanjan, Jeeraka, Madhu - Should be grinded with Nagavalli Patra swarasa in (Kamsya paatra) Coppper vessel - vati anjan is given with Honey in Abhishyanda, Adhi mantha etc diseases.

20) Tamradi Varthi :

Tamra bhasma, Nagabhasma, Rajatha Bhasma, Parada, peetha Rohini, Karpoora, pippali, Rasanjan, Saindhava lavan, shankha bhasma, Kamshya bhasma, should be grinded with Hamsa padi moola swarasa- Varti anjan is given in Most of the eye diseases.

21) Raktanjan :-

Rakta chandan, choorna collected in a coppervessel - 100 Bhavana and 100 mardana should be given in Bringaraj rasa and anjana is given with madhu.

22) Timira haranjan :-

Gandak 1 Part, parada 2 parts, Sauveeranjan 1/8 part, should be grinded with kapittha rasa for anjana in timira.

CHAKRADATTA - ANJANA YOGA.

1) Sukhavathi varthi :-

Kataka, shankha, Trikatu, Lavan, Samudra phena, Rasanjan, Vidanga, manahshila, Kukkutanda twak, should be grinded with water varthi anjana is given with madhu in Timira, kacha, Arma, shukra.

2) Chandrodaya Varthi :-

Hareetak, Vibheetak, pippali, maricha, vacha, kusta, Nabhi Manahshila, should be grinded with Aja ksheera and used as varthi anjan in Timira, Kacha, Arma, Naktandya.

3) Hareetakyadi Varthi :-

Hareetaki, Haridra each 2 parts ; Pippali 1 part, Lavana 1/4 part, grineded and used As varthi anjan in Timira.

ANJANA YOGA FROM BASVA RAJEEYA (TELUGU BOOK)

1) Trikatukaadyanjan :-

Trikatu, Triphala, jyothishmati, vidanga, Karanja - each 4 part ; prapoundareeka, Yastimadu, Tamra basma, Saindhava lavana, spatika shankah, each 3 parts ; Rasanjan Gyrika, chandana dwayam, Draksha, Haridra, Swetha Lodra - each 2 parts ; Tutta, Daruharidra, Katuki, - each 1 part ; should be grinded with Karanja swarasa, vati should be prepared and is used as anjan with water - in Timira, Adimantha, Arma, shukra and Naktandya.

2) Katakaadyanjan :-

Kataka beeja, shankha, saindhava lavana, Trikatu, sharkara, samudra phena, Rasanjan, Madhu, vidanga, manahshila, kukkutanda twak, should be grinded with stanya and used as anjana with lemon juice, it is useful in Timira, varthma roga, Abhishyanda and Arma.

3) Garudanjan :-

Ela, Maricha, Tuttha, Saindhava lavan, samudra phena, spatic, Hingula, shankha, chandana, kusta, Laksha, haridra, Kukkudanda twak, skull of the human, manahsila, kataka, karpoora, Devadaru, Rasanjan, Guggulu and should grind spearately with Bringaraj swaras, Aja ksheera, matsyakshi patra swarasa, swetha Kamala swarasa, Neeli swarasa, punarnav swarasa and vati is prepared for anjana with water in Timira, Dhoomadarshi and Andhatwa.

4) Maha Garudanjan :-

Kathak, saindhava lavan, Tutta, Trikatu, spatika, shankha, Kaphardhika, Rasanjan, Manahsila, Tamra bhasma, Loha bhasma, Karpoora, katuki, Samudraphena, vacha, skull of human, Naga bhasma, Rasa bhasma Tankan, sauveeranjan, Triphala, Yastimadu, Gorochan, should be grinded with Karanja swarasa and the preared vati is used for anjan with water in Andhatwa Timira.

5) Nayanamrutam :-

Karpoora, Sauveeranjan, Tutta, Rasanjan, Daruharidra, katuki, Kaphardika, Saindhavalavana, Trikatu, Samudra phena, Yastimadu, Chandan, Shankha, should be grinded with mathulunga swarara and prepared vati is used for anjan with Honey or in all types of eye diseases.

6) Rasa Krianjan :-

Rasa bhasma, praval bhasma, Nagabhasma, kaseesa, Rasanjan, Saindhava lavan, Trikatu, Tamra bhasma, Tutta, Gyrika, Lodra, putranjeevi seeds, manahshila, musta, shireesha beeja, Abhaya, Chinchabeeja, sauveeranjan - should be grinded with Nimba patra swarasa in a copper vessel and anjan is given with Honey. in Timira, Arma, etc diseases.

7) Netranjan :-

Pippali, Sauveeranjan, Karpoora, Nagabhasma, Rasa bhasma, Loha bhasma, vatsanabhi should be grinded with Nandyaavarth rasa in a Iron vessel for a day and vati anjan is given .

8) Tamradyanjan :- Tamra bhasma, Dhanyabhraka, Tuttha, Kaphari each 10 Nishka, the powder should heat in a pan with 30 karsha gandhaka, by closing the pan with same sized pan to prevent the medicated vapours not to escape out. After formation of perfect mixture the medicine should be coolled then it is diluted in 1 prasta of water, the pure solution is kept in the heat of sun to make the liquid concentrate, then 1karsh Tutta and shilajith powder is added vati is prepared for anjan with madhu or ghritha and is used in most of the eye diseases.

9) Rasanjanadyanjan :- Ativisha, pippali - grinded in Gomutra, vati is prepared for anjana in Timira. Samudra phena, spatica, Hingula, Rasanjan, Kacchapa Prusta Asti, manahsila, Trikatu, (double to manahshila), saindhava lavan (double to Trikatu,) Loha bhasma (equal to saindheva lavana,) Ati visha (equal to lohe bhasma) grinded welll and anjana is given with Honey or ghee in Timira and Arma.

10) Saindhavadyanjan :- Saindhava lavan, Rasa bhasma Nagabhasma, Amalaki, Rasanjan, Pippali etc should be collected in a copper vessel and grinded with ghee, honey, Nagavalli swarasa and sugar, vati is prepared and used for anjana .

11) Tarakadya vati Or Taranjan :- Rajatha bhasma, Tamra bhas, Rasa bhasma, Tuttha, Khapari, Daruharidra, Kakuti, Rasanjan, kamsya bhasma, shankha should be grinded with Hamsapada patra swarasa and vati prepared for anjana.

Gaja kesari :- Manahshila, naga bhasma Tuttha, (Dobule to naga) slight karpoora, should be grinded with dronapushapa ras and vati prepared for anjan.

12) Chandrakaanjan :- Tuttha, Tamra bhasma, Loha bhasma, yastimadu, vacha, palatutta, lavanga, saindhava lavan, Shankha, Tritaku, vidanga, Rasa bhasma, Kataka, Daruharidra, Vata, Amalaki, Talaka, Karanja beeja, Neelanjan and Should be grinded with Nimba swarasa, matulunga swarasa to prepare vati for anjana .

13) Spatika, lodra, Rasanjan, Tagara ,Tuttha ,Naga bhasma, Kaphari, saindhava lavana, Karanja beeja, Yastimmadu, Trikatu, vidanga, Hareetaki, and Should be grinded with Bringaraj rasa - Mathulunga ras to prepare vati for anjan .

14) Kataka, Manhshila, Amalaki, Kshèeratutta ,Hingula, Yastimadu, lodra, Talaka, sauveera, Trikatu, Karanja dwayam, Devadaru, Daru haridra, maricha, spatika, swetha kamala, shankha, Tamra bhasma, Naga bhasma, Abraka bhasma, Kantha loha bhasma, Raktha manahshila, pippali, lavana, samudra phena, Gyrika and shoulded be grinded with vata, shunthi, bringaraj rasa to prepare vati for anjana with Honey or ghee in Timira and Netra srava.

14) Nayanaamrutam :- Tuttha, saindhava lavan, Ksheera tuttha, samudra phena, Rasanjan, Tankan, maricha, should be grinded with lemon juice in a copper vessel for 3 days to prepare anjana in Arma and Timira.

16) Karparyadyanjan :- Kaphari, Tuttha, Rasanjan, Samudra phena, shankha manahshila, punarnava, Triphala, and should be grinded with lemon juice to prepare vati for anjan with water in Timira Arma.

17) Tila Pushpanjan :- Maricha 2 parts, Kaphari 4 parts, Tila pashpa 8 parts, and shoulded be grinded with lemonjuice to prepare vati for anjan in Timira Arma.

18) Marichanjan :- Maricha 1 part, Amalaki 2 parts, Karanja beeja 3 parts, should be grinded with Bringaraj swarasa and vati prepared for anjan in Timira etc.

19) Netra Prabhanjan :-Samudra phena, Loha bhasma, Kataka, skull of human, Kukkutanda twak, manahshila and should be grinded with jeerakaKashaya for vati anjan in Timira

20) Chandro daya Varthi :- Haridra, Nimba pallava, pippali, maricha, vibheetaki, Karanja beeja, shankha, vatsanabhi, manahshilla, should be grinded with Aja, pureesha for vati anjana with water in Arma and Timira.

21) Darvyadyanjan :- Application of Rasanjan in Arjuna, Arma, and Timira

22) Girikarnikanjan :- Swetha Girikarni root, seeds and flowers, shankha, Haridra, Hareetaki, shunthi, shouid be grinded with girikarni moola rasa and applied as varthianjan.

23) Kumarika vari :-80 tila pushpa, maricha 16, Jathi pushpa 50, pippali 60 used as Vati anjan.

24) Shiladyanjan :- Manahshila, pippali, Karpoora, Tinthinee phala, Karanja beeja, should be grinded with water for Varthi anjan in Timira.

25) Narikelanjan :-

Triphala, Daruharidra, Yastimadu each 1 phala, (Triphala 3 phala); add Narikela jala and the decoction is prepared then Karpoora, saindhava lavana and madhu added for anjana. in Timira Arma.

;) Maha Narikelanjan :-
Yastimadu, Triphala, Darauharidra each 1 phala ; 1 prasta narikela jala, added 1/8 Residual decoction; prepared and Tuttha, karpoora, samudra phena, Gyrika, saindhava lavan, Rasanjan, Maricha, and madhu added for Anjana.

21) Shankhadi Vatika anjana :-
Shankha 4 parts, manahshila 2 parts, maricha 1 part saindhava lavan 5 parts, should be grinded with Aja ksheera and used as Anjana in Timira Naktandya.

28) Pushpanjan :-
Manijista, Yastimadu, uthphala, Dadhi, pippali twak, chavya, Gorochan, jatamamsi. chandana, shankha, kangiri, Tuttha, pushpanjan, is used in Netra srava Abhishyanda shukra and Netra shoola.

29) Godanthadyanjan :-
Go dantha, Kukkutanda twak, makara dantha, shankha choorna, varata churna, samudra phena, Tamra churna, Tuttha, Karpoor, Rasna, chandra kanth Ratna, Madhucchista - all should be grinded and heated, then anjan is used with lemon juice in Timira Arma, Arjuna etc.

30) Dhatranjan :-
Triphala should be grinded with lemon juice and is used as Anjan in Netra srava and Timira .

31) Uthphaladyanjan :-
Uthphala, saindhavalavan, chandan, Triphala, should be grinded with Lemon juice and is used as anjan in Timira Naktandya.

32) Artha Chandrodaya Anjan :-
Karpoora, spatika, shankha, chandana, Yastimadu, Madhuka, sariba, Manjista, Haridra, Daruharidra, Kataka beeja, Gyrika, in equal quantity and add equally purfied Tuttha and grinded with lemon juice and is used for anjana in Timira, Naktandya, Varthma roga.

ANJANA YOGAS FROM NETRA DARPAN

1) Laakshaanjan :-
Laksha, Daruharidra, Rakta manashila, vidanga, and gyrika, should be grinded with stanya in Abhishyanda - netra srava .

2) Akshanjan :-
Tuttha, Yastimadu, Amalaki, vidbheetaki and maricha grinded with water for anjana in Timira.

3) Sudarshananjan :-
Chandana, manahshila, saindhava lavan, Haritala, shankha, Yastimadu, maricha and spatica, grinded with water for anjanan in Timira and shukra .

4) Shastra Vallabhaanjan :-
Shankha, Shigrubeeja, Saindhava lavan, Kukkutanda twak, samudraphena, grinded with water for Anjana with shigru pushpa rasa. in Timira shukra.

5) Aamalakaanjan :-
Aamalaki, maricha, karanja beeja, grinded with Bringaraj swarasa for anjana in Timira, kamala etc.

6) Shankhanjan :-
Saindhava lavana 1 part, maricha 2 parts, manashila 4 parts shankha 8 parts should be grinded with aja ksheera, for anjana in Timira Arma etc.

7) Shashi Prabhaanjan :-
80 Tila pushpa, 50 Jathi pushpa, 16 maricha and 6 pippali - anjana is given in Timira.

8) Spatikaanjan :-
Spatika, Lodra, Trikatu, Rasanjan, Ksheera tutta, Saindhava lavan, Tuttha, Yastimadu, vidanga, Karanja beeja, Hareetaki, Vanga bhasma, Naga bhasma, grinded with Lemon Juice or Bringaraj swarasa for anjana in Timira Arma.

9) Amrutaanjan :-
Karpoora, samudraphena, vatsanabhi, Tuttha, Yastimadu, Katuki, chandan, Daruharidra, Trikatu, Kaphardik bhasma, Neelanjan, Garudanjan, grinded with madiphala ras for vati anjana with Honey or Ghee.

10) Bhujangaanjan :-
Naga bhasma, Manahshila 1 part; Tuttha 2 parts.
Slightly Karpoora - grinded with Dronipashpa swarasa for anjana.

Tutthaanjan :-
Tuttha, vata, Yastimadu, shankha, Daruharidra, Trikatu, Karanja beeja, Gandak ,Talaka, parada, Vidanga, Ksheera tuttha, Kataka, Amalaki, Tamra and Loha bhasma - grinded with madiphala rasa for vati anjan.

Nishaanjan :-
Vacha, maricha, Daruharidra, Pippali, Saindhava lavana, grinded with Bringaraj swarasa, for anjana

Laghu marichaanjan :-
Maricha grinded with Bile of black goat and used for vati anjan.

Tamraanjan -
Tamra bhasma, Hareetaki masi, bhallatak beeja masi, grinded with Navaeetha in a copper vessel and used as anjan .

Rajathanjan :-
Rajatha bhasma, Varaha shrunga, Gaja nakha, Kukkata Gala asti, grinded with Honey for anjan

Trikatukaanjan :-
Trikatu, Triphala, grinded with Aja pureesha for anjana.

ANJANA YOGA FROM BHAISHAJYA RATNAVALI

1) Nishadi Netra bindu :-
Haridra, musta, Hareetaki, vibheetaki, Amalaki, Daru haridra, sharkara, yastimadu, Draksha - Devadaru, (equally), 64 times water is added and arka extracted for Aashchyotan in Abhishyanda - netra shoola, daha etc.

2) Chandra prabha Varthi :-
Swetha maricha, Krishnanjan, Pippali, Yastimadu, shankhanabhi, manahshila, Hareetaki, grinded with Aja ksheera for varthi anjan. in Timira, Arma, Nakthandya etc.

3) Haridra varthi :-
Haridra, Nimba pallava, maricha, shunthi, methi, vidanga, grinded with Gomutra for varthi anjana in timira Nakthandya etc.

4) Vyoshadi Varthi :-
Trikatu, Kamala, Hareetaki, Kusta, Daru haridra used as varthi anjan in Timira arma etc.

5) Pippalyadi varthi :-
Pippali, Tagara, Kamala patra, Yastimadu, Haridra used as varthi anjan in Abhishyanda .

6) Pancha Shataka Varthi :-
1) Neela Kamal patra 100 parts 2) Mudga 100 parts 3) Nistusha Yava 100 parts 4) malathi pushapa 100 parts 5) Pippali 100 parts - varthi anjan should be given with ghritha in Timira Ashruasrava etc diseases.

7) Drustiprada varthi :-
Triphala, Kukkudanda twak, Kaseesa, Loha bhasma, Neela Kamal, vidanga samudra phena, grinded with Aja Ksheera in a copper vessel for 7 days and used as varthi anjan in Blindness.

8) Kokila Varthi :-
Trikatu, Loha churna, saindhava Lavana, Triphala, anjana, used as varthi anjan in Timira.

9) Bruhath Chandrodaya varthi :-
Rasnajan, sukshma ela, Kumkuma, manahsila, Shankhanabhi, shigru beeja, sharkara used as varthi anjan, in Timira.

ANJANA YOGA FROM SARANGDHAR SAMHITHA

1) Karanja Varthi :-
Karanja beeja + phalasha pashpa swarasa used as varthi anjan.

2) Samudra phenadi Varthi :-
Samudra phena, saindhava lavan, shankha, Kukkatanda twak, Shigru beeja, used as varthi anjan in shukra vyadhi.

3) Dantha Varthi :-
Animals teeth, shankha, muktha, Samudra phena, used as varthi anjan in Shukra vyadhi.

4) Atinidranashini Varthi :-
Neelothphala, shigrubeeja, Nagakesar, used as varthi anjan in Atinidra

5) Pushpa Varthi :-

Tila pushpa 80, pippali beeja 60, jathi pushpa 50, maricha 16 - grinded with water varthi prepared and used for anjana in Timira shukra etc.

6) Naktandyanashini Varthi :-

Rasanjan, Haridra, Daruharidra, Jathi pushpa, Nimba patra, - grinded with Gomaya ras Varthi is prepared and used for anjana in Naktandya.

7) NetraSravahara Varthi :-

Triphala majja + Water used as varthi anjan in Netra Srava

8) Tutthadi rasa Kriya :-

Tuttha, swarna makshika, saindhava lavana, shankha, manahsila, sugar, Gyrica samudra phena, maricha. The fine powder + madhu - given as anjan in Timira shukra etc .

9) Karpooranjan (Pushpahara Rasakriya)

Karpoora choorna + Vata Ksheera used as anjan in Shukra.

10) Atinidraaghna Anjan :-

Maricha got bhavana in Ashwa lala srava + madhu - powdered and anjana given to control sleep.

11) Tandraghna anjan :-

Jathipushpa, pravala, maricha kataka, vacha, saindhava lavan, - grinded with Aja mutra and anjana given to control yawnings.

12) Daarvyadi Rasanjan :-

Daruharidra, patola, Yastimadu, Nimba, padmakaasta, Neelothphala, prapoundareeka, rasa Kriya prepared and used for anjana in Daha raga paka srava Raktaadikya and shoola of eye.

13) Rasanjanadi Rasa kriya :-

Rasanjan, Sarja ras, Jathi pushpa, Manahshila, Samudra phena, saindhava lavan, Gyrica, maricha. grinded with Honey and used as anjana in praklinna varthm .

14) Guduchi rasakriya :-

Guduchi Swarasa 12 grams, madhu 1 gram, saindhava lavan 1 gram - Rasa kriya anjan is used in Timira shukra etc.

15) Punar nava rasakrianjan

Punarnava	+	milk	in	Netra kanda
"	+	madhu	in	Netra srava
"	+	Ghritha	in	Shukra
"	+	Taila	in	Timira
"	+	Kanji	in	Naktandya

16) Babboola patra Rasa Kiryanjan with madu in Netra srava.

17) Ghritha + Madhu as anjan - in sirothpatha .

18) Krishna Sarpa vasa, shankha, Kathaka, and Rasanjan, the prepared rasa Kri yanjan is used in Blindness.

19) Saindhava lavana, maricha, each 1/2 part; pippali - samudra phena, sauveeranjan, each 1 part ; choorna anjana is given in Kandu, Kacha.

20) Sauveera Choornanjan (Bhavana in Triphala Kashaya) is used in most of the eye diseases.

21) The pippali of yakruth pippali yoga (Pakwa) + madhu as anjan in Nakthandya .

22) Kukkutanda twak, manahshila, kacha, shankha, chandan, saindhava lavana, grinded in water for anjan in Arma disease.

23) Nayanamrutanjan :-
Melted Naga + Parada + Krishnanjan (equalaly) + 1/10 Karpoora - well grinded and used for anjana in most of the eye diseases.

24) Sarpa Visha hara anjan :-
Jayapal beeja majja - grinded (Bhavan) in Lemon juice for 21 times and varthi is prepared and used as anjan with saliva of human, it is useful in snake bites.

26) Kataka phala - grinded in water and Honey, Karpoora is added, pefectly mixed and used as anjan for netra Prasadan.

EXAMINATION OF EYE BALL

Eye ball is an important sensory organ for visual perception, a simple mistake may cause blindness so only while handling diagnosis and treatment of ophthalmic case definite principles should be followed.

The examination of eye ball chiefly contain 3 headings.

1) History taking :- the detailed, present, past history and family history, some times give a clue for the diagnosis.

2) Objective examination :-

a) Examination of the appendages and anterior segment of the eye ball (eyelids, lacrimal gland, Lacrimal apparatus, conjunctiva, cornea, sclera, Anterior chamber, Iris, pupil and Lens)

b) Examination of posterior segment of eye ball with ophthalmo scope ex :- vitreous, retina, choroid, optic, disc etc.

c) Examination of eye ball with special optical instruments like corneal micro scope, slit lamp, gonioscope, Transilluminator etc.

3) FUNCTIONAL EXAMINATION OF EYE BALL

Recording or estimating of function of eyes separately.

a) Acuity of vision :-

Both the distant and near vision are tested, Distant vision is recorded with snellen's chart and Near vision is recorded with jaeger's test types etc.

b) Colour vision test :-

Test of colour vision is essential for certain occupations such as sailors, Railway engine driver etc. This can be tested by various methods but the most common method is by means of Isihara chart.

c) Field of Vision :-

The Examination of Central field and peripheral field of vision is essential. Central field is estimated by Bjerrum's screen and peripheral field of vision is estimated by perimeter.

A) HISTORY TAKING :-

History taking is extremely important, the patient should be encouraged to narrate his complaints, enquiry should be made about certain complaints and definite questions are put as indicated below .

1) Age sex occupation and address should be asked, it is help ful for the diagnosis.

Ex :- a) After 40 yrs of age some diseases comes like senile cataract, presbyopia and also retinopathies.
b) Styes & meibomian cyst are common in the young
c) Styes & allegic blepharitis common in the female (Allergy due to Anjana)
d) Visual problems, corneal opacties etc are common in welders and in the labour working in chemical factories.
e) Xerosis and vitamin deficiences are common in the poor.

2) cheif complaints, aasociated complaints, previous illness, Family history, personal history etc should be asked indetail to assess the disease and to put furthur relavent questions.

3) Questions in relation to vision :-

a) Mode of onset of the disease whether gradual or sudden.
b) Duration of the disease whether fresh or chronic
c) Whether it is primary or secondary.
d) Before the visual problems if any head injury happened or not.
e) Whether it is uniocular or Binocular.
f) Whether visual problem is constantly present or getting occasionally.
g) Dim vision whether in day time (Hemeralopia) or at nights (Nyctalopia)
h) Any glasses (Spectacles) used before.
i) Any double vision (Diplopia), or multi vision (Polyopia)
j) Any haloes around the light (Commonly seen in Acute or sub accute conjunctivitis, closed angle glaucoma and in Lenticular opacities)
k) Any spots or floating objects seen infront of eye (in Aqueous precipitations, Keratic precipitates and in Vitreous haemorrhages)
l) Any distortion of objects (known as Metamorphopsia, seen in choroiditis and retiinitis)

m) Whether objects appearing smaller than the normal (known as microp-
sia, seen in choroiditis and retinitis)

n) Whether objects appearing bigger than the normal (Known as macropsia,
seen in Choroiditis and Retinitis)

o) Any subjective flashes of light are seen (Known as photopsia, seen in
choroiditis due to retinal irritation)

p) Whether defective vision present in central field or in peripheral field or for
colour things.

q) If colour blindness present that is unlocular or Binocular . Whether total or
partial If only one colour factor seen among the 3 colours (Red green blue) in
known as **monochromics** If two colour factors are seen among the three it is
known as **dichromics (Protanopes** - red blind, **deuteranopes** - green blind,
Tritanopes- Blue blind)

r) Whether difficulty in vision for distant objects (myopia), or near objects
(Hyper metropia)

s) Whether having the habbit of Tobacco, alcohol and any other toxic things
(Produce amblyopia)

t) Any eye strain, head ache, red eyes while reading sewing etc.

4) Questions with regard pain in the eye ball.
   a) Mode of onset b) Duration
   c) Mild moderate or severe
   d) Time of the day when worse
   e) Relation to close work
   f) Any associated nausea vomiting giddiness and fall of vision.

5) Head ache :-
   a) Location b) whether the site of pain is fixed or altering
   c) Time of the day when worse d) Mild or moderate or severe
   e) Whether constant, interupted or intermittent
   f) Frequency of the pain.
   g) Relation to close work.
   h) Any associated nausea vomiting giddiness or fall of vision.

6) Watering of the eyes :-
   a) Duration
   b) Constant or intermittent
   c) Relation to close work, travelling on in fast vehicles, after cinema show, after reading or sewing, after seeing bright things etc.
   d) Any associated redness
   e) Time of the day when worse
   f) Any lesion in lacrimal apparatus (catarrhal dacrocystitis)
   g) Stenosis or Obstruction in puncta (epiphora)
   h) excessive stimulation of Lacrimal gland (Lacrimation) .

7) Discharge of the eyes :-
   a)Nature of the discharge whether mucoid, muco purulent or purulent.
   b) Onset.
   c) duration.
   d) Any stickiness of lids or margins in the mornings on waking (in conjunctival lesions and lesions of Lacrimal apparatus this condition is seen.).

8) With regard to glasses (Spectacles)
   a) Has the patient worn the glasses, is so for what pupose and the glasses relieved the symptoms or not.

9) Photophobia (dislike for light) present or not .

10) History of injury :-
   a) Direct or indirect (penetrating types of foreign bodies) b) Whether dimvision started after the injury c) whether the dim vision agravated after the injury

11) Past history :-
a) Past history of the diseases, Hypertension, diabetes, Tuberculosis syphilis, leprosy, thyroid dysfunction, general debility etc.

b) Past medical and sugical history should also enquired for the proper diagnosis.

12) While the answering of the patient, the Doctor should observe for the ptosis, proptosis, screwing up of the eye ball, axis of the eye ball, watering, palpebral fissure, head posture etc.

OBJECTIVE EXAMINATION

B) Examination of the head, for its.
a) Configuration b) its position. ie. head tilt or head turn.

C) Examination of the face,
a) Any asymetry b) Signs of paralysis c) skin changes

D) Examination of eye brows, for
a) Loss of hair b) Depigmentation
c) Any elevation from hyperaction of frontalis muscle.

E) Examination of palpebral fissure
(The wide gap between upper and lower lid margins when the eyes are opened.)
a) Normal b) Wide c) Narrow d) Absent.

F) Examination of orbit for
a) Deformity b) Fullness in any part etc.

G) Examination for the position of eye ball in the orbit for the following
a) Smaller eye ball (microphthalmos)
b) Bigger eye ball (Buphthalmos)
c) shrinken eye ball (Phthisis bulbi)
d) Sunken eye ball (Enophthalmos)
f) Protruded eye ball (Exophthalmos)
g) Deviated axis of eye (Squint or strabismus)
h) Oscillating or pulsating eye ball (nystagmus)
i) Congestion or discolouration should also be noted.
k)

EXAMINATION OF EYE LASHES (PAKSHMA)

In general the colour of the eye lashes cannot become grey or white (Depigmentation of eye lashes). Normal eye lashes are fresh regular soft blackish and arranged in 2 or 3 rows, the upper eye lashes project forward and upward, lower eye lashes project forward and slight down wards. These prevent the entry of foreign bodies into the eye.

Eye lashes should be examined for the following :-
1) Absence of eye lashes is known as madarosis (pakshma shatha)
a) Partial or total absence, b) Congenital or acquired should be noted.

2) Irregular hard and misdirected eye lashes, is known as trichiasis (pakshma kopa)

3) Irregular misdirected eye lashes if congenitally present is known as distichiasis.

4) Depigmentation (grey or white) of hair is known as vitiligo (very rare)

5) eye lashes should be examined for nits parasites at its root.

6) Any matting of eye lashes with conjunctival sticky discharge should be noted.

7) Any cracking of the lashes should be noted.

EXAMINATION OF EYE LID MARGIN
(PAKSHMA VARTHMA SANDHI)

The lid margins should be normal in thickness, colour and in position (without in-rolling or outrolling.)

1) Inflammation of eye lid margin is known as Blepharitis (Krimi grandhi) " The lid margin appears with ulcers, crusts, scales etc. "

2) Thickening of eye lid margin is known as Tylosis .

3) Hyperaemia of eye lid margin is known as milphosis.

4) Inversion (in rolling) of lid margin or is known as entropion (it causes scratches or ulcers on cornea due to constant pricking of eye lashes).

5) Eversion (out rolling) of eye lid margin is known as Ectropion (Due to evertion of lid margin, eye lids cannot closed perfectly, so cause exposure keratitis etc).

6) Small cystic swellings develops at the root of the eye lashes (on the lid margin) due to the obstruction in the channels of zeis gland, it is known as zeis cyst or stye or External hordeolum.

7) Puncta should be examination whether it is stenosed, obstructed closed or everted (puncta is a hole present on the eye lid margin at the inner canthas, through which lacrimal fluid enters into lacrimal apparatus and inferior meatus of nose 1) if puncta is closed causes epiphora (watering of eyes) 2) and in dacryocystitis, by pressing over the sac area pus regurgitates out through the puncta)

8) Posterior sharp edge of lid margin should be examined for the series of white dots, they are the normal openings of meibomian glands.

EXAMINATION OF EYE LID PROPER

Eye lid is formed of the following layers. from out to inwards.

1) Skin 2) Loose aeriolar tissue (no fat) 3) Muscle layer 4) Tarsal plate 5) Palpebral Conjunctiva.

Note :- The Lesions of the skin and palpebral conjunctiva can be examined directly where as the other parts lesions are estimated functionally.

1) Examination of the skin of the eye lid.
   a) It is very thin, loose without subcutaneous fat so having more scope for oedema of eye lid due to trauma.
   b) Ulcers, scars, depigmented lesions, burns etc are examined.
   c) Trauma to eye lid may cause swelling and ecchymosis or Black eye lid
   d) Vertical wounds of eye lid may produce a notch on lid margin (Traumatic coloboma)

2) Applied Examination of muscles of eye lid.
   a) Facial nerve palsy causes Lagophthalmos (improper closure of eye lid) due to failure of the function of orbicularis oculi muscle.
   b) Oculomotor nerve Palsy causes ptosis (improper opening of eye lid or Droopping of eye lid) due to failure of the function of Levator palpebrae superioris muscle (a) and b) can be corelated to vata hatha varthma).
   c) Over action of muller's muscle (Supplied by cervical sympathetic nerves) causes vigorous blinking of eye lids. (Nimesha)

3) Examination of the glands of eye lid.

a) Zeis gland inflammatory condition is seen due to obstruction in its duct, by which a small cystic swelling is seen in the lid margin, is known as zeis cyst or External hordeolum or stye (Anjana namika - Kumbheeka) These commonly resolute naturally if not by pulling the affected eye lash or by giving a tiny Horizontal incision pus should be drained.

b) Meibomian glands

These present in the tarsal plate of eye lid, a cyst may form due to obstruction in the gland or its duct, is known as meibomian cyst or Tarsal cyst or chalazian (utsangini or lagana or Bahala varthma) . A cyst develops above the lid margin merely in the centre of the eye lid, swelling can be felt through the skin but its pus point, red ness and suppuration seen through the palpebral conjunctiva and for treatment Incission drainage is done by giving a small vertical incission on palpebral conjunctiva. (small cysts resolute naturally, suppurated cysts are treated by I/D, and hard cyst are treated by Excision.)

EXAMINATION OF CONJUNCTIVA

Conjunctiva is a thin smooth transparant serous layer that cover under surface (internal surface) of eye lids and Anterior part of (bulbar) conjunctiva. Different names are given to it according to it's site, they are as follows

1) Palpebral conjunctiva.

a) Marginal - The conjunctiva which is at the eye lid margin. **b)** Tarsal conjunctiva - the conjunctiva which covers Tarsal plate of eye lid.**c)** Orbital part - rest of the palpebral conjunctiva beyond the lid posteriorly .

2) Fornix :- It is the fold of conjunctiva formed by the reflexion of conjunctiva from eye lid to the eye ball.

3) Bulbar conjunctiva - the conjunctiva that covers the anterior part of sclera upto Limbus.

4) Limbal conjunctiva-it covers around the limbus (Sclero corneal junction).

5) Plica semilunaris- it is the crescentic fold of conjunctiva at the inner canthus which forms boundary for Lacrimal Lake to preserve the tears.

Note :- Marginal - Tarsal and Limbal conjunctiva firmly attached to the subjacent tissues but conjunctiva of fornix, orbital conjunctiva and Bulbar conjunctiva are lossely attached to the subjacent tissues.

1) Bulbar conjunctiva, Limbal conjunctiva, plica semi lunaris can be easily inspected because they present in palpebral fissure, and in the Horizontal meridian.
2) Lower palpebral conjunctiva and formix should be examined by pressing down the eye lid against the orbital bone.
3) Upper palpebral conjunctiva and fornix should be examined by everting the eye lid it is slight difficult than the others.
4) In general the following lesions should be detected in the conjunctiva.

a) Examination of the Fornix and palpebral conjunctival lesions:-

1) Hyperaemia (Red ness - due to increased vascularity followed by some lesion inflammatory or traumatic), **2)** Anaemia (loss of blood - pale conjunctiva) **3)** Follicles (Sand particles like eruptions, localised aggregation of lymphocytes in the sub epithelial adenoid layer of the conjunctiva), **4)** Papillae (Hyper trophic Folded epithelium with core of blood vessels by which conjunctiva appears velvety), **5)** True membrane formation as in diphtheria (un separatable layer if tried to separate causes bleeding), **6)** False membrane formation (Which can be easily separated from its base without bleeding), **7)** Foreign bodies, **8)** Cicatrical changes (contraction of the tissue due to scar tissue formation **9)** sub conjunctival haemorrages. **10)** Haemorrhagic lesions.**11)** Congestion **12)** Discharge (Watery mucoid, mucopurulent, purulent etc).**13)** Adhesions. **14)** Inflammatory changes (Conjunctivitis) **15)** Congenital lesions etc should be examined.

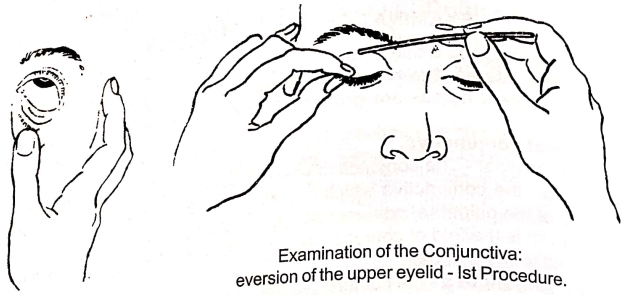

Examination of the Conjunctiva:
eversion of the upper eyelid - Ist Procedure.

Examination of the conjunctiva:
eversion of the lower eyelid

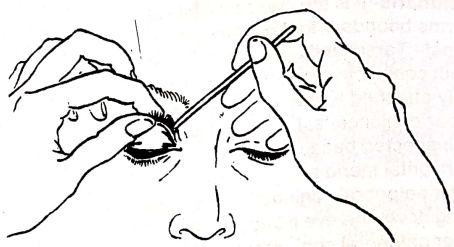

Examination of the Conjunctiva:
eversion of the upper eyelid - Second Procedure

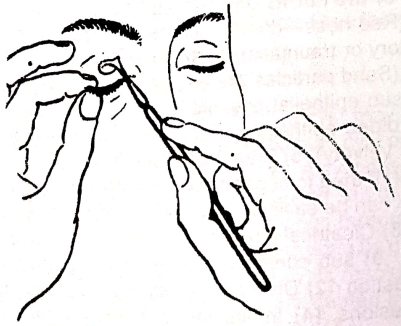

Examination of the Conjunctiva:
eversion of the eyelid for examination of super palpebral fold.

Note:- a1) Follicles, papillae, cicatrical changes, pannus are the common signs of **Trachoma** (Pothaki)

a2) True membrane formation, congestion, hyperaemia, foreign body sensation, are the common signs of true mebranous conjunctivitis due to diphtherial infection.

a3) Follicles formation,Foreign body sensation, congestion,hyperaemia of conjunctiva are the common signs of follicular conjunctivitis .

a4) Frank pus discharge with inflammatory signs of conjunctiva are seen in purulent conjunctivitis commonly due to Gonococcal infection

a5) The common signs & symptoms of conjunctivitis (Abhishyanda). are conjunctival discharge, hyperaemia (Red ness), chemosis, Foreign body sensation and other constitutional symptoms.

b) Examination of Bulbar Conjunctival lesions :-

The following lesions to be noted.

1) Hyperaemia, 2) chemosis; 3) Anaemia, 4) Foreign bodies 5) sub conjunctival haemorrhage (Arjuna) 6) congestion 7) discharge (Watery, mucoid, mucopurulent and purulent) 8) Follicles, 9) papillae, 10) Truemembrane or False membrane formation, 11) phlycten formation at near limbus due to tubercular infection(phlyctenular conjunctivitis -parvani) 12) Triangular subconjunctival layer formation towards cornea do to diegenerative changes is known as pterigium (Arma), 13) A small raised yellowish white nodule occuring in bulbar conjunctiva in Horizontal meridian a little distance away from Limbus occurs due to Allergy and degenerative changes is known as pinguecula (Pistaka, Balasa graditha),

(A phlycten may ulcerate but pinguecula cannot , Dry lustreless conjunctiva with bitods spots arises a little distance to limbus in horizontal meridian is known as Xerosis or xerophthalmia due to vitamin A deficiency, Adhesion between palpebral and bulbar conjunctiva either due to congenital or acquired causes is known as symblepharon, and any other allergic inflammatory traumatic or degenerative lesion of bulbar conjunctiva should be noted.

c) EXAMINATION OF LIMBAL CONJUNCTIVA

Ciliary or circumcorneal congestion, (sirajala) and presence of any nodules should be examined.

(Summary - conjunctiva should be examined for.
1) Hyperaemia 2) Anaemia 3) Pigmentory changes 4) chemosis 5) collections of foreign bodies 6) Haemorrhagic lesions. 7) sub conjunctival haemorrhages 8) xerotic changes 9) Extra growths (layers, nodules cysts tumours etc) 10) Follicles, papillae 11) discharge 12) Cicatrical changes 13) Congestion 14) Adhesions 15) Inflammatory traumatic degenerative and allergic signs should be noted.)

Probing of the lacrimal passages:
Insertion or probe into the lacrimal punctum.

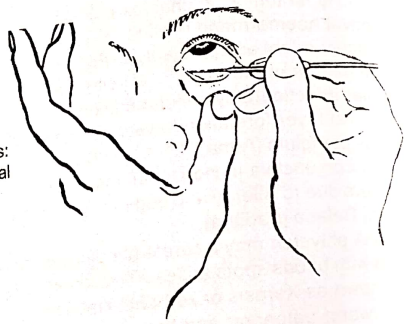

Probing of the lacrimal passages:
Insertion of probe into the lacrimal canaliculus

Probing of the lacrimal Passages:
Insertion of probe into the lacrimal sac.

Examination of Lacrimal apparatus :-

1) Lacrimal sac area (just below the inner canthus) should be examined for any swelling or fistula that may be due to dacryocystitis (inflammation of Lacrimal Sac).

2) By Pressing over the sac area if pus regurgitates through punctum it is of Dacryocystitis.

3) In acute dacryocystitis some times Lacrimal fistula also seen at the same site.

4) Watering of eyes if occurs due to obstruction in lacrimal apparatus is known as epiphora (Netra srava).

EXAMINATION OF EXTRA OCULAR MUSCLES

The six extra ocular muscles are responsible for the movement of eye ball. So the movement of eye ball should be examinaed in all the directions to check the function of the muscles. (The deviation of the visual axis is knownas squint, the oscillatory movement of eye ball is known as Nystagmus).

EXAMINATION OF CORNEA

Cornea is the Anterior 1/6th Part of Fibrous coat which is colourless transparent and the first part of the refractiva media, it appears black due to the iris which is placed exactly at behind. it is Avascular but highly sensiitive due to rich nerve supply. The regular arrangement of corneal components keep it's transparency.

1) Size of the Cornea :-

Normal :- Approximately 10.5 to 11 mm in diameter, the horizontal diameter is slight more than vertical diameter.

If the size of cornea is smaller. Known as **micro cornea** , If the size of cornea is bigger known as **megalo cornea** or **macro cornea**

2) Shape of the Cornea :-

It is sperical anteriorly and circular posteriorly, the anterior surface is smooth regular and with uniform thickness for the refractive purpose, due to congenital abnormalities cornea may present in oval shape, conical shape and in irregular shape.

3) Position of Cornea :-

It occupies central position in the eye ball and well fitted in the anterior scleral aperture like the watch glass. its position is well maintained by extra ocular muscles if not cause squint.

4) Surface of Cornea :-

The anterior surface of cornea is smooth and uniform for optical purpose, if not leads to visual problems (Astigmatism develops due to uneven surface of cornea) .

5) Colour of the Cornea :-

In normal, it is colourless but appears Black due to Iris behind. But in some abnormal conditions it may become red brown white or in multi colours.

6) Thicknes of Cornea :-

Normal central corneal thickness is 0.5 mm, normal peripheral corneal thickness is 0.8. mm, The central zone is more thinner for optical purpose. If the thickness varies due to traumatic or inflammatory causes, that should be noted.

7) Position of cornea :-

whether Normal in the position or with Anterior synechia Should be noted (Adheson of Iris with cornea is known as anterior synechia.

8) Cornea should be examined whether it is Normal in the position or with Anterior staphyloma (Protrusion of Iris through sclera or cornea .

9) Whether cornea is intact or with Iris prolapse, should be noted (Ajakajatha)

10) Examination of minute corneal ulcers, scratches, Foreign bodies etc. should be examined in bright room with magnifying corneal loupe If they are not visualised by corneal loupe, by the following methods those should be detected.

a) 2% fluorescein drops should put in the eye, normal corneal epithelium cannot respond to the above medicine but the injured epithelium (2nd layer exposure happens) responds and be come green colour, like this the smallest scratches, ulcers, penetrating type of Foreign bodies are detected.

b) An Instrument known as placidos disc is used to detect the scratches or smallest, invisible injuries of cornea those derange the surface of cornea.

Placidos disc contain a round plate with central perforation, one surface is painted with concentrical lines equidistantly around the perforation and painted alternatively (one area with black next area white (no colour) this round plate is given support with a handle.

The patient is asked to sit in front of the doctor with light source at the head level of the patient and to words the left side. The doctor should handle the placidos disc in his hand Facing the painted surface to wards the patient and has to see through the central perforation. The painted surface is illuminated with light source and the corneal surface should be examined through the central perforation of placidos disc.

1) If cornea is as smooth as mirror the placido's image is seen as it is in the mirror

2) If any where corneal tissue is injured in that area the concentrical lines of disc shows some irregularity, so image of placidos disc is seen irregular on the affected site of the cornea.

By above two methods, the smallest scratches, injuries, penetrating type of Foreign bodies etc can be detected to assess whether cornea is transparent or affected.

11) If any corneal ulcer (ulcerative keratitis) or opacity (non ulcerative keratitis) or pentetrating type of foreign bodies presnet, the following details should be collected for the perfect diagnosis .

1) Size of the lesion (smaller or wide) 2) Shape of the lesion. 3) Position of the lesion (Whether central or peripheral) (central corneal opacity obstruct the vision) 4) Number of lesions 5) progressive or stationary 6) Drylesion or with discharge 7) depth of the lesion 8) Margins of the lesion to know whether healing type or progressive type 9) Alone or with any adhesions or protrusions or prolapse 10) Colour of the lesion.

Note :- Smaller single, marginal is stationary, dry, superficial, hyperaemic margins without adhesion protrusion prolapse is non complicative.

Examination of corneal Vascularisation.:-

Normally cornea is avascular, except it s 1-2 mm peripheral area. But in some conditions, as a complication cornea may become vascularised or opaque, that should be noted.

Ex:- In trachoma 3rd stage the upper part of cornea is vascularised in triangular shape, is known as pannus formation.

2) In anterior synechia, Anterior staphyloma , Iris prolaps etc diseases due to contact of iris with cornea, there are chances for Vascularisation. of cornea.

13) The colour and depth of corneal opacity should be estimated.
a) Slight discolouration with involvement of superficial epithelium of cornea is known as Nebula.
b) Brown discolouration with moderate thickness of the corneal opacity is known as macula.
c) White conreal opacity with maximum thickness is known as Leucoma.

14) Examination of Corneal sensitivity :- Cornea is having rich nerve supply to have perfect sensitivity to realise the smallest dust particles which collects on cornea, if not the foreign bodies may damage the cornea. But in some Nerve lesions of cornea some part of corneal tissue become insensitive, that affected area should be diagnosed to prevent furthur corneal damge.

CAUSES FOR LOSS OF CONREAL SENSATION

1) Herpes infection 2) Acute congestive glaucoma 3) Absolute glaucoma 4) Leucoma 5) Leprosy 6) Following alcohol injection in the gasserian ganglian 7) Tumour pressing on 5th Nerve etc.

Estimation of corneal sensitivity :-

It is elicited by touching the cornea with a wisp of cotton wool, if the patient do blepharospasm that indicate the cornea is sensitive and if the patient doses not do blepharospasm that indicate some area of cornea is insensitive.

15) Cornea should be examined for any superficial inflammatory changes (superficial keratitis) or deep inflammatory changes (deep keratitis), oedema vesicles or bullae on the epithelium,

16) Corneal endothelium should be examined for any inflammatory deposits known as keratic precipitates.

EXAMINATION OF SCLERA AND EPISCLERA

Sclera is the white opaque, the 5/6th part of outer fibrous coat , it is responsible to maintain the shape of the eye ball. It is covered by episclera and bulbar conjunctiva anteriorly and episclera and Tenons capsule posteriorly (conjunctival covering present only in anterior part of eye ball, that is replaced by Tenons capsule posteriorly).

The lesions of Sclera and Episclera are not common.(very rare)
1) Inflammation of sclera is known as scleritis.
2) Inflammation of episclera is known as episcleritis.
3) Thinning of sclera at limbal area may cause scleral staphyloma through which Iris protrudes out.
4) Thinning of sclera at posterior pole of eye ball (posterior scleral staphyloma) is the commonest cause for axial myopia .
5) Sclera should be checked for foreign bodies. congestion oedema and pigmentory changes.

EXAMINATION OF LIMBUS

Limbus is a small transitional zone present between cornea and sclera (sclero corneal junction). It contain circular canal of schlemm, having importance in aqueous circulation.

a) LImbus should be examined for any traumatic or surgical scars.
b) Congestion of vessels (ciliary congestion seen radially)
c) Pterigium, pinguecula, phlycten, Bitods spots, Xerotic changes, Vascularisation. Staphyloma etc should be examined which are commonly observed at limbus.

Examination of Anterior Chamber :-

It is a small chamber (2.5 mm depth centrally) present in between cornea and Anterior uvea (Iris, ciliary body), it contain aqueous humour, through this chamber the aqueous circulate in to schlemm's canal of Limbus, by this normal intra ocular pressure is maintained. Aqueous chamber should be examined (Trans illumination) for the following points.

1) Depth of the Anterior chamber whether.
a) Normal b) Shallow (may cause glaucoma due to obstruction in aqueous circulation). c) deep (Commonly in Aphakia)

2) Aqueous fluid should be checked for the inflammatory precipitates.

a) Collection of pus in Aqueous chamber is known as Hypopyon .
b) Collection of blood in Aqueous chamber is known as Hyphaema .
c) Collection of Keratic precipitates on endothelium of cornea.
All these commonly seen in uveitis etc inflammatory lesions.
d) Examination of Angle of anterior chamber is important for the con
firmation of glaucoma, it is possible with the instrument known as
gonioscope.

EXAMINATION OF IRIS

Iris is a coloured circular diaphragm present in between cornea and lens. on either sides it continues with ciliary body and chorroid. It contains a central perforation known as pupil, the constriction and dilatation of pupil is regulated by the sphinctre pupillae and dilator pupillae muscles of iris. The anterior surface of Iris is uneven and shows many crypts and fissures. The cornea appears black or brown due to iris which is exactly behind . The following points should be examined.

1) Whether Iris present or absent (congenitally Absence of Iris is known as Aniridia.
2) Iris is a pigmented diaphragm, if the pigment reduces causes photo phobia, blurring of vision and nystagmus, that is known as Albinism .
3) The colours of both Irides or All the sectors of Iris should be in uniform colour,if not called Heterochromia of Iris.
4) Size shape of the iris should be noted .
5) Position of the iris should be noted whether it is central or displaced
a) Adhesion of Iris with cornea is known as anterior synechia .
b) Adhesion of Iris with lens is known as posterior synechia .
c) Bulging of Iris anteriorlly in secclusio pupillae due to the pressure of aqueous humour on iris, is known as Iris bombi

6) Iris vessels are not visible in general but in Rubeosis iridis disease, new vessels are formed and seen.

7) Surface of Iris, should be examined to see the colour crysts and fissure etc, in Iritis the surface appears in uniform mud colour, (no crypts and fissures.)

8) Iris should be examined for its unifolm colour but the lesions of atrophic patches (depigmented) are seen some times, those should be noted.

9) Gapping of Iris (Coloboma) seen in congenital lesions, after iridectomy and by penetrating injuries.

10) The tremulousness (Shaking or moving Iris) of Iris if elicited by the movment of eye ball, it is known as Iriododonesis. it is observed in the aphakia and in Subluxation of lens etc.

11) Tearing of Iris from it's attachment (ciliary body) and giving the pupil D shape, is known as Iridodialysis .

12) Inflammation of Iris is known as			Iritis.
"	Ciliary body	"	Cyclitis
"	Choroid	"	Choroiditis (Posterior uveitis)
"	Iris and ciliary body	"	Iridocyclitis or Anterior Uveitis
"	Iris, ciliary body, choroid		Total Uveitis.

" The infection of one part easily spreads to other and cause compete Uveitis.

13) Iris can be seen and examined directly through cornea but ciliary body and choroid direct examination is not possible, it can be estimated by the following signs and symptoms.

COMMON CLINICAL FEATURES OF UVEITIS

1) Hypopyon 2) Hyphaema 3) Keratic precipitates 4) Posterior synechia 5) formation of cyclitic membrane behind the lens 6) retinal detachment 7) Pain and redness of eye 8) moving spots beofre the eye 9) Hazy vision 10) Metamorphopsia (distortion of objects) 11) Micropsia (objects appears maller) 12) Macropsia (Objects seen bigger) 13) Photopsia (Flashes of light seen due to retinal irritation) 14) ciliary congestion 15) ciliary tenderness 16) cloudy aqueous 17) deep anterior chamber 18) muddy Iris 19) Irregular pupil with sluggished reaction. 20) Iris bombi 21) secclusio pupillae and occulusio pupillae 22) secondary glaucoma 23) Finally may cause Hypotony or Phthisis bubi.

EXAMINATION OF PUPIL

It is the central perforation of the Iris meant for regulating the entry of light rays into the retina by the constriction and dilatation. The following points should be noted while the examination of pupil .

1) Size :- Normal 3 to 4 mm (Bigger in the adults and smaller in the old; constrict in bright illumination and dilates in the dim illumination; pupil constrictors are known as miotics and pupil dilators are known as mydriotics. Mydriotics or used for fundoscopy and to prevent anterior synechia, miotics used to treat glaucoma).

2) Shape :- Normally circular but seen irregular in Uveal tract lesions and synechia .
3) Position of pupil - Normally present in centre but seen eccentric or drawn to front or back or sides in Uveitis and synechia .

4) Pupillary margin - It should be regular but may become irregular in synechia. Uveitis, seclusio pupillae, and occlusio pupillae .

5) Pupillary aperture should be clear without any occlusion, but following abnormalities should be noted.
a) Inflammatory exudates collects and cause occlusio pupilae, it causes obstruction to vision.
b) the pupillary margin completely attached to the lens capsule and produce secclusio pupillae, it causes visual obstruction and iris bombi.

6) Pupillary reaction to light :-
a) Driect method - Light should be focussed and removed alternatively and the constriction and dilatation of the pupil should be noted respectively.
b) Consensual method - light should be focussed in the one eye and pupillary reaction (constriction and dilatation) should observe in the other eye.
3) Pupil reaction to accommodation or convergence
Patient is asked to look at a near object and his pupil should be observed for constriction.

EXAMINATION OF THE CRYSTALLINE LENS

Lens is a traasparent, Bi convex structure present in the eye ball to converge and focuss the light rays on fovea of macula of retina for visual perception. its dioptric power is + 17.5 . on either sides it is supported by suspensary ligaments or zonule and it is situated in between Iris and vitreous humour.

In transillumination test a) When the lens is transparant nothing can be seen behind the pupil except a black shade .
b) When lens become opaque, Brown or white colour opacities are seen behind the pupil.
c) In Senile Lental Sclerosis also lens appears brown or white in transillumination test.

It should be confirmed by ophtholmoscopic examination.
The findings of ophthalmoscopy.
a1) Lental opacities (cataract) appears as black spots in front of red reflex of the retina -.

a2) In normal condition the red reflex of retina, macula, optic disc and vessels are seen perfectly (no black dots seen)
a3) In immature cataract the red reflex and contents of retina are seen partially.
a4) In mature cataract red reflex is absent, media is obstructed and appears black,

B) In senile Lental sclerosis though lens appears in brown externally, media appears clear by opthalmoscopic examinatiion .

"The different types of cataracts can be easily diagnosed by ophthalm oscopy "
The follwing features should be examined by ophthalmoscopy.
1) Colour of the lens, place of the opacity (central - marginal or total) 3) Displacement of lens (sub luxation - partial dis placement of lens, luxation total displacement of lens) should be noted 4) presence or absence of lens (Aphakia) should be noted.

During the examination of retinal vessels, the narrowing, tortuosity, dilatation, sheathing, venous compression at the arterio venous crossings and light reflex from the vessels should be noted. when retinal pigment is deficient choroidal vessels seen as pinkish flat ribbons which do not show any light reflex.

A slit lamp

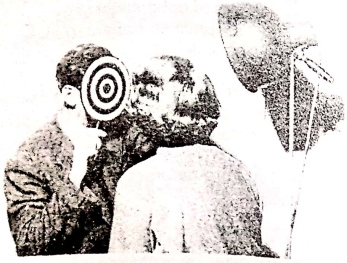

Placido's disc

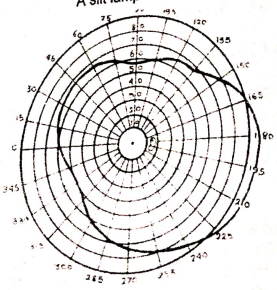

Extent of normal visual field of the right eye

Digital tonometry

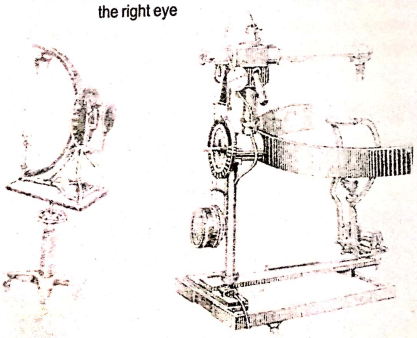

Projection perimeter

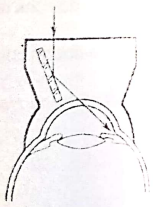

A diagram of gonioscopy

ESTIMATION OF INTRA OCULAR PRESSURE

1) Digital tonometry :-

It is by palpation of the eyes with fingers, patient is asked to look down then the sclera is palpated through the upper lid beyond the tarsal plate. The tension is judged by the amount of fluctuation obtained.

2) By Schiotz tonometer :-

The patient is asked to liedown on a table, local anaesthesia is given, the eye lids are separated with fingers or with universal eye speculum. Now the cornea is properly exposed, later the foot plate of tonometer is kept on the cornea then the deflection of the pointer on the scale should be recorded, like the deflextion reading should be recorded for different weight. Later on the deflection should be interpreted in terms of intra ocular tension from the chart accompanying the tonometer. the normal intra ocular pressure is 18 to 25 mm Hg. if it increases causes a dreadful disease known as glaucoma.

THE FUNCTIONAL EXAMINATION OF EYE BALL

1) Visual acuity :-

Central or direct vision

a) Distrant central vision is estimated with snellen's chart.

b) Near central vision is estimated with jaeger's test types, snellen's test types, printer's type of N serives.

a) Estimationof central distant vision with the help of snellen's chart :-

The snellen's chart is placed 6 meters or 20 feet distance from the patient, the patient is asked to sit on a stool facing the chart from 6 meters distance and asked to read the prints of the chart by closing one eye. The chart contain different sized prints in 7 or 8 Lines, from Bigger size to smaller From Top to down wards.

The each line is marked with some specific number. they are (from top to bottom) 60, 36, 24, 18, 12, 9, 6,5.

If the patient is able to read upto 6 number row, his vision is 6/6 - Normal.

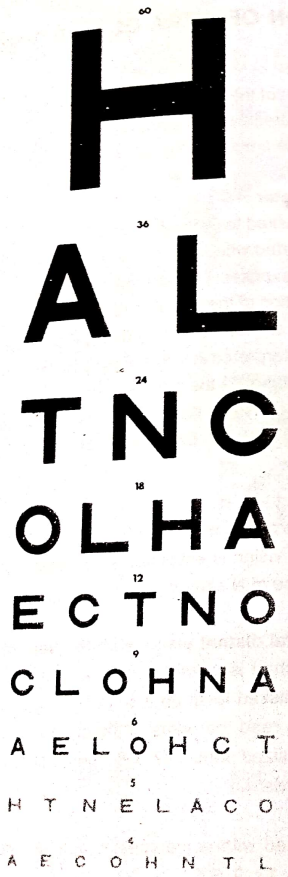

Snellen's Distant Test Types (reduced). The lines, from above downwards, should be read at 60, 26,24,18,12,9,6,5 and 4 m, respectively, i.e., at these distances the letters subtend a visual angle of 5.

If the patient able to read only	1st line		His vision is	6/60
" "	2nd line	"		6/36
" "	3rd line	"		6/24
" "	4th line	"		6/18
" "	5th line	"		6/12
" "	6th line	"		6/9
" "	7th line	"		6/6 normal vision
" "	8th line	"		6/5

Note :- 1) 6/6 is normal
2) 6/5 the Best vision.
3) In 6/6 the upper six is the fixed distance between the patient and chart, thelower six is the marking of the 7th line of the Snellen's chart..

Models of snellens chart prints.

1) One surace contain English alphabets .
2) 2nd surface contain the letters of different Local language.
3) 3rd surface contain Black dots in squares asked to count the black circles in each square (for illiterates)

4th surface of the snellen's chast contain E or C shaped pictures, patients are asked to find out the direction of or gap of E or C (This is also for illiterates).

If the patient is not able to recorgnise even the first letter of the chart (vision less than 6/60), than the distance between the chart and patient should be reduced .

If the patient can see the top letter from	5 meters	his vision is		5/60
" " "	4 Meters	"		4/60
" " "	3 meters			3/60
" " "	2 meters			2/60
" " "	1 meter			1/60

If the patient is not able to recognise the top letter of the chart even from 1 meter, he is asked to count the fingers from 3/2/1 feet distance, finally the patient is asked to recognise the projection of light (Directions of light) and perception of light (identificationof Brightness of Light).

Like this the distant central vision can be estimated accurately.

Note :- After completion of the examination of one eye, the other eye should be examined.



Direct Ophthalmoscope

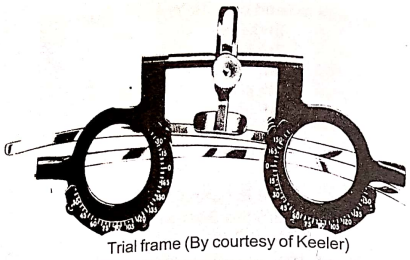

Trial frame (By courtesy of Keeler)

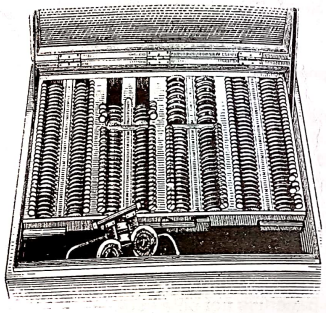

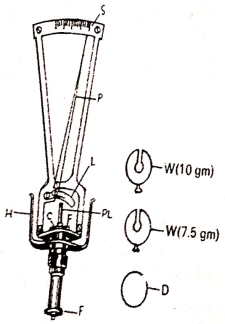

Schiotz Tonometer

Schiotz tonometer (by courtesy of

OPHTHALMOSCOPY

Ophthalmoscope is used for the examination of posterior segment of the eye ball, ophthalmoscopy is highly important diagnostic procedure not only in the diseases of eye but also in the many diseases of visceral organs (systemic lesions).

Ophthalmoscope contain a handle and head piece. handle is for handling the instrument to put cells inside, it also contain on - off switch. The head piece contain a central perforation with the arrangement of mini bulb to focuss the light rays into fundus and concave and convex lenes to see the fundus and in addition to above there is arrangement for producing different types of light beams to see the different parts. (Macular beam, fundus beam, Retinal beam, slit beam etc),

Before ophthalmoscopy, pupil dilatation of the patient is neeeded for clear and camplete view of fundus (but pupil dilatation is contra indicated in glaucoma). Right eye of the patient should be examined with the right eye of the examiner by handling the instrument in right hand - and vice versa

Note :- 1) In indirect ophthalmoscopy 5 times magnification of the fundus can be seen with inverted image and with Direct ophthalmoscopy 10 times magnification of the fundus can be seen with errect image.

2) Regular practice is needed for conducting ophthalmosopy.

Direct ophthalmoscopy :-

1) In a dark room patient is asked to sit comfortablly, a red bulb should be arranged above the head level and facing opposite to the patient.

2) While the examination, the doctor should sit infront of the patient and should place the ophthalmoscope close to the patient's eye without hurting him (only one inch gap between 2 faces).

3) The eye is illuminated by the light reflected from the ophthalmoscope.

4) The lenses should adjust to see the media and fundus clearly through the hole of the ophthalmoscope.

5) if both the examiner and the patient are emmetropic a clear view of the fundus can be seen without any adjustment of lens if not by adjusting the lenses ophthalmoscopy should be don.

6) If the refractive media is clear (cornea, aqueous Lens vitreous) the red reflex of retina is seen brightly at the pupil in ophthalmoscopy.

7) If any opacities are present in the media those appear as black spots (fixed or floating) against the red back ground of fundus of retina.

8) If the media is partially opaque, the red reflex seen partially and if media completely opaque the red reflex cannot be seen.

9) The moving opacities situate in vitreous or aqueous, and the fixed opacities situate in cornea and Lens .

10) When the eye ball is moved if the the opacities move in the same direction those present in the anterior plane, and if move in opposite direction those prasent in the posterior plane.

11) Dots or spots if disappears when closely approached, thay are lental, if persist they are corneal.

12) While the examination of the macula the patient is asked to see straight into the hole of ophthalmoscope.

13) While the examination of optic disc the patient is asked to see towards the opposite shoulder or ear of the examiner to expose the optic disc.

14) If the patient is myopic by adjusting concave lenses, if Hyper metropic by adjusting convex Lenses, fundus should be examined for the following points.

1) Optic disc 2) macula 3) Periphery of retina and 4) Vessels of retina.

Examination of optic disc :-

It is a round or oval structure . pale pink in colour, stuated at the posterior part of fundus, medial to macula (Posterior pole) it is also known as optic nerve head. There is excavation at the central part of disc known as the physiological cup, whose dept and extent varies in different subjects. The margins of the disc are normally sharp and distinct so during the examinationof the fundus, the colour shape, margins, physiological cup, presence of abnormal vessels and any other lesions should be noted.

In optic atrophy disc become pale or white with blurred margins, in oedema and raised intra cranial pressure (papilloedema) discbulges and protrudes with blurred margins, in papillitis disc become hyperaemic margin be come blurred and later on disc swells, in chronic glaucoma cupping of the disc seen.

Examination of macula :-

It present at the posterior pole cones are tightly packed so only it is responsible for the perception of bright and colour vision, it contain a central depression known as fovea centralis where the light rays are focussed for the visual sensation. During ophthalmoscopic examination fovea appears as a bright reflex, but in degenerative condtitions, burns and in the other lesions the brightness of macula reduces and lead to blindness.

Examination of Retinal vesels :-

The arteries and veins radiate from the optic disc and spread all over the fundus. arteries appear in bright red colour and venins in purplish red.

EXAMINATION OF CENTRAL NEAR VISION

It is carried out with the help of snellen's prints or jaeger's prints or printer's type of N series.

Patient is asked to sit comfortably, the test types should be properly illuminated from behind the head of the patient, each eye is to be tested separately at a distance of about 25 cm or 30 cm . The test types are present from smaller print to Bigger gradually. A person with normal accommodation can read the smallest types also. if he cannot read the smallest types, the types which he can read should be noted, N/10 , N/12 etc or J/10, J/12 etc.

EXAMINATION OF COLOUR VISION

The human eye can distinguish seven or eight colour of spectrum (Red - Blue and green are 3 primary colours). Normal colour perception is essential in some occupations such as the Railway, steamship services, Navy and airforces. There are several methods for tesing colur vsion. Among them the common one is Ishihara ISO chromatic chart.

Ishihara Iso chromatic hart contains bold numerals which are represented in dots of different tints, which are very confusing to the colour blind persons. when he can see all the colours then only he can Identify the numerals of the chart.

Field of vision :-

It is a space within an object can be seen when the eye remains fixed on some point. The extent of the field can be roughly estimated by con frontation method, more accurately by the perimeter.

Confrontation Method :-

The patient is asked to sit infront of the examiner at a distance of about 2 feet, light is being placed above and behind the head of the patient. To examine the patients Right eye he is asked to close his left eye with his leftpalm and should fix his right eye on the examiner's left eye.

The examiner has to close his right eye and bring his hand with extended fingers in midway between the patient and himselft, from periphery to inward and the patient is asked to indicate when he first see the fingers, the same test is repeated in all the directions. like this the doctor should examine the patients field of vision by comparing to his own vision.

Perimetry :-

Perimeter records the field of vision accurately, this method is known as perimetry. This instrument contain a metallic semi circle which can be rotated in any direction, the arc is marked in degrees "O". at the cnetre and 90 on each end. The patients head should be supported on chin rest of the instrument 33 cm away from the middle of tthe arc one eye should be covered and other fixes on an object placed at the centre of the arc. A test object is a white or coloured disc of varying sizes is carried along the inner surface of arc and the points at which it is first observed in the different meridians should be recorded on a specially designed chart- in routine work the extent of the field should be recorded with two different sized white objects one a 3 mm and other 1 mm, some times coloured test object may also be used.

Extent of normal field of vision for 5 mm test object

The visual field extends 100° on temporal side, 60° on nasal side, 55 to 60° Above and 75° below.

(Within the visual field there may be areas of defect which are known as scotomata (no perceptive elements)

Scotometry of Central and paracentral visual field with Bjerrum's screen:-

Bjerrum screen is used to detect central and para central visual field, within a radious of 30°. It consist of a black curtain of 2 meters square, which is fixed on a wodden frame work. The patient is seated at a two meters distance. The test object consists of round white disc mounted to a black rod. (There are various sizes of test objects both white and coloured) with one eye closed, the patient should fixe the other eye on white spot which in the centre of the screen. At first blind spot should be mapped out on the screen using a 10 mm white test object, then the extent of the visual field is determined with one or two mm white test objects and finally working systematically over the field the presence of any scotoma should be detected. while recording the extent of a scotoma it is advisable to move the test object from the blind to the seeing area. when the scotoma is relative it may not be detected until a coloured test object is used.

All these findings are marked out by inserting black headed pins on the screen . The result is then transferred on a printed chart for record.

OPHTHALMIC INSTRUMENTS

Plate No. I

1) a) **Universal eye speculum:-**. It can be used for either eye, it has a spring two limbs to keep the eye lids separate. As there is no guard more space is obtained during the operation (The eye lashes protrude in the field of operation due the absence of guard).

I) b) **Guarded eye speculum :-** There are two instruments one for right eye and another for left eye. it has a spring and two limbs. the upper limb has a guard to keep the eye lashes away from the field of operation.

2) Fixation Forceps :- It has 2 to 5 teeth and used to fix the eye ball through the conjunctiva and episcleral tissue during the operation.

3) Von graefe's Cataract Knife :-

It has a long narrow thin straight blade with a sharp point and sharp cutting edge, used for making section for cataract operation, iridectomy and for paracentesis .

4) Elschnigs intra capsular Forceps:-

Each limb of the forceps has a double curve and blunt point without teeth, it is used to hold the anterior Lens capsule at 6 0 clock position in intra capsular Lens extraction.

5) Capsulotome or Cystitome :-

It has a tiny sharp and bent point at the end of a straight narrow limb, it is used to tear the capsule of lens in Extra capsular Lens extraction.

8) Capsule forceps:- used to hold the capsule of lens during lens extraction.

7) Mc namara Spoon :-

it has two tiny spoons at the ends of a metal handle, used to apply counter presssure beyond the limbus, during extraction of lens and to remove dislocated lens.

8) Lens expressor :-

It has a flat corrugaged metal handle with a curved knob pointed limb it is used to apply pressure with Knob point of the curved limb on the Limbus, druing the extraction of Lens.

Pate II

9) Iris forceps - The shape of the forceps are of various types (Straight angular curved) It is used for holding the iris for iridectomy.

10) Iris scissors :- The blades vary in shape and used for Iridectomy.

11) Iris repositor :- It is used to reposit the iris by clearing it from the wound after iridectomy .

12) Anterior chamber washing canula :-
It is used to clean the anterior chamber from various precipitants.

13) Bowmans discission needle:- It is straight sharp triangular needle with gaurd, used for discission of congenital or traumatic cataract and for needling of an after catract.

14) Ordinary discission needle :-
Same as above but the needle dosen't contain gaurd.

15) Keratome :-
It has a triangular bloade with a sharp cutting edges, used for Limbus incision and for paracentesis.

16) Zeigler's Knife :-
It has a tiny curved blade with a sharp point at the end of a narrow limb, attached to a handle. it is used for incising the after cataract in the pupillary area.

17) Vectis :-
It is a loope of Wire at the end of a narrow Limb attached to a handle, it is used to remove the subluxation of lens

Plate III

18) Tooke's Knife :-
It has a short elongated blade attached to a handle with a semi circular cutting edge, bevelled on both surfaces.It is used for splitting the cornea during elliotis sclero corneal trephening operation.

19) Elliot's sclero corneal trephine handle with blade :-
It is used for punching a hole in the wall of the eye ball at Limbus in 12^0 Clock position during Trephine operation.

20) Disc holding Foceps :-
It is used for catching the disc of sclero corneal tissue made by the trephine blade.

21) Broad needle or Paracentesis needle.:- It is used for paracentesis to drain the aqueous, to reduce the intra ocular prssure.

22) Thermo Cautery :-
The cautery is heated in the flame of a spirit lamp and then applied, used for cauterizing tiny iris prolapse, progressive margin of corneal ulcer, and bleeding points.

23) Epilation forceps :-
It is used for epilation of eye lashes in trichiasis.

24) Des marrie's upper lid retracter :-
It is used for examination of eye in a child and in blepharospasm

25) Enucleation scissors :-
It is used to cut optic nerve etc, during enucleation operation.

26) Evisceration scoop of mule :-
It is used for scooping out the contents of eye ball during evisceration operation.

27) Sac knife :-
It is used for incising of skin subcutaneous tissue and for removal of lacrimal sac or for dacryocystorhinostomy operation .

28) Muller's Retractor :-
It is used to retract the skin edges during dacryo cystectomy or dacryocystorhinostomy operation.

29) Rougine :-
It is used for separating the lacrimal sac from lacrimal fossa during dacryo cystectomy operation.

30) Lang's dissector with scoop :-
It is used for following the removal of the sac, the scoope is used to scrape off the epithelium from the upper end of the naso lacrimal duct for drainage purpose.

Plate IV

31) Nettleship's puctum dilator :-
It is used for dilatation of puncta in case of stenosis of punctum .

32) Lacrimal canula :- It is used to test the pateny of the lacrimal sac.

33) Chalazion forceps :- It is used for the fixation of chalazian cyst during the operation

34) Beer's Knife :-
It is used for incising a chalazian (Vertical incision)

34) Chalazian Scoope :-
It is used for scooping out the granulation tissue of the chalazian after incision with Beer's Knife.

36) Strabismus hook or Squint hook :-
It is used for catching the extra ocular muscles during squint operation, enucleation operation or operation for detachment of retina.

37) Strabismus Scissors ;-
It is used to cut the extra ocular muscles during the operation.

38) Foreign body spud and Needle :-
It is used to remove the corneal foreign bodies.

39) Sinclair's Cyclodialysis spatula :-
It is used to separate the ciliary body from its attachment to the scleral spur during cyclodialysis operation for aphakic glaucoma.

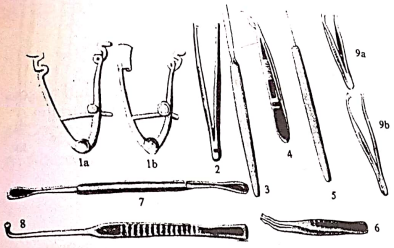

PLATE I

(1a) Universal Eye Speculum (1b) Guarded Eye Speculum (2) Fixation Forceps. (3) Von Graefe's Cataract Knife. (4) Elschnig's Intra-Capsular Forceps. (5) Capsulotome or Cystitome (6) Capsule Forceps. (7) MacNamara Spoon. (8) Lens Expressor (9a) Iris Forceps-Angular. (9b) Iris Forceps-Curved.

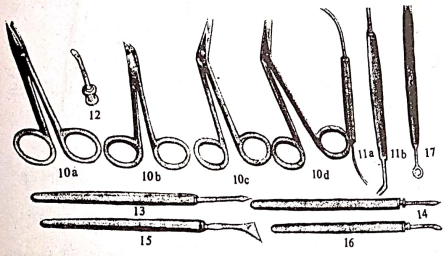

PLATE II

(10a) Iris Scissors-Straight and Sharp-pointed. (10b) Iris Scissors-Curved on flat and sharp-pointed. (10c) Iris Scissors-Angular and sharp-pointed. (10d) Iris Scissors-Angular and Knob-pointed, (11a) Iris Repositor-'S' shaped. (11b) Iris Repositor-Angular. (12) Anterior Chamber Washing canula. (13) Bowman's Discission Needle. (14) Ordinary Discission Needle. (15) Keratome (16) Zeigler's Knife. (17) Vectis

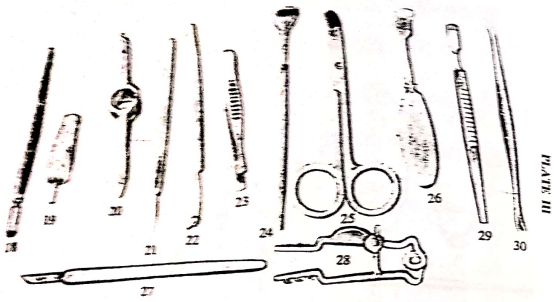

18. Tooke's Knife. 19. Elliot's Sclero-Corneal Trephine Handle with Blade. 20. Disc-Holding Forecepts. 21. Broad Needle or Paracentesis Needle. 22. Thermo-cautery 23. Epilation Forceps. 24. Desmarre's Upper Lid Retractor. 25. Enucleation Scissors. 26. Evisceration Scoop of Mule. 27 Sac Knife. 28. Muller's Retractor. 29. Rougine 30. Lang's

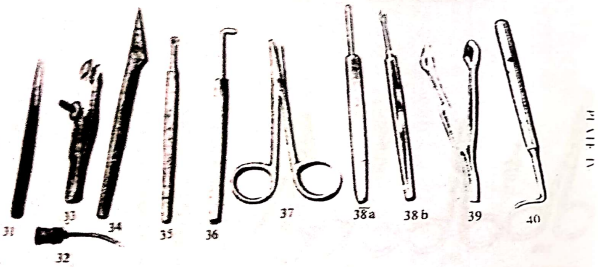

Nettleships Punctum Dilator. 32. Lacrimal Canula, 33. Chalazion Forceps. 34. Beer's Knife. 35. Chalazion Scoop. 36. Strabismus Hook or Squint Hook. 37. Strabismus Scissors. 38a. Foreign Body Spud. 38b. Foreign Body Needle. 39. Knapp's Roller Forceps. 40. Sinclair's Cyclodialysis Spatula.

C.S.S.

N.K.J. AYURVEDIC MEDICAL COLLEGE HOSPITAL - BIDAR.

AFFLIATED TO RAJIVGANDHI HEALTH UNIVERSITY - KARNATAKA

SHALAKYA I CASE SHEET

DEPARTMENT OF SHALYA SHALAKYA

1 1) Name of the Patient 2) Age 3) Sex

4) Caste 5) Occupation

6) Address 7) Registration No.

O.P.D. No.

I.P.D. No.

Bed No.

8) Date 9) Provisional diagnosis

---

ii) 1) Patient's chief Complaints, duration.

2) Associated complaints, duration :

3) History of Present illness :

4) History of Previous illness :

5) Personal history :

6) Family history :

III) Asta sthana pareeksha :-

1) Nadi
2) Mutra
3) Malam
4) Jihwa
5) Shabda
6) Sparsha
7) Druk
8) Akruthi

IV) Dasha - vidha pareeksha :-

1) prakruthi
2) Vikruthi
3) Sara
4) Samhanana
5) Pramana
6) Satmya
7) Satwa
8) Ahara Shakthi
9) Vyayama Shakthi
10) Vayas

V) Anga pratyanga Pareeksha :-

1) Heart
2) Lungs
3) Liver
4) Spleen

Other ;-

VI) Samsthanika - pareeksha : - (Systemic Examination)

VII. General Examination of FACE -ORBIT and EYE BALL

1. Face whether bilateral symmetrical ( ) or not. ( )
2. Protrusion of eye ball (Exophthalmos) ( )
3. Sunken eye ball (Anophthalmos) ( )
4. Shrinken eye ball (Phthisis bulbi) ( )
5. Smaller eye ball (microphthalmos) ( )
6. Bigger eye ball (Buphthalmos) ( )
7. Deviated axis of eye ball (Squint or strabismus) ( )
8. Oscillatory eye ball (Nystagmus) ( )
9. Congenital abnormalities if any:- ( )

VIII), Examination of appendages of eye ball (lacrimal apparatus etc

IX) Examination of PAKSHMA MANDALA (Eye Lashes)

1. Normal eye lashes (Fresh, regular, soft, normal in colour, position and number.) ( )

2. ABNORMAL :-

a) Absence of eye lashes (Pakshma, Shaatha - madarosis ( )
b) irregular hard eye lashes (Pakshma kopa, Trichiasis) ( )
c) Depigmented eye lashes (Greyish - whitish) ( )
d) Eye lashes with parasites ( ) e) Matting of eye lashes ( )
f)
g) Description :-

x). Examination of PAKSHMA VARTHMA SANDHI (Eye lid margins)

1) NORMAL :-

Normal in colour size, thickness, position and function, without any abnormalities .

2) ABNORMAL :-

a) Inflammation of eye lid margin (krimigrandhi - Blepharitis) ( )
b) Hyperaemia of eye lid margin (Ragatwam-Milphosis) ( )
c) Thickening of eye lid margin (Sthulatwam-Tylosis) ( )
d) Cystic swelling at the root of cilia (Anjana namika kumbhipitika- zeiscyst or stye) ( )
e) Inversion of eye lid margin (entropion) ( )
f) Eversion of eye lid margin (ectropion) ( )
g) Adhesions of lid margins, if any.
h)
j) Description :

XI Examinationof Varthma Mandala (Eye lids)

1.size : (a) Normal b) Abnormal ( )
2.Shape : (a) Normal b) Abnormal ( )
3.Colour: (a) Normal b) Abnormal ( )
4.Skin surface : a) Normal b) Scars c) Burns d) Injuries ( )
5.Oedema : a) Partial b) Total ( )
6.Cyst (Grandhi) : Chalazian (Utsangini) ( )
7.Polyps (Arsha) ( ) 8. Abscess (Vidradi) ( ) 9. Tumour (Arbuda)( )

10). Varthmakriya (function of eye lids)
a) Normal b) Abnormal
A) Lagophthalmos (improper closure of eye lids)
B) Ptosis (improper opening of eye lids) (Vatahatvarthma) ( )
C) Increased blinking of eye lids (Nimesha)

11. Varthantah sleshma Kala (Palpebral conjunctiva)
A) NORMAL :-
Conjunctiva is bright transparent without any inflammatory, degenerative and traumatic lesions. ( )

B) ABNORMAL :-
a) Hyperaemia b) Anaemia c) Follicles d) Papillae
e) True membrane f) Falsemembrane g Foreign bodies
h) Cicatrical changes j) Haemorrhagic lesions j) .....
k) congestion l) Discharge, m) Adhesions n) .....

12) Description :-

XII) Examination of Varthma Shukla Sandhi (Fornix)

1) NORMAL :-

2) ABNORMAL :-
a) Hyperaemia b) Anaemia c) Foillicles d) Papillae
e) True membrane f) False membrane g) Foreign bodies
h) Cicatrical changes i) Haemorrhagic lesions j) inflammatory lesions
k) Congestion l) Discharge m) Adesions n) .....
Description :-

XIII) Examination of Shukla Mandala (Sclera - bulbar conjunctiva).

A) NORMAL ( )
B) ABNORMAL :
a) Hyperaemia b Anaemia c) Papillae d) Follicles e) True membrane f) False membrane g) Phlycten h) Pterigium i) Pinguecula j) Haemorrhagic lesions. k) Congestion l) Discharge.....m) Allergic changes. n) Inflammatory changes p) Degenerative changes p) Episcleritis. q) Sclertis.
C) Description.

XIV.) Examination of KRISHNA MANDALA (Cornea - Iris)

A) Examination of cornea :
1) Size :
NORMAL approximately II mm in diameter ( )
ABNORMAL : a) Micro cornea b) Megalo cornea etc. ( )

2) Shape
Normal :-Sperical, Horizontal diameter is slight ( )
More than Vertical diameter
Abnormal :- a) Oval b) Conical c) irreular d)..... ( )

3) Surface
Normal :- Smooth uniform , Convex anteriorly
Abnormal a) Rough b) irregular c) Flat d)..... ( )

4) Colour
Normal : Colour less. bright : transparent
Abnormal : a) Brown b) White cO Red d)..... ( )

5) Thickness
Normal : Central thin zone, peripheral thicker zone ( )
Abnormal :..... ( )

6) Transparent ( )

7) Opaque
a) Corneal opacities b) Uicers c) Scratches d) Foreignbodies ( )
Central /marginal; Superficial /Deep; single/ Multiple;
Smaller /Wider

8) Vascularisation
9) Sensitivity a) normal b) Partial loss c) Total loss ( )
10) Congenital abnormalities if any.....
11)
12) Description :

B) Examination of Iris :-

1) size : a) Normal b) Abnormal ( ) 2) Shape : a) Normal b) Abnormal( ) 2)
Surface : a) Normal b) Abnormal (Adhesions, inflammatory lesions. ( )
Injuries etc) ( )
3) Colour :a) Normal b) Abnormal ( ) 4) Thickness a) Normal b) Abnormal ( )
5) Position : Normal b) Abnormal (Synechia) ( )
6) Gaping : a) congenital (Coloboma) b) Acquired (Iridectomy) ( )
7) a) Iridencleosis b) Iridodialysis c) Presence of vessels ( )
8) Description ;-

C) **Examination of Anterior Chamber and Aqueous humour**

1) Depth of Anterior chamber a) Normal b) Deep c) Shallow ( )
2) Angle of Anterior chmaber a) Open b) Closed ( )
3) Aqueous humour c) Hyphaema (with blood)
   a) Transparent d) Other precipitants ( )
   b) Hypopyon (with pus)

4) Intra ocular pressure :
5) Description :-

XV) Examination of Krishna Drusti Sandhi (Limbus)

XVI.) Examination of Drusti Sandhi

A). Examination of Pupil
   1. size a) Normal (3 to 4 mm dia meter) b) Abnormal ( )
   2. Shape :- a) Normal (circular) b) Abnormal ( )
   3. Position ; a) Normal b) Deviated Anterior synechia ( )
      posterior synechia
   4. Margin a) Normal b) Abnormal ( )
   5. Aperture : a) Normal b) Occluded ( )
   6. Reaction : a) Reactive b) Sluggished c) Absent ( )
   7. Description :-

B. Lens :-
1. a) Transparent b) Opaque ( )
2. Opacity :- a) Capsular b) Cortical c) nuclear ( )
3. a) Partial /Total b) Dotlike/Diffused c) Congenital/Acquired ( )
4. a) Immature b) Mature c) Hypermature ( )
5. Description :-

C). Retina :-
   1. Optic disc
   2. Macula
   3. Fundus
   4. Examination of Refractive media
   5.
   6. Description .

D). Vision Examination R.EYE L. EYE
   1. Distant. Vision.
   2) Near Vision.
   3) Colour Vision.
   4) Field of vision.

E) Instrumental Examination

F) Description

XVII Differential Diagnosis :

VIII) **Final diagnosis**

XIX) **Pancha Lakshana Nidanam**

1. Nidana :

2. Poorva rupa

3. Rupa

4. Upashaya :

5. Samprapthi

6. Dosha Vikruthi

7. Dushya Vikruthi

8. Sroto vikruthi

9. Rogi balam.

10. Roga balam

11. Sadhyaa Sadhyatha

XX) A. **Chikitsa Sutra**

B. Pathya :

C. Apathya :

D. Aushada chikitsa :

1. Sthanika chikitsa

II. Saarva dehika chikitsa

E. Shastra Chikitsa ;

I. Poorva Karma

II. Pradhana Karma

III. Paschaat Karma

XXI) Result

XXII) Advises

Signature of the Student

signature of the lecturer

BIBLIOGRAPHY

1. Bruhattraya
2. Laghutraya
3. Basavarajeeya
4. Chakradattha
5. Hareetha Samhitha
6. Vangasena
7. Sachitra Shalakya by Dr. Ravindra Chandra Chaudari
8. Shalakya tantra by Dr. Ramnath Dwivedi
9. Shalakya tantra by Dr. Vishwanath Dwivedi
10. Shalakya Tantra by Dr. K.V. Prabhakaram (Telugu)
11. Parson's ophthalmology
12. May & worth Ophthalmology
13. A Short book on Ophthalmology by B. M. Chattergee
14. A Guide to Ophthalmology by Dhanraj Singh
15. Notes on Ophthalmology by Experienced teachers.

Ayurveda Ek Vikalp Foundation

- All ayurvedic books store
- India's biggest Ayurveda union.
- For Ayurvedic E- book follow, subscribe us on

Telegram- https://t.me/ayurvedaekvikalpfoundation

Facebook- https://m.facebook.com/ayurvedaekvikalp/?ref=bookmarks

E-mail- ayurvedaekvikalp@gmail.com

Website- ayurvedaekvikalp.org

For WhatsApp group msg- 9561788826

become member and explore the Ayurveda